SonoPath

Clinical Sonography & Telecytology

EDUCATIONAL TELECONSULTATION SERVICES™

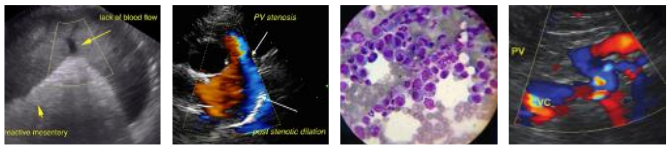

SonoPath.com™
1-800-838-4268 info@sonopath.com

PATIENT

Skoden Emmett

SPECIES

Feline

BREED

DMH

SEX

MN

AGE

16mo

WEIGHT

3.56kg

INTERPRETED BY

R. McKenzie Daniel, DVM, DABVP (Canine and Feline)

IMAGING PERFORMED BY

JSS

HOSPITAL NAME

King Hopkins Pet Hospital

REFERRING VET

Dr. Brown

INVOICE

12474ag

DATE

12/19/2022

PRESENTING CLINICAL SIGNS

16 month-old neutered DSH presented with kidney issues. Was taken to rDVM for gingivitis a week ago. rDVM diagnosed kidney disease. cat was given Sc fluids and has been on Sc fluids at home since. Now there is a swelling under the neck. Lymph Nodes: swollen left submandibular LN Skin & Coat: mild swelling in the caudoventral neck

Abnormal PE/Chem/CBC/UA Results: - Low RBC, Hematocrit 0.23, Hemoglobin, Retics 10.5, WBC 14.9 with mild neutrophilia, - High Platelets, MCHC, Creatinine 565, Urea >46.4, Globulin 52, - please see attached Urinalysis & Bloodwork reports USG 1.016 w/proteinuria, 3+ blood, glu neg

ULTRASONOGRAPHIC EXAMINATION OF THE ABDOMEN

Urinary System

The urinary bladder, trigone, cystourethral junction, and visible pelvic urethra to a depth of 2 cm exhibited normal thickness and tone. Anechoic urine was present in the lumen with no uroliths or sediment. The ureteral papillae were normal. The ureters were not visible which is normal. No evidence of inflammatory or neoplastic changes were noted.

Mildly enlarged size with asymmetrical margination was present in both kidneys. The renal cortex presented uniformly increased in echogenicity with uniform echotexture. The renal cortex appeared to be hypertrophied resulting in an altered cortex: medulla ratio. Mild loss of corticomedullary distinction was also present. Mild bilateral pyelectasia was present without left or right ureter dilation. The renal medullary volume was subjectively reduced. The left kidney measured 5.2 cm in length. The right kidney measured 5.5 cm in length.

The area of the aortic trifurcation was free of pathology.

Adrenal Glands

The left adrenal gland was uniform in size and contour with a uniformly hypoechoic parenchyma. The left adrenal gland measured 0.44 cm width. The right adrenal gland was uniform in size and contour with a uniformly hypoechoic parenchyma. The right adrenal gland measured 0.23 cm width.

Spleen

The spleen exhibited a finely textured and homogenous parenchyma which was hyperechoic to the liver and renal cortical parenchyma. The capsule was smooth and regular without apparent expansion. The splenic vasculature at the hilus was normal in volume with no evidence of congestion or thrombosis. Acute to chronic inflammatory, neoplastic, or benign parenchyma changes were not noted.

Liver

The liver was subjectively normal in size, structure, and contour. The liver parenchyma was uniform and hypoechoic to the spleen with a mild coarse echotexture. The hepatic and portal vasculature were normal in appearance without signs of congestion. The gallbladder was non-distended in size with thin walls and primarily anechoic luminal content with minor echogenic debris potentially secondary to fasting and likely incidental. The proximal common bile duct was dilated and tortuous without overt post hepatic obstruction, likely incidental.

Gastrointestinal

The stomach presented intact wall layering with a normal wall layer ratio. The lumen of the stomach was empty with no signs of ileus, obstruction or foreign material.

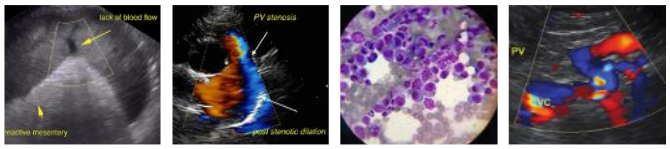

SonoPath.com
1-800-838-4268 info@sonopath.com

PATIENT

Skoden Emmett

SPECIES

Feline

BREED

DMH

SEX

MN

AGE

16mo

WEIGHT

3.56kg

INTERPRETED BY

R. McKenzie Daniel, DVM, DABVP (Canine and Feline)

IMAGING PERFORMED BY

JSS

HOSPITAL NAME

King Hopkins Pet Hospital

REFERRING VET

Dr. Brown

INVOICE

12474ag

DATE

12/19/2022

The small intestine presented intact wall layering with 1:3 muscularis/mucosa ratio. The lumen of the small intestine was empty with no signs of ileus, obstruction or foreign material.

Normal visible colon wall layers were present with apparent formed feces in lumen.

Pancreas

The parenchyma of the left limb, body and right limb of the pancreas presented isoechoic to the adjacent omental fat. A normal curvilinear capsule contour of the pancreas was present. The visible pancreatic duct was normal. No signs of active inflammation or neoplastic disease was evident.

Free Abdomen

No omental masses, overt lymphadenopathy or evidence of overt/significant peritoneal effusion was present.

ULTRASONOGRAPHIC FINDINGS

- Bilateral interstitial nephrosis renal pattern-nonspecific, early onset chronic renal disease, non-specific nephritis i.e. interstitial nephritis, glomerulonephritis or other. Potential for emerging bilateral renal neoplastic criteria i.e. lymphoma cannot be definitively excluded
- Unremarkable GI tract
- Mild gallbladder debris with mild non-obstructive proximal common bile duct dilation-likely incidental

INTERPRETATION OF THE FINDINGS & FURTHER RECOMMENDATIONS

Further renal staging to include urine C/S and protein: creatinine ratio on sterile urine sample may be considered. Renal sampling is required for further clarification and definitive diagnosis. Initial renal cortex FNA cytology using 25g needle and assuming normal clotting status could be considered. The appearance of the kidneys is not overtly suggestive of renal dysplasia given the mild increased bilateral increased renal size and discernable corticomedullary architecture. Recheck retroviral status is suggested. Empirically, CRD therapy with monitoring of renal parameters would be reasonable.

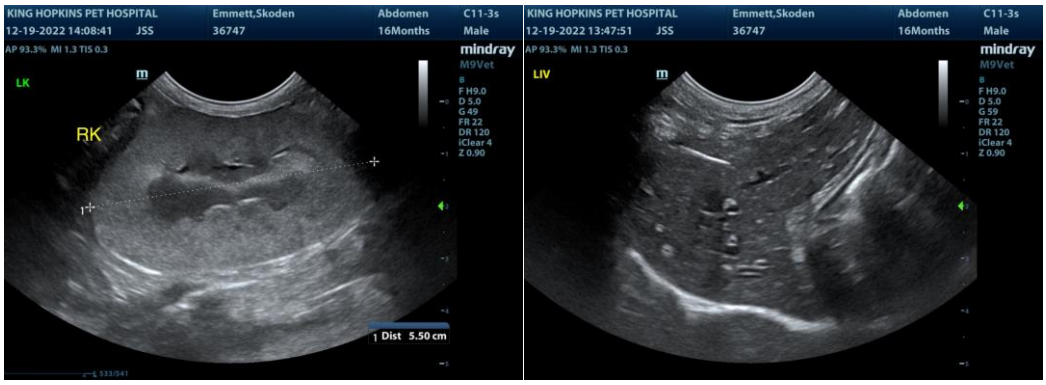

SonoPath

Clinical Sonography & Telecytology

EDUCATIONAL TELECONSULTATION SERVICES™

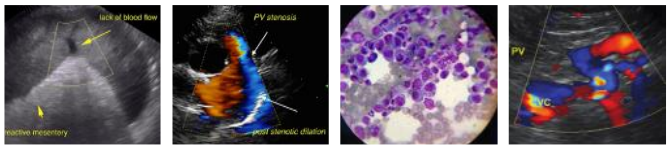

SonoPath.com™
1-800-838-4268 info@sonopath.com

PATIENT

Skoden Emmett

SPECIES

Feline

BREED

DMH

SEX

MN

AGE

16mo

WEIGHT

3.56kg

INTERPRETED BY

R. McKenzie Daniel, DVM, DABVP (Canine and Feline)

IMAGING PERFORMED BY

JSS

HOSPITAL NAME

King Hopkins Pet Hospital

REFERRING VET

Dr. Brown

INVOICE

12474ag

DATE

12/19/2022

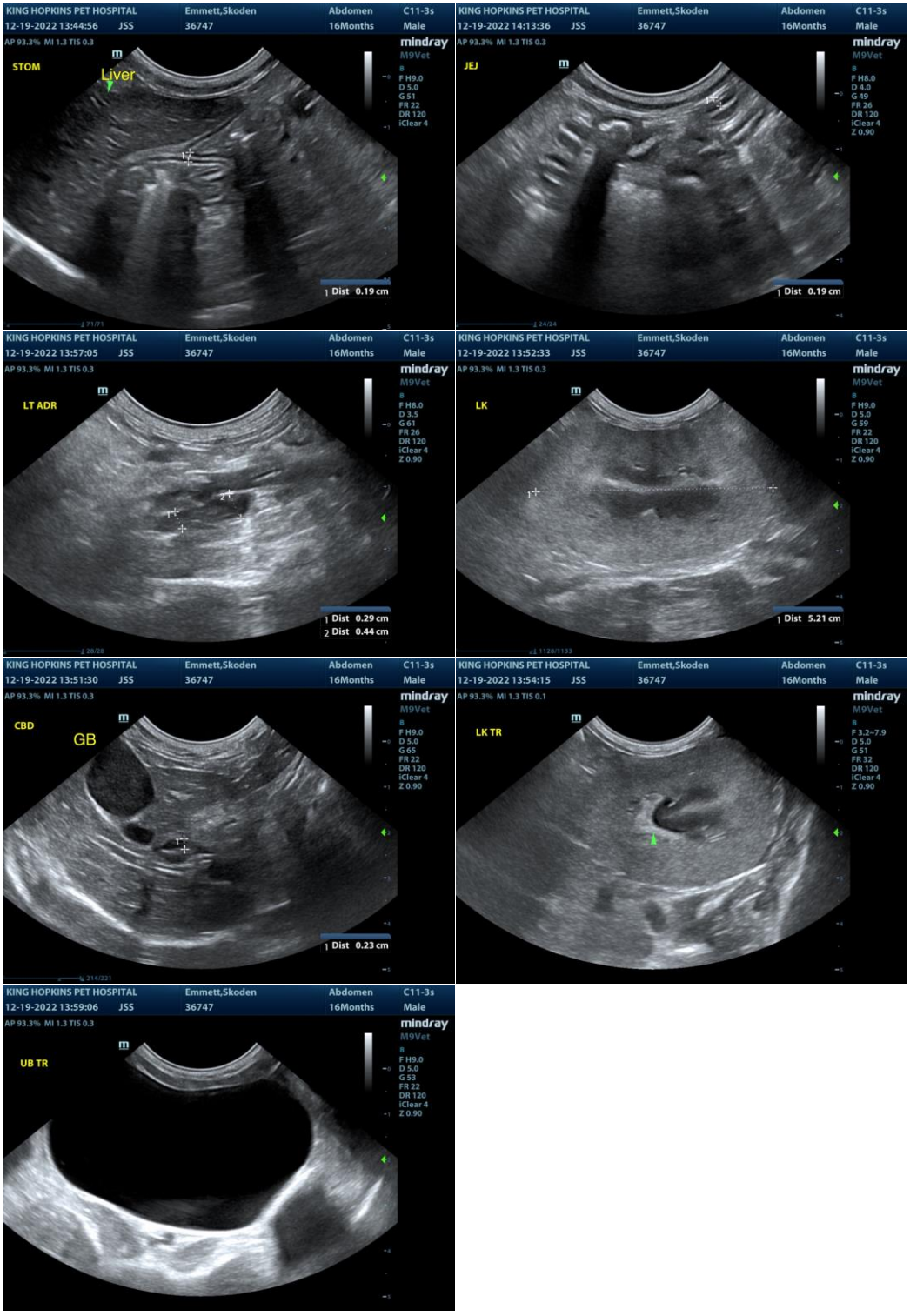

The information and recommendations provided are based on the images presented by the referring veterinarian/sonographer. No evaluation can be communicated regarding pathology that was not visible in the image/video clips provided.

Thank you for this referral. If the clinical or image interpretation does not parallel your findings or if I

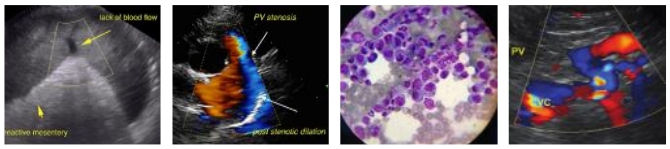

SonoPath.com
1-800-838-4268 info@sonopath.com

PATIENT

Skoden Emmett

SPECIES

Feline

BREED

DMH

SEX

MN

AGE

16mo

WEIGHT

3.56kg

INTERPRETED BY

R. McKenzie Daniel, DVM, DABVP (Canine and Feline)

IMAGING PERFORMED BY

JSS

HOSPITAL NAME

King Hopkins Pet Hospital

REFERRING VET

Dr. Brown

INVOICE

12474ag

DATE

12/19/2022

can be of any further assistance, please contact me.

R. McKenzie Daniel, DVM, DABVP (Canine/Feline Practice)
mac.daniel@sonopath.com