



PATIENT PRESENTING CLINICAL SIGNS

Lucy Kujala Incidental finding of increased liver enzymes on routine pre-surgical lab work. No history of toxins or ingestion of unknown substances.

SPECIES Current meds: Denamarin, Trio.
 Canine Abnormal PE/Chem/CBC/UA Results: ALT 447; ALP 300.

ULTRASONOGRAPHIC EXAMINATION OF THE ABDOMEN

BREED *Urinary System*

Husky The urinary bladder, trigone, cystourethral junction, and visible pelvic urethra exhibited normal thickness and tone. Anechoic urine was present in the lumen with no uroliths or sediment. The ureteral papillae were normal. The ureters were not visible which is normal. No evidence of inflammatory or neoplastic changes were noted.

SEX FS Normal size and margination were present in the kidneys. A normal 1:3 cortex / medulla ratio was maintained. The medulla and cortices were uniform in texture with some increased echogenicity and mild loss of corticomedullary symmetry and definition expected for the age of the patient. No evidence of pelvic dilation was present. The left kidney measured 7.3 cm in length. The right kidney measured 5.7 cm in length.

WEIGHT The area of the aortic trifurcation was free of pathology.

Adrenal Glands

61.3lb The left adrenal gland was uniform in size and contour with a uniformly hypoechoic parenchyma. The left adrenal gland measured 0.37 cm width at the caudal pole and 0.38 cm width at the cranial pole. The right adrenal gland was uniform in size and contour with a uniformly hypoechoic parenchyma. The right adrenal gland measured 0.51 cm width at the caudal pole and 0.53 cm width at the cranial pole.

INTERPRETED BY

R. McKenzie Daniel, DVM,
 DABVP (Canine and Feline)

Spleen

IMAGING PERFORMED BY

Pamela Harrigan, RDCS

The spleen exhibited mild enlargement likely secondary to sedation with a finely textured and homogenous parenchyma which was hyperechoic to the liver and renal cortical parenchyma. The capsule was smooth and regular without apparent expansion. The splenic vasculature at the hilus was normal in volume with no evidence of congestion or thrombosis. Acute to chronic inflammatory, neoplastic, or benign parenchyma changes were not noted.

HOSPITAL NAME

Dr. Pam Harrigan
 PAUS

Liver

REFERRING VET

Dr. Kalani

The liver was enlarged in size with symmetrical to mildly rounded capsule contour. Mild increased hepatic parenchyma echogenicity compared to the spleen with a moderate coarse echotexture. A solitary small thinly walled cyst was present containing anechoic fluid. The hepatic and portal vasculature were normal in appearance without signs of congestion. The gallbladder was non-distended in size with thin walls and primarily anechoic luminal content with non-dependent non-organized hyperechoic debris. No evidence of gallbladder or peripheral gallbladder inflammation was present. The cystic and common bile ducts were normal.

INVOICE

12477ag

Gastrointestinal

DATE

12/19/2022

The stomach presented intact wall layering with a normal wall layer ratio. The lumen of the stomach was empty with no signs of ileus, obstruction or foreign material.

The small intestine presented intact wall layering with 1:3 muscularis/mucosa ratio. The lumen of the small intestine was empty with no signs of ileus, obstruction or foreign material.



PATIENT Normal visible colon wall layers were present with apparent formed feces in lumen.

Lucy Kujala **Pancreas**

SPECIES The pancreas was normal in size and contour with isoechoic to heterogeneous parenchyma compared to adjacent omentum, likely consistent with age related changes and considered incidental. No signs of active inflammation or neoplasia.

Canine

Free Abdomen

BREED No omental masses, overt lymphadenopathy or peritoneal effusion was present.

Husky Several to intermittent mildly prominent to enlarged colic lymph nodes were present. The lymph nodes were essentially isoechoic to adjacent omentum without evidence of peripheral inflammation and maintaining a normal width: length ratio (<0.5). This finding is considered incidental and is not consistent with inflammatory or neoplastic criteria.

SEX

FS

ULTRASONOGRAPHIC FINDINGS

AGE

9yr

- Hepatopathy with solitary small intraparenchymal cyst-subjectively benign, vacuolar hepatopathy, inflammatory/immune mediated disease, hematopoiesis, hyperplasia, non-obstructive cholestasis or other hepatopathy possible. Neoplastic criteria considered less likely
- Mild gallbladder debris (non-mucocele)
- Mild heterogeneous pancreas
- Early mild age-related renal changes

WEIGHT

61.3lb

INTERPRETATION OF THE FINDINGS & FURTHER RECOMMENDATIONS

INTERPRETED BY

R. McKenzie Daniel, DVM,
 DABVP (Canine and Feline)

Assuming normal clotting status and using a 25g needle, a hepatic FNA for screening cytology is warranted for further assessment primarily to assess and identify inflammatory cells or hepatic antigenic stimulation. A leptospirosis titer/PCR may be considered if clinically indicated or if potential exposure/endemic to the area. Hepatosupportive medications such as Denamarin and Ursodiol may prove beneficial.

IMAGING PERFORMED BY

Pamela Harrigan, RDCS

The pancreas was non-specific and may indicate patient/ age variant, remodeling owing to previous inflammatory episode or mild to chronic pancreatitis possible. This potential may be considered if evidence of cranial abdominal or subxiphoid discomfort on palpation. Correlation with a spec cPL could be considered if clinically indicated. No overt anesthetic contraindications assuming evidence of normal hepatic function, normal ALB, GLU, BUN and CHOL levels.

HOSPITAL NAME

Dr. Pam Harrigan
 PAUS

REFERRING VET

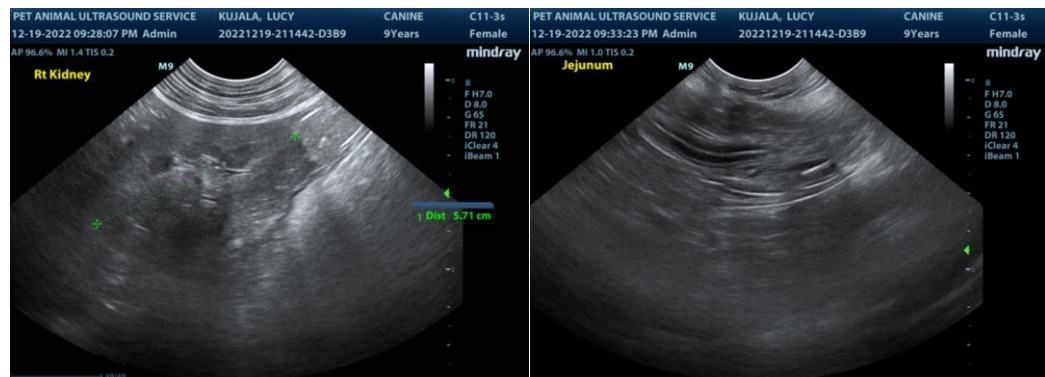
Dr. Kalani

INVOICE

12477ag

DATE

12/19/2022





PATIENT

Lucy Kujala

SPECIES

Canine

BREED

Husky

SEX

FS

AGE

9yr

WEIGHT

61.3lb

INTERPRETED BY

R. McKenzie Daniel, DVM,
 DABVP (Canine and Feline)

IMAGING PERFORMED BY

Pamela Harrigan, RDCS

HOSPITAL NAME

Dr. Pam Harrigan
 PAUS

REFERRING VET

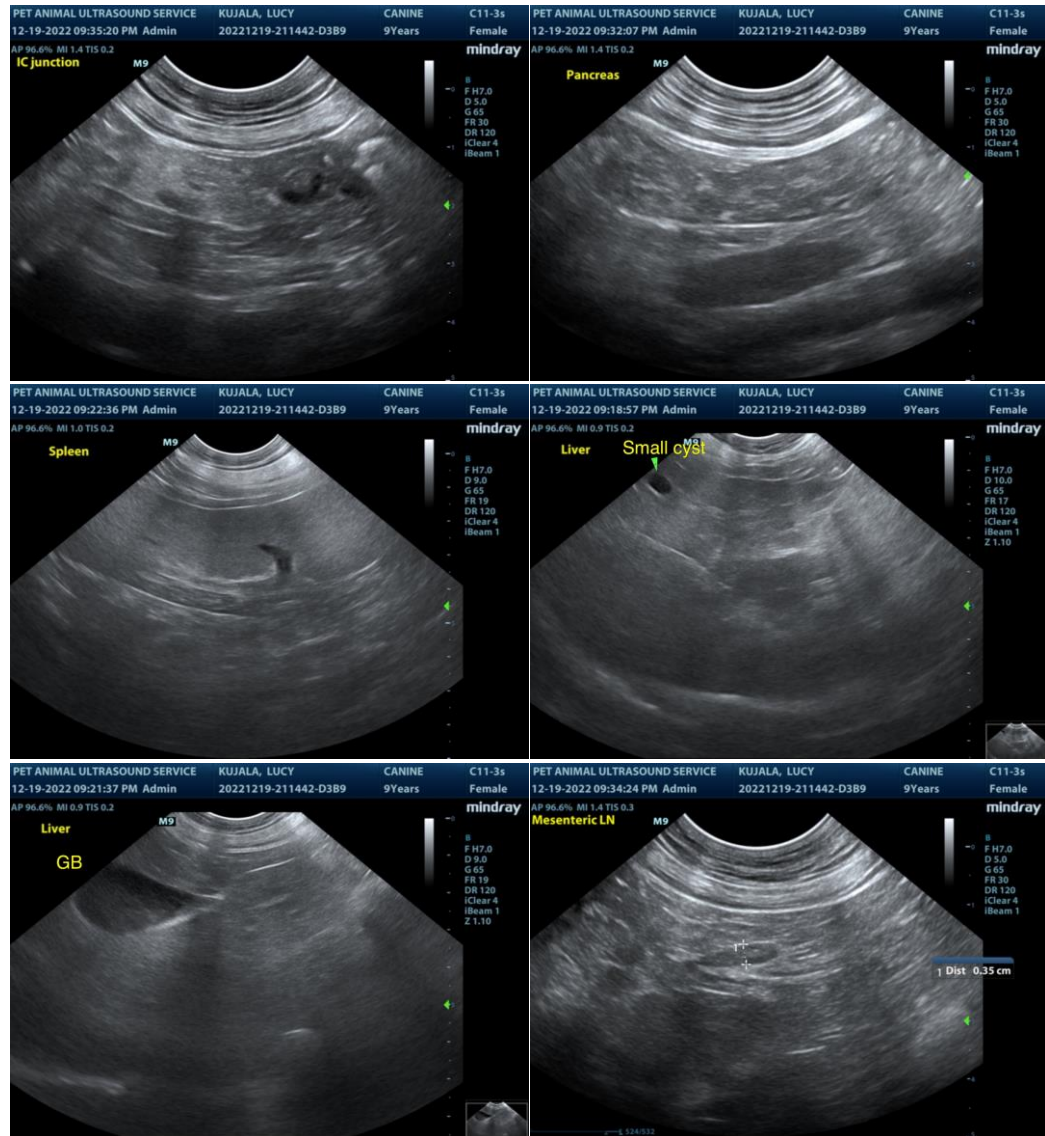
Dr. Kalani

INVOICE

12477ag

DATE

12/19/2022





PATIENT

Lucy Kujala

SPECIES

Canine

BREED

Husky

SEX

FS

AGE

9yr

WEIGHT

61.3lb

INTERPRETED BY

R. McKenzie Daniel, DVM,
 DABVP (Canine and Feline)

IMAGING PERFORMED BY

Pamela Harrigan, RDCS

HOSPITAL NAME

Dr. Pam Harrigan
 PAUS

REFERRING VET

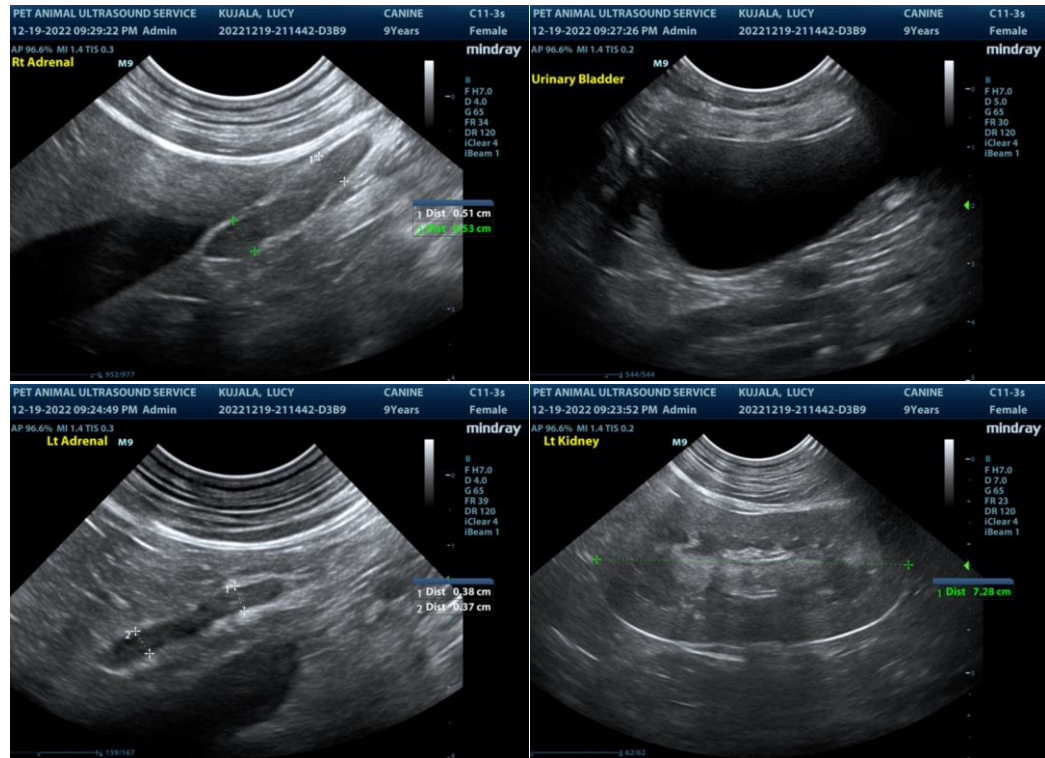
Dr. Kalani

INVOICE

12477ag

DATE

12/19/2022



The information and recommendations provided are based on the images presented by the referring veterinarian/sonographer. No evaluation can be communicated regarding pathology that was not visible in the image/video clips provided.

Thank you for this referral. If the clinical or image interpretation does not parallel your findings or if I can be of any further assistance please contact me.

R. McKenzie Daniel, DVM, DABVP (Canine / Feline Practice)

info@SonoPath.com