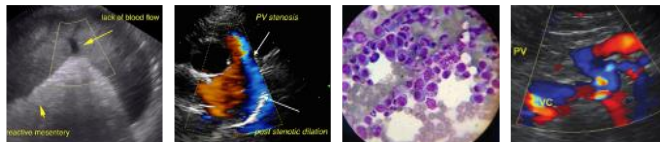




PATIENT	PRESENTING CLINICAL SIGNS
Atheena Samletzki	Chronic vomiting. Normal labs. Please see barium series. Attending DVM concerned for pyloric abnormality given stomach radiographs with barium.
SPECIES	ULTRASONOGRAPHIC EXAMINATION OF THE ABDOMEN
Canine	Urinary System
BREED	The urinary bladder, trigone, cystourethral junction, and visible pelvic urethra exhibited normal thickness and tone. Anechoic urine was present in the lumen with no uroliths or sediment. The ureteral papillae were normal. The ureters were not visible which is normal. No evidence of inflammatory or neoplastic changes were noted.
Shepherd Mix	
SEX	Normal size and margination were present in the kidneys. A normal 1:3 cortex / medulla ratio and normal corticomedullary definition were maintained. The echogenicity of the cortex was similar to or slightly less than normal liver parenchyma while the medulla echogenicity was hypoechoic to the cortex with no evidence of pelvic dilation. The left kidney measured 6.3 cm in length. The right kidney measured 6.7 cm in length.
FS	
AGE	The area of the aortic trifurcation was free of pathology.
6yr	Adrenal Glands
WEIGHT	The left adrenal gland was indistinctly visualized without overt pathology. The left adrenal gland measured 0.60 cm width at the caudal pole. The right adrenal gland was not definitively visualized.
35.1kg	Spleen
INTERPRETED BY	The spleen exhibited a finely textured and homogenous parenchyma which was hyperechoic to the liver and renal cortical parenchyma. The capsule was smooth and regular without apparent expansion. The splenic vasculature at the hilus was normal in volume with no evidence of congestion or thrombosis. Acute to chronic inflammatory, neoplastic, or benign parenchyma changes were not noted.
R. McKenzie Daniel, DVM, DABVP (Canine and Feline)	Liver
IMAGING PERFORMED BY	The liver was subjectively normal in size, structure, and contour. The liver parenchyma was uniform and hypoechoic to the spleen with a mild coarse echotexture. The hepatic and portal vasculature were normal in appearance without signs of congestion. The gallbladder was non-distended in size with thin walls and primarily anechoic luminal content with mild echogenic non-organized debris. No evidence of gallbladder or peripheral gallbladder inflammation was present. The cystic and common bile ducts were normal.
Dave Stasiuk	Gastrointestinal
HOSPITAL NAME	The stomach presented intact wall layering with a normal wall layer ratio. The lumen of the stomach contained mild progressively shadowing ingesta suggestive of food with no signs of ileus, obstruction or overt foreign material.
Healthy Paws Forward VH	
REFERRING VET	INVOICE
Dr. Hen-Boisen	The small intestine presented intact wall layering with 1:3 muscularis/mucosa ratio. The lumen of the small intestine was empty with no signs of ileus, obstruction or foreign material.
	Normal visible colon wall layers were present with apparent formed feces in lumen.
DATE	Pancreas
12/19/2022	



PATIENT

Atheena Samletzki

The parenchyma of the left limb, body and right limb of the pancreas presented isoechoic to the adjacent omental fat. A normal curvilinear capsule contour of the pancreas was present. The visible pancreatic duct was normal. No signs of active inflammation or neoplastic disease was evident.

SPECIES

Canine

Free Abdomen

No omental masses, overt lymphadenopathy or peritoneal effusion was present.

BREED

Shepherd Mix

- Overtly normal GI tract with mild gastric ingesta

INTERPRETATION OF THE FINDINGS & FURTHER RECOMMENDATIONS

SEX

FS

The presence of gastric ingesta is nonspecific and likely indicates post-prandial presentation. Correlation with most recent meal ingestion is recommended. If documented NPO prior to the ultrasound, the presence of gastric ingesta may indicate some degree of gastric hypomotility or metabolic stasis. The sonographic presentation of the ingesta was most consistent with food, without evidence of foreign material.

AGE

6yr

Dietary intolerance / food hypersensitivity, occult parasitism, structurally insignificant inflammatory gastroenteropathy or low grade to chronic pancreatitis both of which may appear sonographically normal are all potentials. A spec cPL or a GI panel to include PLI/TLI/Cobalamin/Folate may be considered for assessment of occult disease.

WEIGHT

35.1kg

Empirically, a limited antigen or hydrolyzed diet trial with potential long term dietary therapy, as needed gastric protectants +/- coverage for helicobacter/esophagitis may prove beneficial. Although considered unlikely considering normal adrenal presentation, a resting cortisol level to rule out occult Addison's disease is recommended. Upper GI endoscopy with potential for biopsies may be considered if continued vomiting despite empirical and dietary therapy.

INTERPRETED BY

R. McKenzie Daniel,
DVM, DABVP
(Canine and Feline)

IMAGING PERFORMED BY

Dave Stasiuk

HOSPITAL NAME

Healthy Paws
Forward VH

REFERRING VET

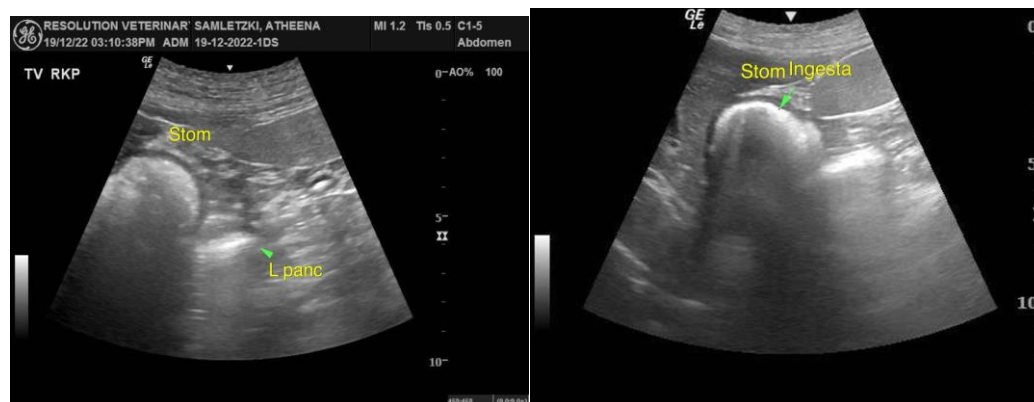
Dr. Hen-Boisen

INVOICE

12488ag

DATE

12/19/2022





PATIENT

Atheena Samletzki

SPECIES

Canine

BREED

Shepherd Mix

SEX

FS

AGE

6yr

WEIGHT

35.1kg

INTERPRETED BY

R. McKenzie Daniel,
DVM, DABVP
(Canine and Feline)

IMAGING PERFORMED BY

Dave Stasiuk

HOSPITAL NAME

Healthy Paws
Forward VH

REFERRING VET

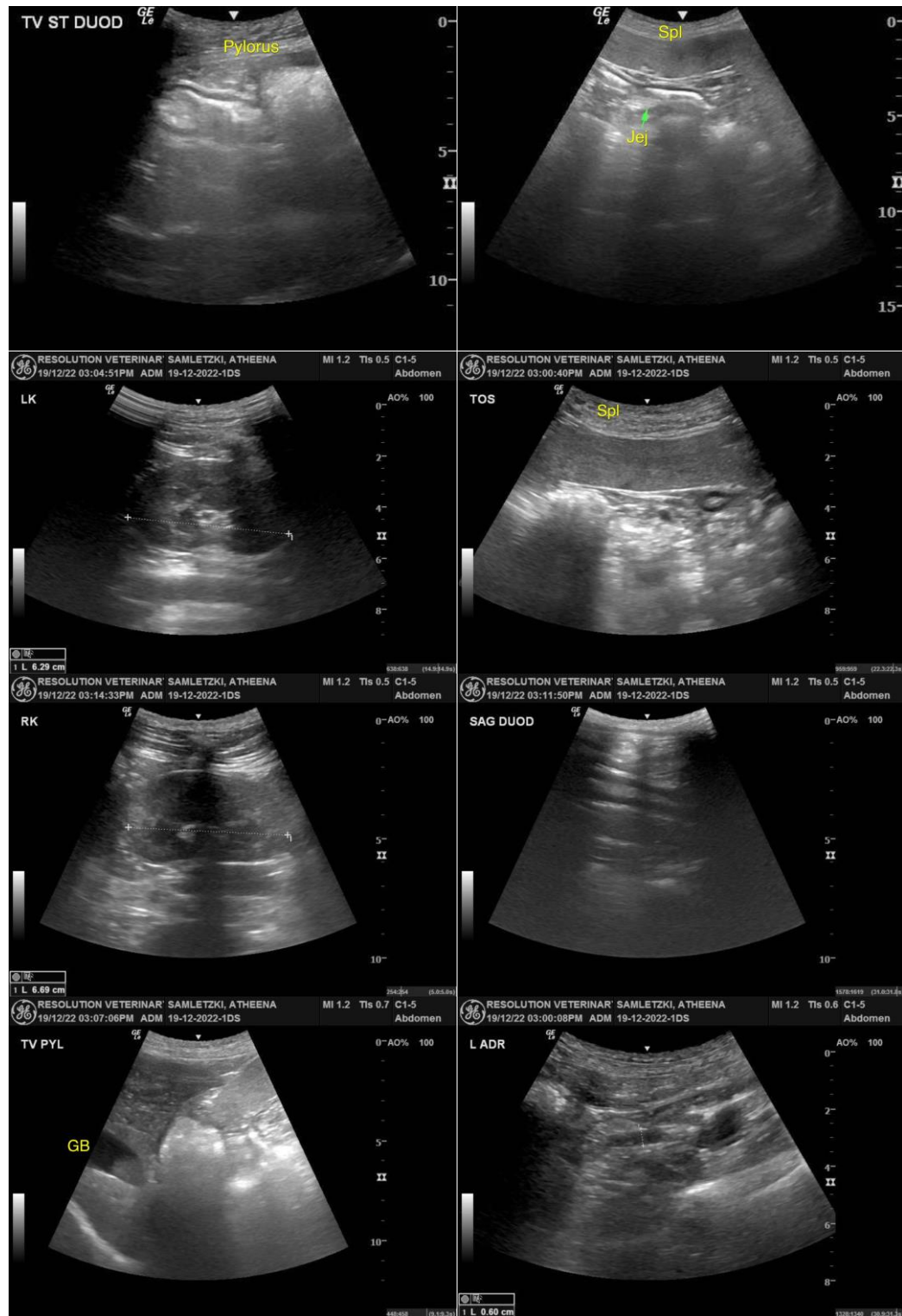
Dr. Hen-Boisen

INVOICE

12488ag

DATE

12/19/2022



The information and recommendations provided are based on the images presented by the referring veterinarian/sonographer. No evaluation can be communicated regarding pathology that was not visible in the image/video clips provided.



PATIENT

Atheena Samletzki

Thank you for this referral. If the clinical or image interpretation does not parallel your findings or if I can be of any further assistance, please contact me.

SPECIES

Canine

R. McKenzie Daniel, DVM, DABVP (Canine/Feline Practice)
mac.daniel@sonopath.com

BREED

Shepherd Mix

SEX

FS

AGE

6yr

WEIGHT

35.1kg

INTERPRETED BY

R. McKenzie Daniel,
DVM, DABVP
(Canine and Feline)

**IMAGING
PERFORMED BY**

Dave Stasiuk

HOSPITAL NAME

Healthy Paws
Forward VH

REFERRING VET

Dr. Hen-Boisen

INVOICE

12488ag

DATE

12/19/2022