



**PATIENT**

Lilo Fuentes

**SPECIES**

Canine

**BREED**

Pitbull

**SEX**

Female

**AGE**

1

**WEIGHT**

63

**INTERPRETED BY**

R. McKenzie Daniel,  
DVM, DABVP  
(Canine and Feline)

**IMAGING PERFORMED BY**

Jenn

**HOSPITAL NAME**

Rockaway AH

**REFERRING VET**

Dr. Kahn

**INVOICE**

12965

**DATE**

12/18/25

**PRESENTING CLINICAL SIGNS**

History: Was playing at dog park, dog became pale and lethargic Increased ALT

Abnormal PE/Chem/CBC/UA Results: ALT 964

**ULTRASONOGRAPHIC EXAMINATION OF THE HEART & ABDOMEN**

CANINE CARDIAC PARAMETERS	MR VMAX (m/s)	TR VMAX (m/s)	LA/AO (M-Mode)	LA/AO (Heart Base; Swe)	FS (%)	EF (%)	EPSS (cm)
NORMAL PARAMETER	4.5-5.5	<2.7	1.3	Up to 1.6	28-40	400.44-100	<0.6
PATIENT	--	--	--	1.36	33	63	
CANINE CARDIAC PARAMETERS	HR (BPM)	AV VMAX (m/s)	PV MAX (m/s)	BODY WEIGHT (kg)	LAD LA MAX 4 Chamber	LVIDd Avg; 2D and m-mode short axis (cm)	LVIDs Avg; 2D and m-mode short axis (cm)
NORMAL PARAMETER	50-100	0.7-1.7	0.7-1.6				
PATIENT	100	1.5	0.82	--	3.8	3.9	--

**Cardiac Presentation**

The echocardiogram in this patient demonstrated normal **left atrial** size based on 2 separate methods of LA evaluation. The cranial and caudal **mitral** valve leaflets presented normal linear structure, extension in systole, and union in diastole with normal kinesis. The **left ventricle** presented thicknesses with linear contour and was not dilated nor restricted. The **myocardium** presented normal echogenicity without subjective evidence of significant fibrotic or ischemic disease. **Contractility** of the ventricular walls was adequate and in normal range for this patient evidenced by the fractional shortening measurement and subjective evaluation of the different regions of the myocardium. The **left ventricular outflow** tract demonstrated normal laminar flow and subjective structural integrity. Normal measured LVOT velocity. The **right atrium** and auricle revealed normal size, structure and content. No evidence of masses was noted. **Tricuspid** valvular assessment demonstrated adequate linear morphology and kinesis. The **right ventricle** was of normal size (1/3 diameter of LV), chordae structure, myocardial echogenicity and thickness. **Pulmonary outflow** tract assessment revealed normal valve structure, laminar flow, and diameter (approx.1:1 pa/ao ratio). Normal measured RVOT velocity. No visible **pericardial** or free pleura fluid was noted. The cranial **mediastinum and pericardial and extra-cardiac regions** were free of masses in the visible window. No evidence of arrhythmia present.



## PATIENT

Lilo Fuentes

## SPECIES

Canine

## BREED

Pitbull

## SEX

Female

## AGE

1

## WEIGHT

63

## INTERPRETED BY

R. McKenzie Daniel,  
DVM, DABVP  
(Canine and Feline)

## IMAGING PERFORMED BY

Jenn

## HOSPITAL NAME

Rockaway AH

## REFERRING VET

Dr. Kahn

## INVOICE

12965

## DATE

12/18/25

## Urinary System

The urinary bladder, trigone, cystourethral junction, and visible pelvic urethra to a depth of 2.0 cm exhibited normal thickness and tone. Anechoic urine was present in the lumen with no uroliths or sediment. The ureteral papillae were normal. The ureters were not visible which is normal. No evidence of inflammatory or neoplastic changes were noted.

No evidence of pathology in the area of the uterus or bilateral ovaries, if intact.

Normal size and margination was present in the kidneys. A normal 1:3 cortex / medulla ratio and normal corticomedullary definition were maintained. The echogenicity of the cortex was similar to or slightly less than normal liver parenchyma while the medulla echogenicity was hypoechoic to the cortex with no evidence of pelvic dilation. The left kidney measured 5.8 cm in length. The right kidney measured 5.6 cm in length.

## Adrenal Glands

The left adrenal gland was uniform in size and contour with a uniformly hypoechoic parenchyma. The left adrenal gland measured 0.62 cm width at the caudal pole. The right adrenal gland was uniform in size and contour with a uniformly hypoechoic parenchyma. The right adrenal gland measured 0.57 cm width at the caudal pole.

## Spleen

The spleen exhibited a finely textured and homogenous parenchyma which was hyperechoic to the liver and renal cortical parenchyma. The capsule was smooth and regular without apparent expansion. The splenic vasculature at the hilus was normal in volume with no evidence of congestion or thrombosis. Acute to chronic inflammatory, neoplastic, or benign parenchyma changes were not noted.

## Liver

The liver was subjectively normal in size, structure, and contour with normal hepatic vascular volume. The liver parenchyma was uniform and hypoechoic to the spleen with a mild coarse echotexture. The hepatic and portal vasculature were normal in appearance without signs of congestion. The gallbladder was non-distended in size without evidence of post hepatic obstruction and contained anechoic bile. No evidence of pericholecystic inflammation. The gallbladder wall was mild to moderately thickened in appearance consisting of an echogenic double rim corresponding to the inner and outer portions of the wall. This is consistent with gallbladder wall edema. Possible causes may include acute inflammation, edema and anaphylaxis. Gallbladder wall measured 0.45 cm width.

## Gastrointestinal

The stomach presented intact wall layering with a normal wall layer ratio. The lumen of the stomach was empty with no signs of ileus, obstruction or foreign material.

The small intestine presented intact wall layering with 1:3 muscularis/mucosa ratio. The lumen of the small intestine was empty with no signs of ileus, obstruction or foreign material.

Normal visible colon wall layers were present with apparent formed feces in lumen.



**PATIENT**

Lilo Fuentes

**SPECIES**

Canine

**BREED**

Pitbull

**SEX**

Female

**AGE**

1

**WEIGHT**

63

**INTERPRETED BY**

R. McKenzie Daniel,  
DVM, DABVP  
(Canine and Feline)

**IMAGING PERFORMED BY**

Jenn

**HOSPITAL NAME**

Rockaway AH

**REFERRING VET**

Dr. Kahn

**INVOICE**

12965

**DATE**

12/18/25

**Pancreas**

The parenchyma of the left limb, body and right limb of the pancreas presented isoechoic to the adjacent omental fat. A normal curvilinear capsule contour of the pancreas was present. The visible pancreatic duct was normal. No signs of active inflammation or neoplastic disease was evident.

**Free Abdomen**

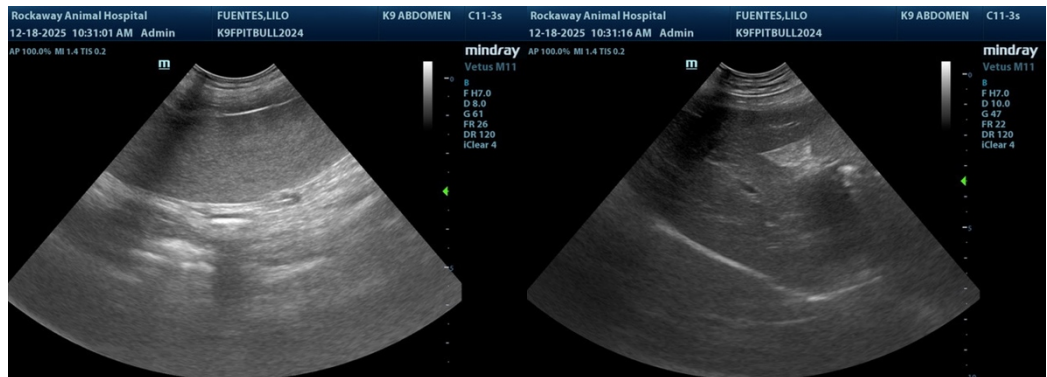
No omental lymphadenopathy or peritoneal effusion was present.

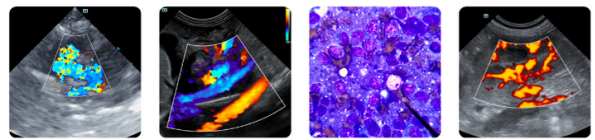
**ULTRASONOGRAPHIC FINDINGS**

- Normal cardiac structure/function
- Hepatopathy
- Mild to moderate edematous gallbladder

**INTERPRETATION OF THE FINDINGS & FURTHER RECOMMENDATIONS**

Considerations for the hepatopathy and gallbladder edema may include acute hepatitis (viral/bacteria leptospirosis toxin) acute cholecystitis or anaphylaxis. No evidence of intrahepatic or extrahepatic macroscopic shunt. Aside from the hepatopathy, no evidence of cardiac or abdominal visceral pathology as an obvious contributing factor to the patient's clinical signs. Further assessment may include, assuming normal clotting status, hepatic FNA cytology and leptospirosis titer/PCR. ECG may be considered to assess for paroxysmal arrhythmia. Empirical therapy for suspect nonspecific hepatitis pending additional diagnostics with clinical monitoring would be appropriate. Sonographic reassessment indicated if evidence of progressive hepatopathy or clinical signs.





**PATIENT**

Lilo Fuentes

**SPECIES**

Canine

**BREED**

Pitbull

**SEX**

Female

**AGE**

1

**WEIGHT**

63

**INTERPRETED BY**

R. McKenzie Daniel,  
DVM, DABVP  
(Canine and Feline)

**IMAGING PERFORMED BY**

Jenn

**HOSPITAL NAME**

Rockaway AH

**REFERRING VET**

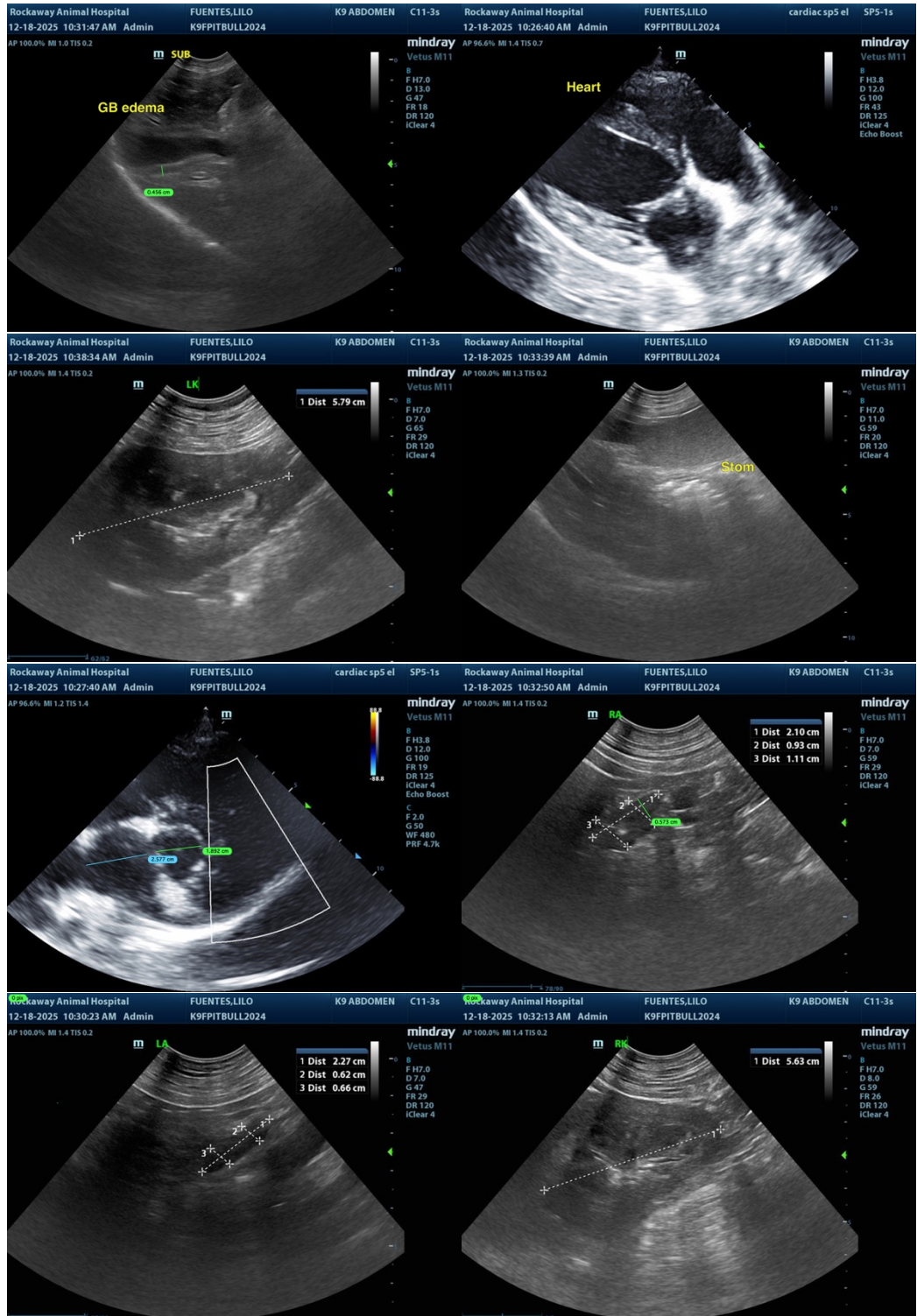
Dr. Kahn

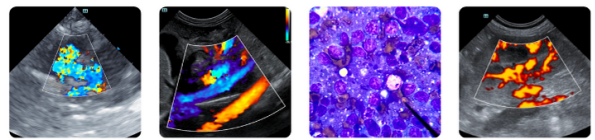
**INVOICE**

12965

**DATE**

12/18/25





## PATIENT

Lilo Fuentes

## SPECIES

Canine

## BREED

Pitbull

## SEX

Female

## AGE

1

## WEIGHT

63

## INTERPRETED BY

R. McKenzie Daniel,  
DVM, DABVP  
(Canine and Feline)

## IMAGING PERFORMED BY

Jenn

## HOSPITAL NAME

Rockaway AH

## REFERRING VET

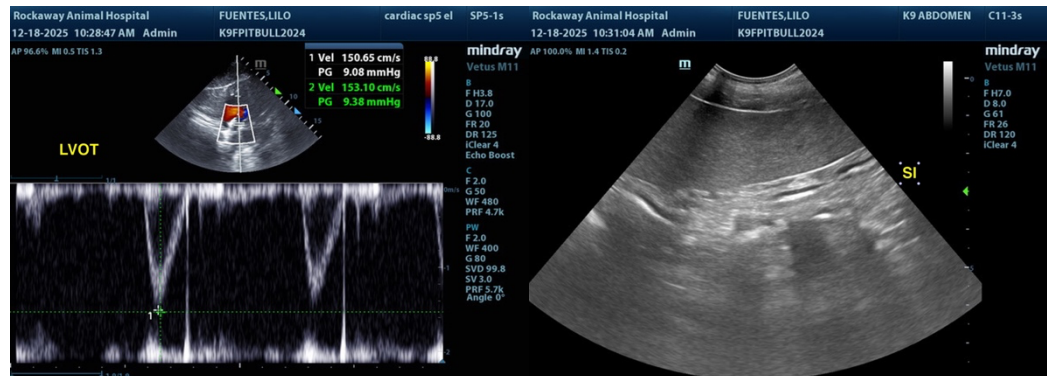
Dr. Kahn

## INVOICE

12965

## DATE

12/18/25



The information and recommendations provided are based on the images presented by the referring veterinarian/sonographer. No evaluation can be communicated regarding pathology that was not visible in the image/video clips provided.

Thank you for this referral. If the clinical or image interpretation does not parallel your findings or if I can be of any further assistance, please contact me.

R. McKenzie Daniel, DVM, DABVP (Canine / Feline Practice)

[info@sonopath.com](mailto:info@sonopath.com)