



PATIENT

Tank Tenney

SPECIES

Canine

BREED

Pit x Lab

SEX

Neutered Male

AGE

14 Years

WEIGHT

35 kg

INTERPRETED BY

R. McKenzie Daniel,
DVM, DABVP
(Canine and Feline)

IMAGING PERFORMED BY

Dr. Callihan

HOSPITAL NAME

Animal Emergency
Care

REFERRING VET

Dr. Callihan

INVOICE

33567

DATE

12/18/21

PRESENTING CLINICAL SIGNS

Tank has had a splenic mass first noted approximately 2 years ago with primary care vet. As owner explains, Tank had a low platelet count at that time that precluded surgery. They opted not to pursue further diagnostics and treatment regarding the mass He has had intermittent GI issues with vomiting and loss of appetite that resolve with supportive outpatient care. Most vet visits have been for GI or arthritis related symptoms. Yesterday, he was observed to be down in the hind, attempting to ambulate but dragging himself and presented to Diamond Vet Hosp ER in Everett. A cavitated cranial abd mass was noted with cursory ultrasound and no visible free fluid (per record; owner was under impression there was fluid) . Further diagnostics were discussed and declined. Owners were considering euthanasia but wanted a more complete ultrasound to help assess overall picture. Meds include Galliprant 60mg p.o. q24h Yunnan Baiyao Gabapentin 300mg #4 cap given last night
Abnormal PE/Chem/CBC/UA Results: No labs. On PE pt is ambulatory X 4 (slowly), alert, apprehensive; mms pink, normal crt; H: no murmur, normal rate and rhythm; abd taut but no fluid wave

ULTRASONOGRAPHIC EXAMINATION OF THE ABDOMEN

Urinary System

The urinary bladder, trigone, cystourethral junction, and visible pelvic urethra to a depth of 3.0 cm exhibited normal thickness and tone. Anechoic urine was present in the lumen with no uroliths or sediment. The ureteral papillae were normal. The ureters were not visible which is normal. No evidence of inflammatory or neoplastic changes were noted.

The residual prostate was symmetrically normal in size with uniform parenchyma and slight coarse echotexture. The prostate measured 1.1 cm in width.

The area of the aortic trifurcation was free of pathology.

Normal size and margination were present in the kidneys. A normal 1:3 cortex / medulla ratio was maintained. The medulla and cortices were uniform in texture with some increased echogenicity and loss of corticomedullary symmetry and definition expected for the age of the patient. No evidence of pelvic dilation was present. Small cortical cysts were present in both kidneys. The left kidney measured 8.3 cm. The right kidney measured 8.0 cm.

Adrenal Glands

The left adrenal gland presented mild parenchyma heterogeneity and mild capsule asymmetry without suspicion for overt neoplasia. The left adrenal gland was mildly enlarged in size, measuring 1.6 cm at the cranial pole and 1.2 cm at the caudal pole. The right adrenal gland was not definitively visualized.

Spleen

A mass involving the spleen with secondary capsule expansion and disruption was present. The parenchyma of the mass was heterogeneous to mixed echogenic without areas of cavitation. Potential for mineralization within the mass possible, although not definitive. The mass measured approximately 12 cm x 11 cm. The visualized spleen not associated with the mass was sonographically unremarkable.

Liver

The liver was subjectively normal in size, structure, and contour. The liver parenchyma was mildly nonuniform and hypoechoic to the spleen with a moderate coarse echotexture and subjective mild to benign parenchymal remodeling. The hepatic and portal vasculature were normal in appearance without signs of congestion. The gallbladder was non-distended in size with thin walls and primarily anechoic luminal content. The cystic and common bile ducts were normal.



PATIENT

Gastrointestinal

Tank Tenney

The visualized gastric walls were normal. The lumen of the stomach contained moderate echogenic ingesta exhibiting subtle progressive distal acoustic shadowing. This may indicate post-prandial presentation with potential for mild gastric metabolic hypomotility if documented NPO.

SPECIES

Canine

The visualized small intestine presented intact wall layering with 1:3 muscularis/mucosa ratio. The lumen of the small intestine was empty with no signs of ileus, obstruction or foreign material.

BREED

Pit x Lab

Normal visible colon wall layers were present with apparent formed feces in lumen.

SEX

Neutered Male

Pancreas

The parenchyma of the left limb, body and right limb of the pancreas presented isoechoic to the adjacent omental fat. A normal curvilinear capsule contour of the pancreas was present. The visible pancreatic duct was normal. No signs of active inflammation or neoplastic disease was evident.

AGE

14 Years

Free Abdomen

Subtle perisplenic reactive mesentery noted. No evidence of splenic mass rupture and secondary peritoneal effusion. No overt lymphadenopathy noted.

Rapid view of the heart revealed no overt evidence of pericardial effusion or definitive masses.

WEIGHT

35 kg

ULTRASONOGRAPHIC FINDINGS

- Non-homogeneous to potentially mineralized splenic mass
- Gastric ingesta, overtly normal small bowel and colon
- Mild hepatic parenchymal remodeling – subjectively benign.
- Bilateral chronic renal changes with cortical cysts
- Non-specific mild left adrenomegaly

INTERPRETED BY

R. McKenzie Daniel,
DVM, DABVP
(Canine and Feline)

INTERPRETATION OF THE FINDINGS & FURTHER RECOMMENDATIONS

This study confirms the presence of previously diagnosed splenic mass. The splenic mass is nonspecific with considerations including hyperplasia, hematopoiesis, granuloma, splenitis, or neoplasia (sarcoma, round cell neoplasia, other).

IMAGING PERFORMED BY

Dr. Callihan

The mild left adrenomegaly is non-specific with considerations including age related/patient variant, benign hyperplasia, adenomatous change, while the possibility of emerging primary or metastatic left adrenal neoplasia cannot be definitively excluded. Screening blood pressure is recommended. No overt evidence of structural gastrointestinal pathology.

HOSPITAL NAME

Animal Emergency
Care

REFERRING VET

Dr. Callihan

Continued as-needed gastrointestinal support would be appropriate. 3-view chest radiographs recommended to assess for thoracic pathology. Aside from the non-specific mild left adrenomegaly, no overt evidence of intraabdominal or pericardial metastasis from the splenic mass.

INVOICE

33567

DATE

12/18/21



PATIENT

Tank Tenney

SPECIES

Canine

BREED

Pit x Lab

SEX

Neutered Male

AGE

14 Years

WEIGHT

35 kg

INTERPRETED BY

R. McKenzie Daniel,
DVM, DABVP
(Canine and Feline)

IMAGING PERFORMED BY

Dr. Callihan

HOSPITAL NAME

Animal Emergency
Care

REFERRING VET

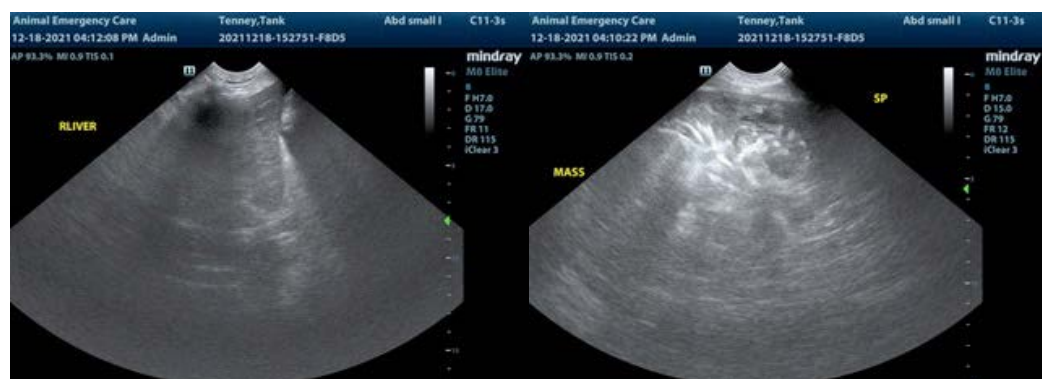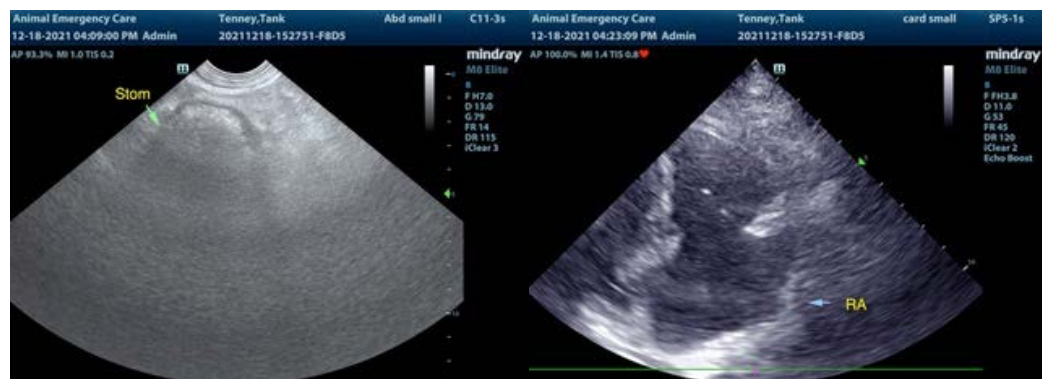
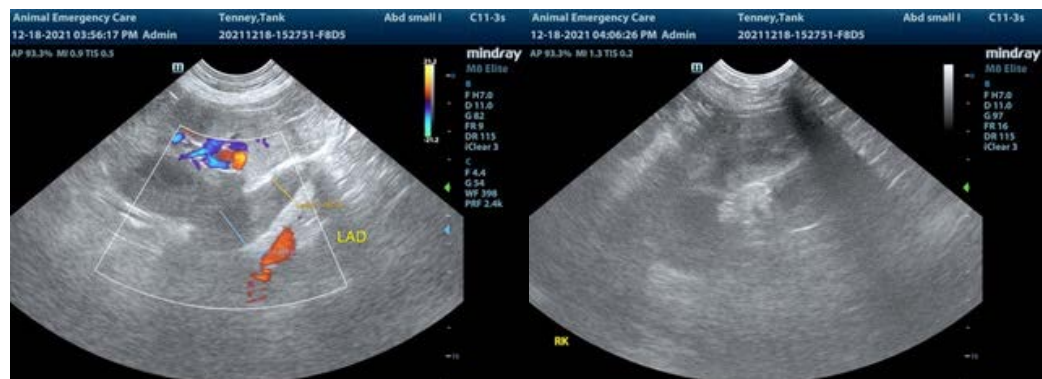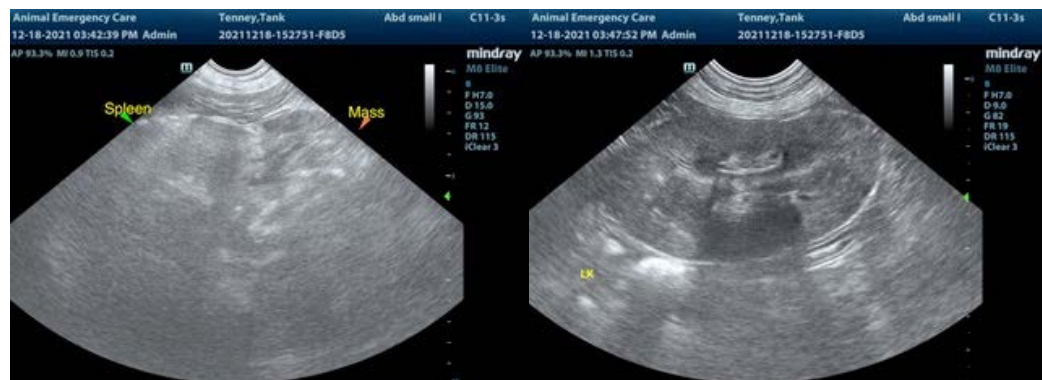
Dr. Callihan

INVOICE

33567

DATE

12/18/21





PATIENT

Tank Tenney

SPECIES

Canine

BREED

Pit x Lab

SEX

Neutered Male

AGE

14 Years

WEIGHT

35 kg

INTERPRETED BY

R. McKenzie Daniel,
DVM, DABVP
(Canine and Feline)

IMAGING PERFORMED BY

Dr. Callihan

HOSPITAL NAME

Animal Emergency
Care

REFERRING VET

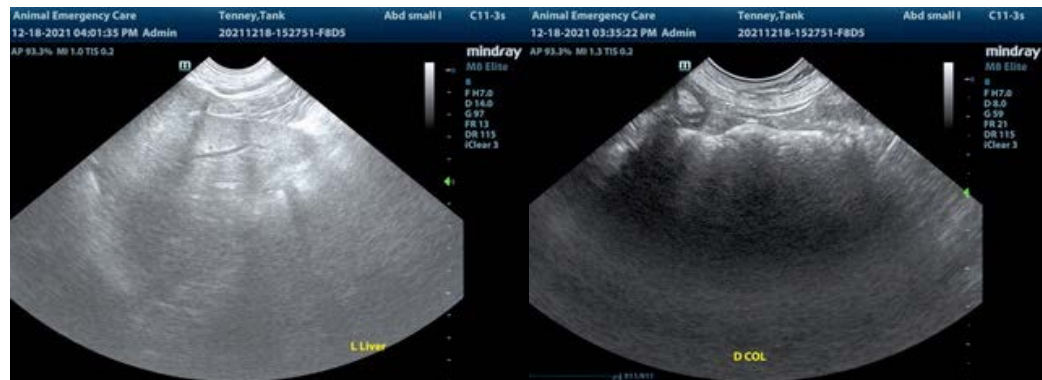Dr. Callihan

INVOICE

33567

DATE

12/18/21



The information and recommendations provided are based on the images presented by the referring veterinarian. No evaluation can be communicated regarding pathology that was not visible in the image/video clips provided.

Thank you for this referral. If the clinical or image interpretation does not parallel your findings or if I can be of any further assistance please contact me.

R. McKenzie Daniel, DVM, DABVP (Canine / Feline Practice)
info@SonoPath.com