



**PATIENT**

Shadow Hegstad

**SPECIES**

Canine

**BREED**

Lab

**SEX**

MN

**AGE**

9 years

**WEIGHT**

53 kg

**INTERPRETED BY**

R. McKenzie Daniel,  
DVM, DABVP  
(Canine and Feline)

**IMAGING PERFORMED BY**

Dr. Callihan/Animal  
Emergency Care

**HOSPITAL NAME**

Animal Emergency  
Care

**REFERRING VET**

Dr. Drummond/AEC

**INVOICE**

12856

**DATE**

12/18/21

**PRESENTING CLINICAL SIGNS**

Pt presented as transfer last night for fever, ADR, urinary tract infection and slight elevation in BUN. His urine SG from rDVM reported as 1.034 with 3+ protein. He was leptotested and positive, though vaccine was boosted last month. He was admitted overnight for antibiotics, diuresis and recheck labs today as well as possible ultrasound. This morning his PCV had dropped and his urine output had been low through the night, checked the USG and it was >1.050 so guessing the initial reading was lab error or from a dipstick rather than refractometer. Checked for free fluid this morning which was reported as neg with primary care yesterday and on admit last night. This morning was positive so I checked coags (normal) and proceeded with ultrasound

Abnormal PE/Chem/CBC/UA Results: CBC mild leukocytosis; mild anemia on admit, PCV now 22%, TP 4.9;

**ULTRASONOGRAPHIC EXAMINATION OF THE ABDOMEN**

**Urinary System**

The urinary bladder presented uniformly mild thickened urinary bladder wall isoechoic to the adjacent normal urinary bladder wall. The luminal margin of the thickened urinary bladder wall was mildly asymmetrical in contour. The ventroapical urinary bladder wall thickness measured 0.63 cm width. Mineralization or echogenic foci within the thickened areas of urinary bladder wall was not present. The urinary bladder, trigone, cystourethral junction, and visible pelvic urethra exhibited normal tone to a depth of 3.0 cm. Anechoic urine was present in the lumen with very mild, nondependent particulate sediment, suggestive of cellular debris, protein, or minor crystalline debris. The ureteral papillae were normal. The ureters were not visible which is normal.

The residual prostate was symmetrically normal in size with uniform parenchyma and slight coarse echotexture measuring 1.4 cm in diameter.

The left kidney exhibited mild to moderate extensive nonhomogeneous mass lesion with disruption of overall discernable left kidney architecture. The discernable left kidney measured approximately 9.7 cm in length, while the overall mass lesion measured at least 12.0 cm in length, but potentially larger. Associated significant left retroperitonitis exhibited by nonuniform hyperechoic retroperitoneal tissue with anechoic to echogenic fluid extending caudally to the approximate level of the urinary bladder.

Normal size and margination were present in the right kidney. A normal 1:3 cortex / medulla ratio was maintained. The medulla and cortices were uniform in texture with some increased echogenicity and mild to moderate loss of corticomedullary symmetry and definition expected for the age of the patient. No evidence of right kidney pyelectasia was present. The right kidney measured 8.8 cm in length. Concurrent right retroperitonitis was present, yet subjectively not as significant as around the left.

**Adrenal Glands**

The left and right adrenal glands were not definitively visualized owing to regional retroperitoneal artifact.

**Spleen**

The spleen exhibited a solitary, mildly expansive, nonhomogeneous nodular mass lesion present in mid spleen, measuring approximately 3.7 cm x 2.5 cm.



**PATIENT**

***Liver/ Gallbladder***

Shadow Hegstad

**SPECIES**

Canine

**BREED**

Lab

**SEX**

MN

**AGE**

9 years

The liver was subjectively normal in size, structure, and contour. The liver parenchyma was mildly nonuniform and hypoechoic to the spleen with a moderate coarse echotexture and subjective mild to benign parenchymal remodeling. The hepatic and portal vasculature were normal in appearance without signs of congestion. No overt hepatic nodules or masses were noted. The gallbladder was non-distended in size with thin walls and primarily anechoic luminal content. The cystic and common bile ducts were normal.

***Gastrointestinal***

The stomach presented intact wall layering with a normal wall layer ratio. The lumen of the stomach was empty with no signs of ileus, obstruction, or foreign material.

The small intestine presented intact wall layering with 1:3 muscularis/mucosa ratio. The lumen of the small intestine was empty with no signs of ileus, obstruction, or foreign material.

Normal visible colon wall layers were present with apparent formed feces in lumen.

**WEIGHT**

53 kg

***Pancreas***

The parenchyma of the left limb, body, and right limb of the pancreas presented isoechoic to the adjacent omental fat. A normal curvilinear capsule contour of the pancreas was present. The visible pancreatic duct was normal. No signs of active inflammation or neoplastic disease were evident.

**INTERPRETED BY**

R. McKenzie Daniel,  
DVM, DABVP  
(Canine and Feline)

***Free Abdomen***

No overt omental lymphadenopathy was present. Mild concurrent peritoneal free fluid was present.

**IMAGING PERFORMED BY**

Dr. Callihan/Animal  
Emergency Care

**ULTRASONOGRAPHIC FINDINGS**

***Primary Findings***

- Mild cystitis
- Left kidney nonhomogeneous mass with associated significant left retroperitonitis
- Right kidney moderate chronic renal changes with concurrent mild right retroperitonitis, possible concurrent nonspecific nephritis
- Nonspecific yet suspicious solitary mildly expansive nonhomogeneous splenic nodular mass lesion
- Concurrent mild peritoneal free fluid

**HOSPITAL NAME**

Animal Emergency  
Care

**REFERRING VET**

Dr. Drummond/AEC

**INVOICE**

12856

**DATE**

12/18/21

**INTERPRETATION OF THE FINDINGS & FURTHER RECOMMENDATIONS**

Potential considerations for the left kidney mass lesion may include neoplasia, infection / abscess, severe nonspecific nephritis, necrosis, or other.

Given the potential for left kidney neoplasia, concern for potential focal splenic metastatic disease is warranted, although benign etiologies for the splenic nodular mass lesion i.e., hematopoiesis, splenitis, hyperplasia are also possible.



**PATIENT**

Shadow Hegstad

**SPECIES**

Canine

**BREED**

Lab

**SEX**

MN

**AGE**

9 years

**WEIGHT**

53 kg

**INTERPRETED BY**

R. McKenzie Daniel,  
DVM, DABVP  
(Canine and Feline)

**IMAGING PERFORMED BY**

Dr. Callihan/Animal  
Emergency Care

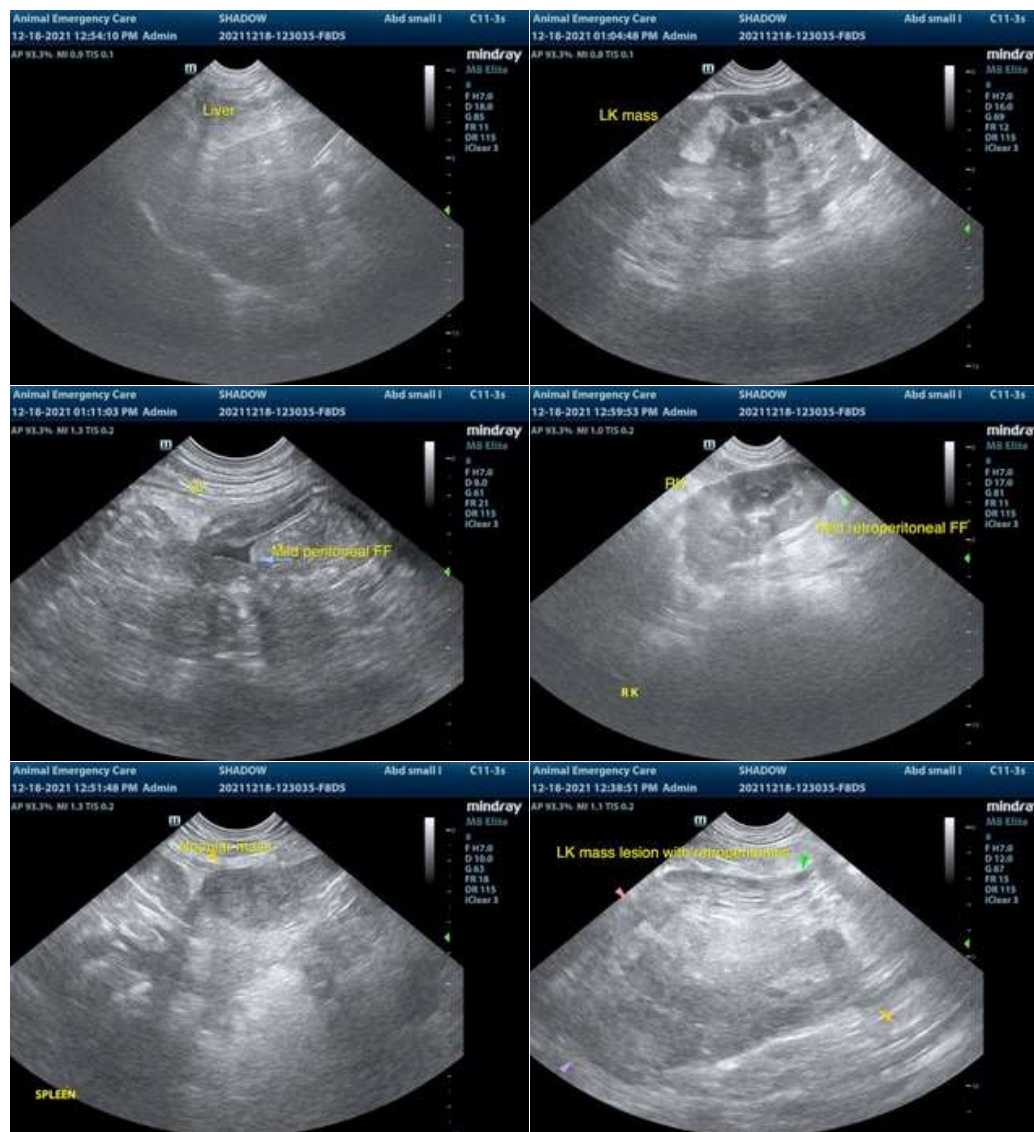
**HOSPITAL NAME**

Animal Emergency  
Care

**REFERRING VET**

Dr. Drummond/AEC

Assuming normal clotting status, ultrasound guided FNA of the left kidney mass and splenic nodular mass lesion, using a 25-gauge needle, could be considered for screening cytology. Urine C/S on ideal sterile urine sample is recommended if not done. Empirically, broad spectrum antibiotics, analgesia, with monitoring of CBC is recommended. Three view chest radiographs are recommended to assess for concurrent thoracic pathology.



**INVOICE**

12856

**DATE**

12/18/21



**PATIENT**

Shadow Hegstad

**SPECIES**

Canine

**BREED**

Lab

**SEX**

MN

**AGE**

9 years

**WEIGHT**

53 kg

**INTERPRETED BY**

R. McKenzie Daniel,  
DVM, DABVP  
(Canine and Feline)

**IMAGING  
PERFORMED BY**

Dr. Callihan/Animal  
Emergency Care

**HOSPITAL NAME**

Animal Emergency  
Care

**REFERRING VET**

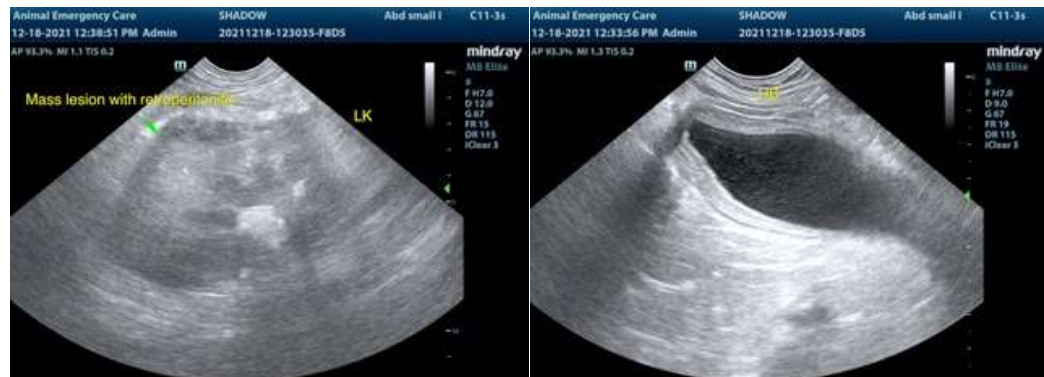Dr. Drummond/AEC

**INVOICE**

12856

**DATE**

12/18/21



**The information and recommendations provided are based on the images presented by the referring veterinarian. No evaluation can be communicated regarding pathology that was not visible in the image/video clips provided.**

Thank you for this referral. If the clinical or image interpretation does not parallel your findings or if I can be of any further assistance please contact me.

**R. McKenzie Daniel, DVM, DABVP (Canine / Feline Practice)**  
info@SonoPath.com