



PATIENT

Charlee Bradley

SPECIES

Canine

BREED

Puggle

SEX

FS

AGE

5

WEIGHT

30 lbs.

INTERPRETED BY

R. McKenzie Daniel,
DVM, DABVP
(Canine and Feline)

IMAGING PERFORMED BY

Chaley Hunt, LVT

HOSPITAL NAME

Columbia AC

REFERRING VET

Dr. Michelle Engel

INVOICE

12850

DATE

12/18/21

PRESENTING CLINICAL SIGNS

Got in to the trash on Tuesday and didn't want to eat much since then. Seems nauseous. Started Cerenia, metronidazole, Ampicillin, IV fluids yesterday, no vomiting we are aware of. CBC yesterday had HCT of 25%, PCV today is 13%. Patient is pale today, still not wanting to eat.

Abnormal PE/Chem/CBC/UA Results: 12/17821 CBC: RBC = 3.79, HCT, 24.9%, Hemoglobin = 8.7, Retics = 155.4, WBC = 24.33, Neutrophils, 18.68, Monocytes = 1.94, Platlets = 139 Chemistry: ALKP = 220, Total Bili = 1.4 12/18: PCV= 13%, T/S = 6.2 g/dL

Radiographs- submitted radiographs revealed retained nonshadowing ingesta present in the stomach with mild increased segmental small intestinal gas pattern with no overt evidence of gastrointestinal obstructive pattern or metallic opacity.

ULTRASONOGRAPHIC EXAMINATION OF THE ABDOMEN

Urinary System

The urinary bladder, trigone, cystourethral junction, and visible pelvic urethra to a depth of 3.0 cm exhibited normal thickness and tone. Minor, nondependent, particulate sediment, which may indicate minor cellular or crystalline debris or potential minor mucus. The ureteral papillae were normal. The ureters were not visible which is normal. No evidence of inflammatory or neoplastic changes was noted.

No evidence of pathology was noted in the area of the uterine remnant or aortic trifurcation.

Normal size and margination were present in the kidneys. A normal 1:3 cortex / medulla ratio and normal corticomedullary definition were maintained. The echogenicity of the cortex was similar to or slightly less than normal liver parenchyma while the medulla echogenicity was hypoechoic to the cortex with no evidence of pyelectasia. The left kidney measured 5.5 cm in length. The right kidney measured 6.0 cm in length.

Adrenal Glands

The left adrenal gland was uniform in size and contour with a uniformly hypoechoic parenchyma. The left adrenal gland measured 0.46 cm width at the caudal pole and 0.56 cm width at the cranial pole. The right adrenal gland was indistinctly visualized, subjectively measuring 0.65 cm width at the caudal pole.

Spleen

The spleen exhibited normal size and contour with generalized mild splenic parenchyma heterogeneity. A solitary, mildly expansive hypoechoic parenchymal nodule was present in the mid parenchyma, measuring 1.3 cm in diameter.

Liver/ Gallbladder

The liver presented enlarged in size. The parenchyma of the liver was subjectively normal in echogenicity compared to the spleen and renal cortices. The liver parenchyma was uniform with a mildly coarse echotexture. The capsule of the liver was symmetrically rounded to mildly swollen in margination. The hepatic and portal vasculature were normal in appearance without signs of congestion. The gallbladder was non-distended in size with primarily anechoic luminal content. No evidence of post hepatic stasis or obstruction was noted. The cystic and common bile ducts were normal.



PATIENT

Charlee Bradley

SPECIES

Canine

BREED

Puggle

SEX

FS

AGE

5

WEIGHT

30 lbs.

INTERPRETED BY

R. McKenzie Daniel,
DVM, DABVP
(Canine and Feline)

IMAGING PERFORMED BY

Chaley Hunt, LVT

HOSPITAL NAME

Columbia AC

REFERRING VET

Dr. Michelle Engel

INVOICE

12850

DATE

12/18/21

Gastrointestinal

The stomach presented intact yet subjective mild prominent wall layering. The stomach contained a mild amount of retained, variably echogenic ingesta with no evidence of distal acoustic shadowing present in the gastric lumen. The ventral gastric body wall width measured 0.48 cm.

The small intestine presented intact wall layering with 1:3 muscularis/mucosa ratio. The jejunum wall width measured 0.40 cm. The duodenum wall width measured 0.42 cm. No evidence of mechanical / metabolic small intestinal ileus or overt foreign material was noted.

Normal visible colon wall layers were present with apparent formed feces in lumen.

Pancreas

The pancreas was normal in size and contour with isoechoic to heterogeneous parenchyma compared to adjacent omentum. No signs of active inflammation or neoplasia.

Free Abdomen

No omental masse, lymphadenopathy or peritoneal effusion were present.

ULTRASONOGRAPHIC FINDINGS

Primary Findings

- Normal splenic size exhibited generalized mild parenchyma heterogeneity and solitary, mildly expansive, hypoechoic parenchymal nodule
- Mild hepatopathy - subjectively benign
- Probable mild gastritis with retained ingesta, sonographically unremarkable small bowel - potential for gastric hypomotility if documented NPO
- Mildly heterogeneous pancreas - nonspecific, patient variant, potential for low-grade to chronic possibly resolving pancreatitis possible

INTERPRETATION OF THE FINDINGS & FURTHER RECOMMENDATIONS

Potential etiologies for the splenic nodule may include benign processes such as nodular hyperplasia, extramedullary hematopoiesis, hematoma, infection, infarction, or neoplasia. Ultrasound guided FNA of the nodule, as well as splenic parenchyma, using 25-gauge needle and assuming normal coagulation parameters is warranted. Otherwise, sonographic monitoring of the splenic nodule for any changes in size or appearance with initial recheck in 3-4 weeks would be a more conservative approach.

Aside from potential splenic pathology, an obvious cause of the worsening anemia was not definitively evident. Assessment for evidence of autoagglutination or hemolysis in light of mild elevated total bilirubin is recommended. Conservative as-needed gastrointestinal care and conservative therapy for potential low-grade pancreatitis is indicated. Some or all of the following protocol may also be considered based on the clinical impression of the patient.



PATIENT

Charlee Bradley

(Note: ensure no underlying neoplasia as IMHA/Evans syndrome can occur as paraneoplastic manifestation especially in lymphoma/round cell neoplasia)

SPECIES

Canine

Anemia +/- thrombocytopenia with spherocytes/autoagglutination in dogs and hyperbilirubinemia, bilirubinuria. (NOTE: cats do not get spherocytes in IMHA)

Consider Onion/Garlic derivative ingestion if Heinz bodies present.

BREED

Puggle

Prednisone (K9) Prednisolone (Feline): 2 mg/kg Sid/Bid initially x 3 weeks then attempt taper

Aspirin 0.5 mg/kg Sid owing to hypercoagulable state

Sucralfate 0.5-1 g po tid dogs, 0.5 g bid cats in slurry

Doxycycline if infectious suspected clinically or based on CBC path review:

Dogs, Cats: 10 mg/kg p.o. q24h with food or water bolus in cats

SEX

FS

Long-term management dogs: Azothiaprine 2 mg/kg Sid or Cyclosporine 10mg/kg po sid bid

AGE

5

WEIGHT

30 lbs.

INTERPRETED BY

R. McKenzie Daniel,
DVM, DABVP
(Canine and Feline)

IMAGING PERFORMED BY

Chaley Hunt, LVT

HOSPITAL NAME

Columbia AC

REFERRING VET

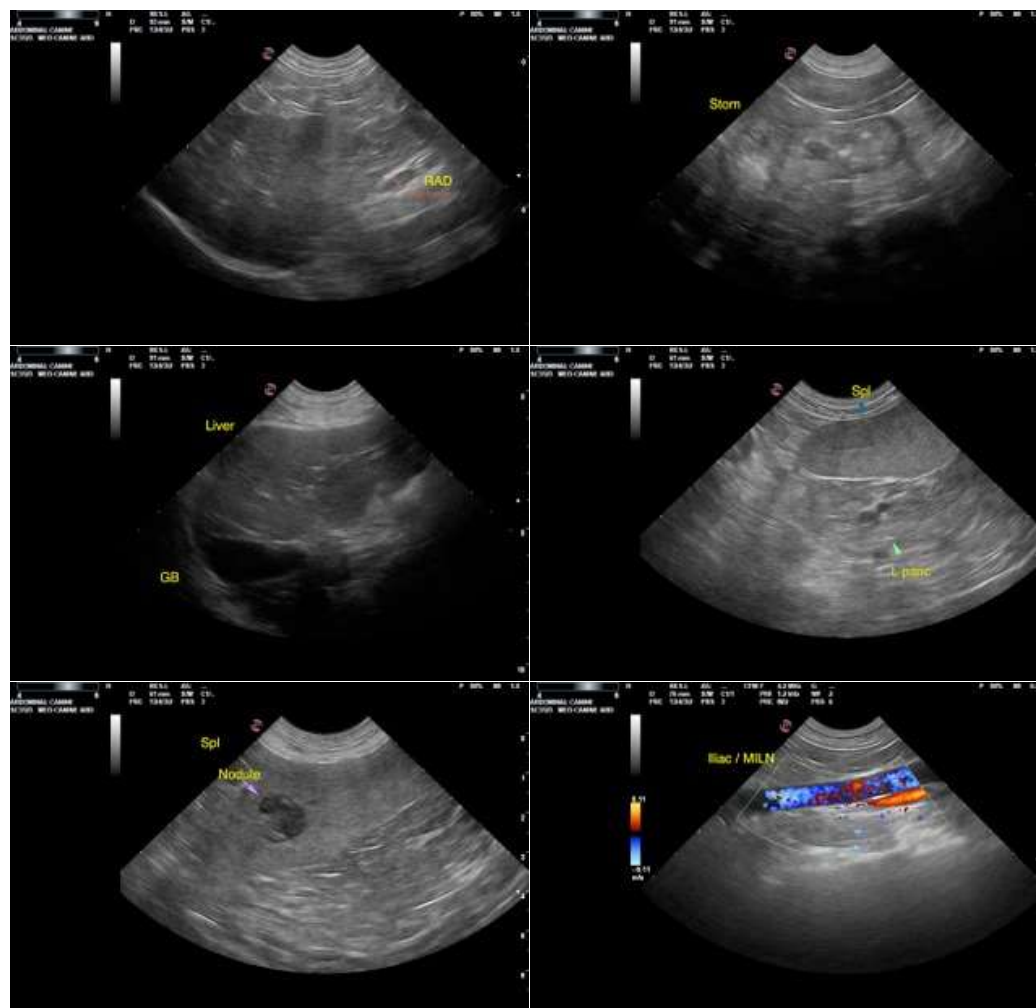
Dr. Michelle Engel

INVOICE

12850

DATE

12/18/21





PATIENT

Charlee Bradley

SPECIES

Canine

BREED

Puggle

SEX

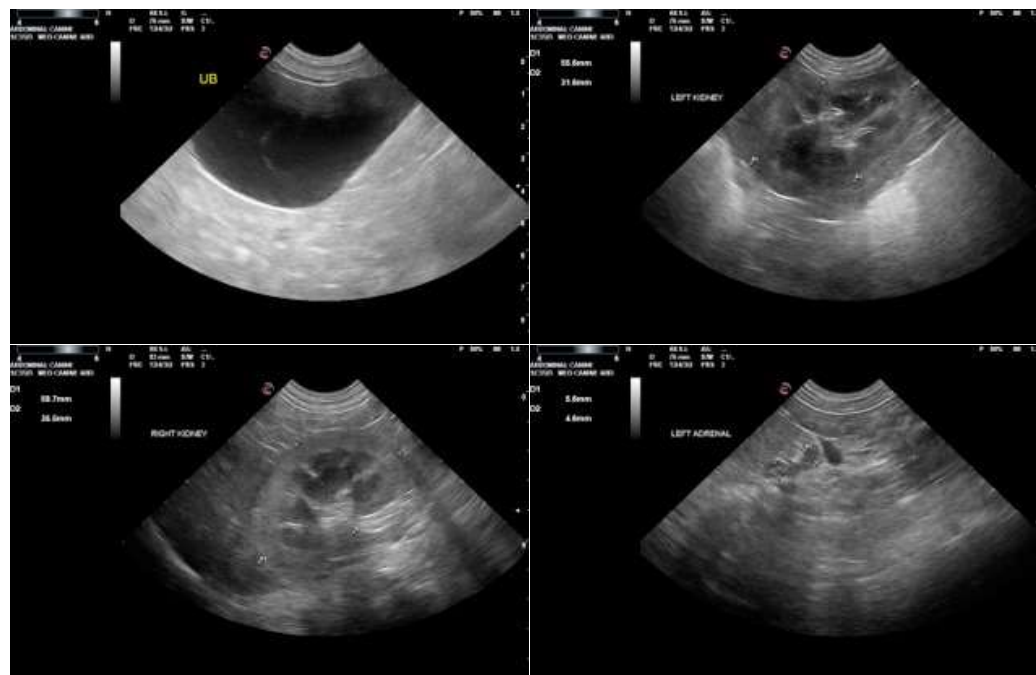
FS

AGE

5

WEIGHT

30 lbs.



INTERPRETED BY

R. McKenzie Daniel,
DVM, DABVP
(Canine and Feline)

IMAGING PERFORMED BY

Chaley Hunt, LVT

HOSPITAL NAME

Columbia AC

REFERRING VET

Dr. Michelle Engel

INVOICE

12850

DATE

12/18/21

The information and recommendations provided are based on the images presented by the referring veterinarian. No evaluation can be communicated regarding pathology that was not visible in the image/video clips provided.

Thank you for this referral. If the clinical or image interpretation does not parallel your findings or if I can be of any further assistance please contact me.

R. McKenzie Daniel, DVM, DABVP (Canine / Feline Practice)
info@SonoPath.com