

**PATIENT**

Sally Masengarb

**SPECIES**

Feline

**BREED**

DSH

**SEX**

SF

**AGE**

15 years

**WEIGHT**

14 lbs

**INTERPRETED BY**

R. McKenzie Daniel,  
DVM, DABVP  
(Canine and Feline)

**IMAGING PERFORMED BY**

Sarah Pender, CVT

**HOSPITAL NAME**

SVS Imaging QC

**REFERRING VET**

Dr. Joe Westerhof

**INVOICE**

12847

**DATE**

12/17/21

**PRESENTING CLINICAL SIGNS**

Running a fever of 104 since 12/14, vomiting; history of pancreatitis and gall stones  
Abnormal PE/Chem/CBC/UA Results: Non- painful abdomen

**ULTRASONOGRAPHIC EXAMINATION OF THE ABDOMEN****Urinary System**

The urinary bladder, trigone, cystourethral junction, and visible pelvic urethra to a depth of 2.0 cm exhibited normal thickness and tone. Primarily anechoic urine was present in the lumen. Mild, nondependent, particulate sediment was present without evidence of calculus formation. The ureteral papillae were normal. The ureters were not visible which is normal. No evidence of inflammatory or neoplastic mural changes were noted.

The area of the aortic trifurcation was free of pathology.

Normal size and margination were present in the kidneys. A normal 1:3 cortex / medulla ratio and normal corticomedullary definition were maintained. The echogenicity of the cortex was similar to or slightly less than normal liver parenchyma while the medulla echogenicity was hypoechoic to the cortex with no evidence of pelvic dilation. The left kidney measured 3.9 cm in length. The right kidney measured 4.2 cm in length.

**Adrenal Glands**

The left adrenal gland was uniform in size and contour with a uniformly hypoechoic parenchyma. The left adrenal gland measured 0.36 cm width. The right adrenal gland was uniform in size and contour with a uniformly hypoechoic parenchyma. The right adrenal gland measured 0.48 cm width.

**Spleen**

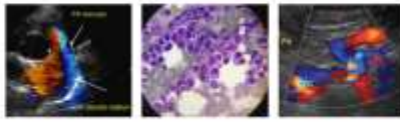The spleen exhibited borderline to mild generalized enlargement yet maintained symmetrical capsule contour and overall finely textured homogeneous parenchyma. The spleen measured 1.1 cm width.

**Liver/ Gallbladder**

The liver exhibited potential for mild enlargement. The parenchyma of the liver was subjectively normal in echogenicity compared to the spleen and renal cortices. The liver parenchyma was uniform with a mildly coarse echotexture. The capsule of the liver was symmetrically rounded to mildly swollen in margination. The hepatic and portal vasculature were normal in appearance without signs of congestion. The gallbladder was non-distended in size. A solitary cholelith was present in the gallbladder lumen, measuring 0.5 cm in diameter. No evidence of gallbladder or peripheral inflammation was noted. The proximal common bile duct was dilated and tortuous. The common bile duct dilation measured 0.27 cm, not consistent with post hepatic obstruction.

**Gastrointestinal**

The stomach presented intact wall layering with a normal wall layer ratio. The lumen of the stomach was empty with no signs of ileus, obstruction, or foreign material. The gastric body wall width measured 0.29 cm.

**PATIENT**

Sally Masengarb

The duodenum exhibited intact yet mild prominent wall layering along with mild duodenal corrugation. The duodenum wall width measured 0.29 cm. The jejunum and ileum to the level of the ileocolic junction were sonographically normal exhibiting intact wall layering and maintained a 1:3 muscularis/mucosa ratio. The jejunum wall width measured 0.22 cm. The ileocolic wall width measured 0.34 cm.

**SPECIES**

Feline

The proximal colon was mildly distended with nonformed to shadowing feces. Potential for small hairball density in the proximal colon is possible, although not definitive. The colon exhibited intact, sonographically normal wall layering.

**BREED**

DSH

***Pancreas***

The pancreas was mildly prominent in size with heterogeneous to mildly nonuniform parenchyma.

**SEX**

SF

***Free Abdomen***

No evidence of significant lymphadenopathy was noted. No omental masses or peritoneal effusion were present.

**AGE**

15 years

**ULTRASONOGRAPHIC FINDINGS*****Primary Findings***

- Mild particulate urinary bladder sediment
- Borderline splenomegaly - subjectively benign
- Solitary, nonobstructive cholelith with mild nonobstructive proximal common bile duct dilation - potential cholangitis
- Heterogeneous pancreas - low-grade chronic to chronic active pancreatitis possible
- Duodenitis, potential for generalized inflammatory bowel episode

**INTERPRETED BY**

R. McKenzie Daniel,  
DVM, DABVP  
(Canine and Feline)

**INTERPRETATION OF THE FINDINGS & FURTHER RECOMMENDATIONS**

Overall, no overt evidence of significant visceral pathology, specifically no evidence of neoplastic criteria, abscessation, or other as an obvious cause of the patient's fever were noted. Potential for inflammatory bowel episode, low-grade to chronic pancreatitis, and hepatobiliary Inflammation are possible. Correlation with a full CBC/Chemistry Panel is recommended. Supportive care should prove beneficial.

**IMAGING PERFORMED BY**

Sarah Pender, CVT

**HOSPITAL NAME**

SVS Imaging QC

**REFERRING VET**

Dr. Joe Westerhof

The urinary bladder sediment may suggest cellular / crystalline debris or mucus. Cystocentesis for UA +/- C/S if evidence of inflammatory cells is recommended.

Three view chest radiographs suggested to rule out thoracic pathology. Recheck sonogram is suggested to assess for progressive inflammatory pancreatic, hepatic, or intestinal changes if clinical signs continue.

**INVOICE**

12847

**DATE**

12/17/21



**PATIENT**

Sally Masengarb

**SPECIES**

Feline

**BREED**

DSH

**SEX**

SF

**AGE**

15 years

**WEIGHT**

14 lbs

**INTERPRETED BY**

R. McKenzie Daniel,  
DVM, DABVP  
(Canine and Feline)

**IMAGING PERFORMED BY**

Sarah Pender, CVT

**HOSPITAL NAME**

SVS Imaging QC

**REFERRING VET**

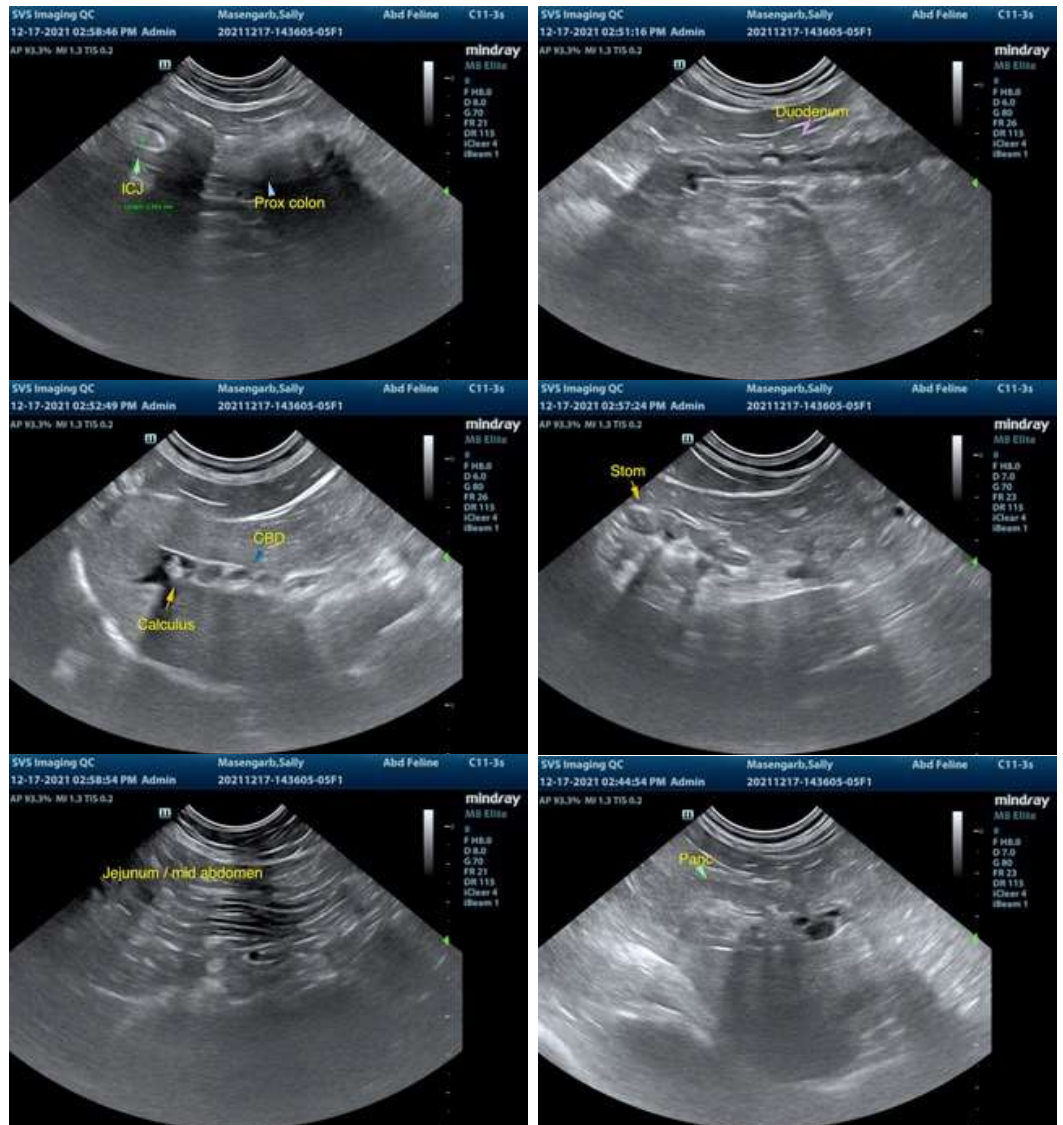
Dr. Joe Westerhof

**INVOICE**

12847

**DATE**

12/17/21





**PATIENT**

Sally Masengarb

**SPECIES**

Feline

**BREED**

DSH

**SEX**

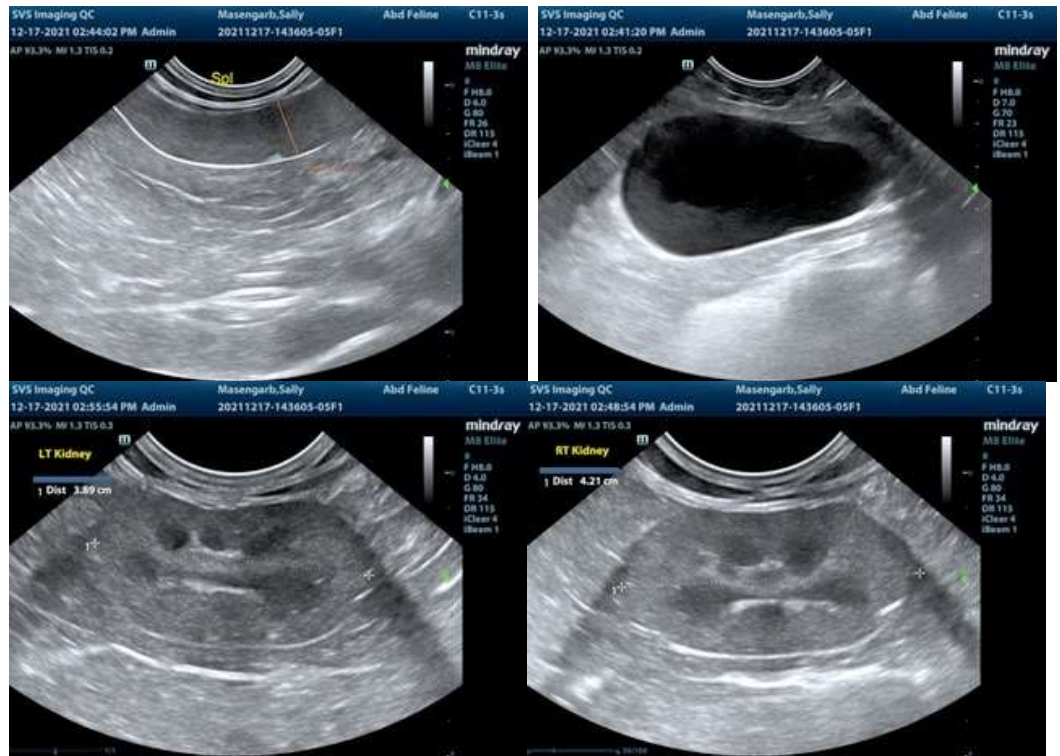
SF

**AGE**

15 years

**WEIGHT**

14 lbs



**INTERPRETED BY**

R. McKenzie Daniel, DVM, DABVP (Canine and Feline)

**IMAGING PERFORMED BY**

Sarah Pender, CVT

**HOSPITAL NAME**

SVS Imaging QC

**REFERRING VET**

Dr. Joe Westerhof

**INVOICE**

12847

**DATE**

12/17/21

The information and recommendations provided are based on the images presented by the referring veterinarian. No evaluation can be communicated regarding pathology that was not visible in the image/video clips provided.

Thank you for this referral. If the clinical or image interpretation does not parallel your findings or if I can be of any further assistance please contact me.

R. McKenzie Daniel, DVM, DABVP (Canine / Feline Practice)  
info@SonoPath.com