



PATIENT

Phoebe Dresser

SPECIES

Canine

BREED

French Bulldog

SEX

Spayed Female

AGE

1 Year

WEIGHT

PRESENTING CLINICAL SIGNS

5d hx of ADR, V+/D+ lethargic. However, hx of recurrent GI issues requiring hosp supportive care over the last year.

Abnormal PE/Chem/CBC/UA Results: Baseline bloodwork-CBC: all wnl; Chem10: all wnl; EPOC: Lactate 6.3, rest wnl. aFAST: no FF, no obvious fluid filled bowel loops. Small amount of shadowing material in the stomach. Urine drug screening - weak positive THC and Opiates. PT/PTT- normal. cPL- abnormal. Rads unremarkable. Recheck EPOC today WNL except persistently elevated LAC (5.6)

ULTRASONOGRAPHIC EXAMINATION OF THE ABDOMEN

Urinary System

The urinary bladder, trigone, cystourethral junction, and visible pelvic urethra to a depth of 3.0 cm exhibited normal thickness and tone. Anechoic urine was present in the lumen with no uroliths or sediment. The ureteral papillae were normal. The ureters were not visible which is normal. No evidence of inflammatory or neoplastic changes were noted.

The area of the aortic trifurcation was free of pathology.

Normal size and margination were present in the kidneys. A normal 1:3 cortex / medulla ratio and normal corticomedullary definition were maintained. The echogenicity of the cortex was similar to or slightly less than normal liver parenchyma while the medulla echogenicity was hypoechoic to the cortex with no evidence of pelvic dilation. The left kidney measured 4.2 cm. The right kidney measured 4.8 cm.

Adrenal Glands

The adrenal glands were uniform in size and contour with a uniformly hypoechoic parenchyma. The left adrenal gland measured 0.31 cm at the cranial pole and 0.50 cm at the caudal pole. The right adrenal gland measured 0.35 cm at the cranial pole and 0.35 cm at the caudal pole.

Spleen

The spleen exhibited a finely textured and homogenous parenchyma which was hyperechoic to the liver and renal cortical parenchyma. The capsule was smooth and regular without apparent expansion. The splenic vasculature at the hilus was normal in volume with no evidence of congestion or thrombosis. Acute to chronic inflammatory, neoplastic, or benign parenchyma changes were not noted.

Liver

The liver was subjectively normal in size, structure, and contour. The liver parenchyma was uniform and hypoechoic to the spleen with a mild coarse echotexture. The hepatic and portal vasculature were normal in appearance without signs of congestion. The gallbladder was non-distended in size with thin walls and primarily anechoic luminal content. The cystic and common bile ducts were normal.

Gastrointestinal

The stomach presented intact wall layering with a normal wall layer ratio. Mild retained echogenic, non-shadowing ingesta/chyme present. Gastric and pylorus walls measured 0.34 cm. No overt evidence of foreign material or mechanical pyloric outflow obstruction.

The small intestine presented intact wall layering with primarily maintained 1:3 muscularis/mucosa ratio with subtle subjective propensity for mildly prominent small intestinal mucosa. The lumen of the small intestine was empty with no signs of ileus, obstruction or foreign material. Jejunum wall measured 0.25-0.30 cm. Duodenum wall measured 0.55 cm. Intermittent areas of subtle duodenojejunal mucosal speckling were present.

INTERPRETED BY

R. McKenzie Daniel,
DVM, DABVP
(Canine and Feline)

IMAGING PERFORMED BY

Dr. Cathy Carter

HOSPITAL NAME

Willamette VH

REFERRING VET

Dr. Hannah Loeffler

INVOICE

33531

DATE

12/17/21



PATIENT

Normal visible colon wall layers were present with apparent formed feces in lumen.

Phoebe Dresser

Pancreas

SPECIES

The left limb, right limb, and base of the pancreas presented hypoechoic to heterogeneous echogenicity compared to adjacent omental fat. Mild asymmetrical capsule margination was present with mild variable parenchymal swelling and mild peripancreatic inflammation. No overt evidence of neoplasia.

Canine

Free Abdomen

BREED

No omental masses, lymphadenopathy or peritoneal effusion.

French Bulldog

ULTRASONOGRAPHIC FINDINGS

SEX

- Gastroenteritis pattern – possible chronic inflammatory enteropathy in light of patient’s recurrent gastrointestinal signs.
- Mild pancreatitis

Spayed Female

INTERPRETATION OF THE FINDINGS & FURTHER RECOMMENDATIONS

AGE

Assessment for evidence of cranial abdominal or subxiphoid discomfort on palpation in the area of the pancreas recommended. Further correlation with GI panel to include PLI, TLI, cobalamin and folate (given the patient’s recurrent gastrointestinal signs) could be considered. Empirical therapy for gastroenteritis/pancreatitis should prove beneficial. Assessment of hydration suggested if not done given the persistent elevated Lactate.

1 Year

WEIGHT

INTERPRETED BY

R. McKenzie Daniel,
DVM, DABVP
(Canine and Feline)

IMAGING PERFORMED BY

Dr. Cathy Carter

HOSPITAL NAME

Willamette VH

REFERRING VET

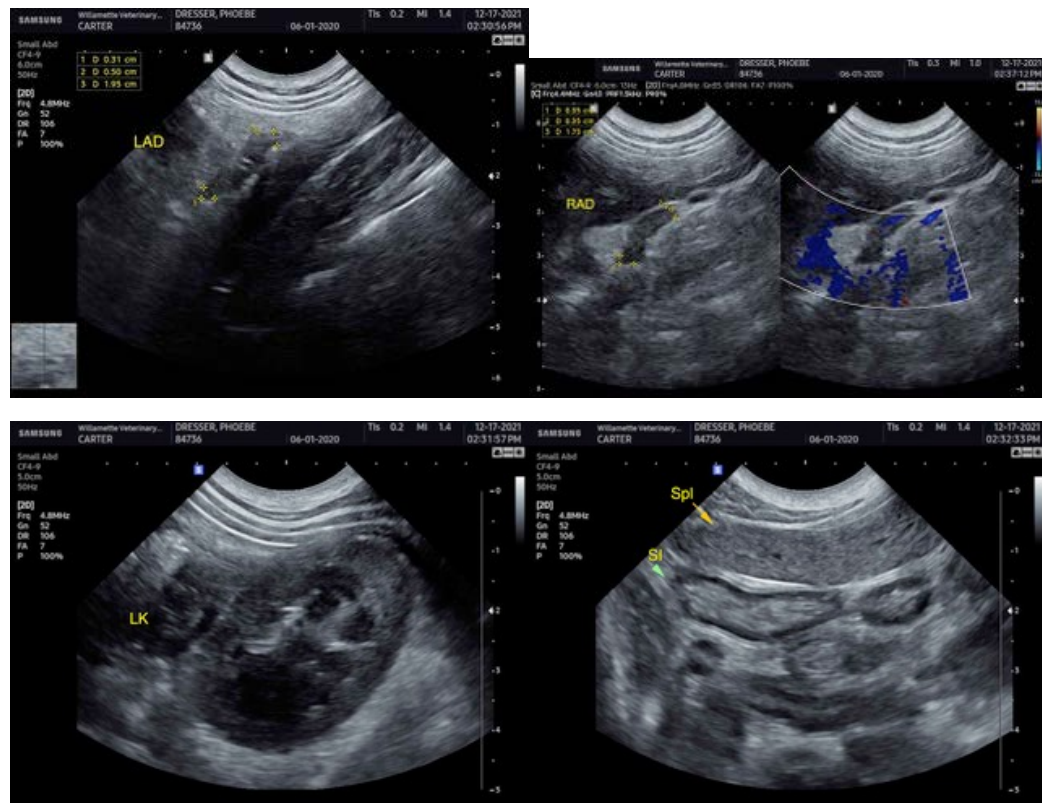
Dr. Hannah Loeffler

INVOICE

33531

DATE

12/17/21





PATIENT

Phoebe Dresser

SPECIES

Canine

BREED

French Bulldog

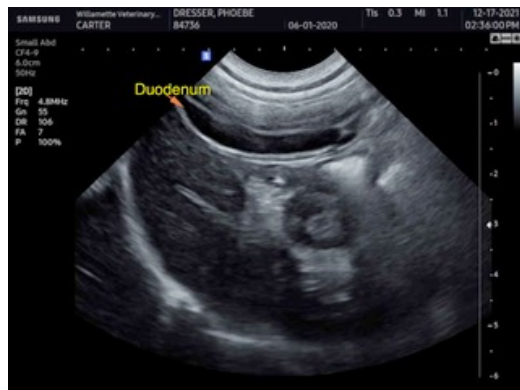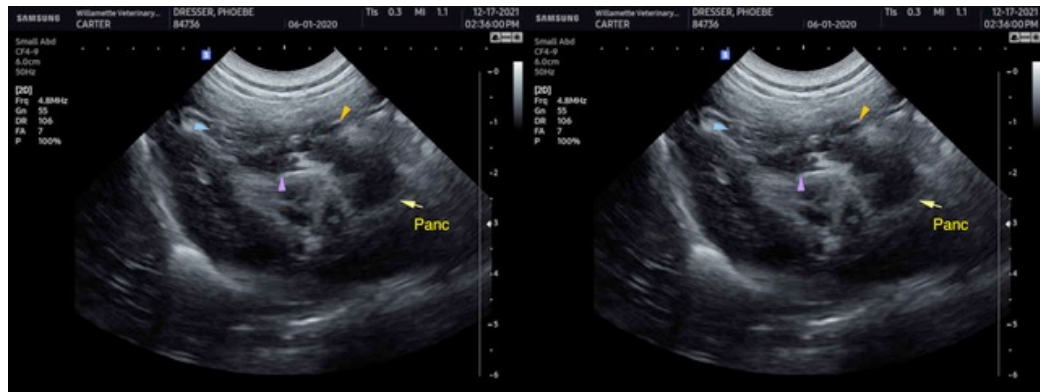
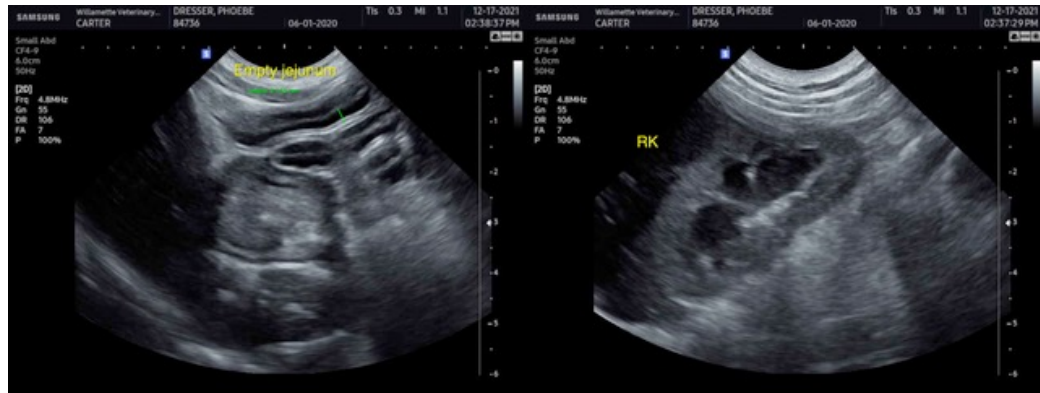
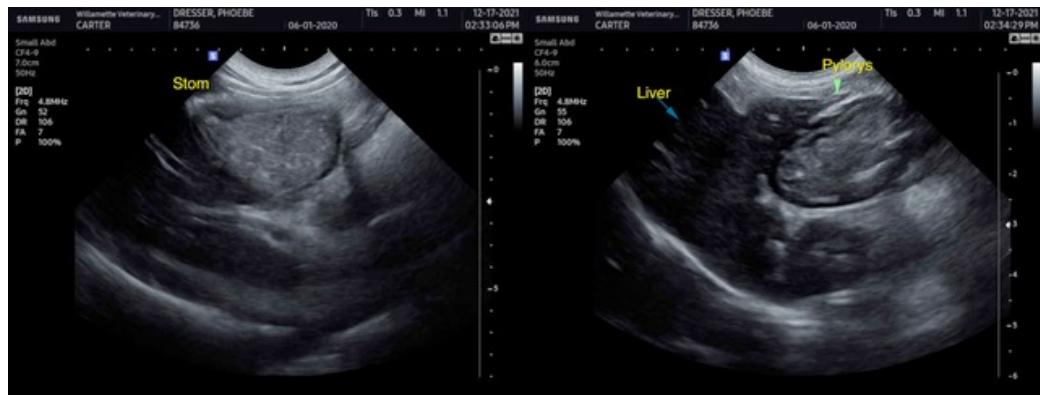
SEX

Spayed Female

AGE

1 Year

WEIGHT



INTERPRETED BY

R. McKenzie Daniel,
DVM, DABVP
(Canine and Feline)

IMAGING PERFORMED BY

Dr. Cathy Carter

HOSPITAL NAME

Willamette VH

REFERRING VET

Dr. Hannah Loeffler

INVOICE

33531

DATE

12/17/21



PATIENT

Phoebe Dresser

The information and recommendations provided are based on the images presented by the referring veterinarian. No evaluation can be communicated regarding pathology that was not visible in the image/video clips provided.

SPECIES

Canine

Thank you for this referral. If the clinical or image interpretation does not parallel your findings or if I can be of any further assistance please contact me.

BREED

French Bulldog

R. McKenzie Daniel, DVM, DABVP (Canine / Feline Practice)
info@SonoPath.com

SEX

Spayed Female

AGE

1 Year

WEIGHT

INTERPRETED BY

R. McKenzie Daniel,
DVM, DABVP
(Canine and Feline)

**IMAGING
PERFORMED BY**

Dr. Cathy Carter

HOSPITAL NAME

Willamette VH

REFERRING VET

Dr. Hannah Loeffler

INVOICE

33531

DATE

12/17/21