

PATIENT

Jack Costa

SPECIES

Canine

BREED

Cavachon

SEX

MN

AGE

12 yrs

WEIGHT

6.3 kg

INTERPRETED BY

R. McKenzie Daniel,
 DVM, DABVP
 (Canine and Feline)

IMAGING PERFORMED BY

Kelly Reschny

HOSPITAL NAME

Vet for Life AH

REFERRING VET

Bajaj

INVOICE

10459

DATE

12/16/25

PRESENTING CLINICAL SIGNS

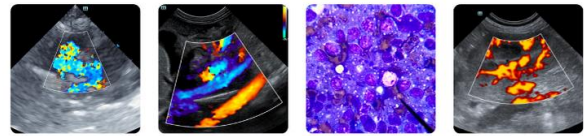
GRADE 4-5/6 HEART MURMUR. COUGHING FROM PAST FEW WEEKS.

ULTRASONOGRAPHIC EXAMINATION OF THE HEART

CANINE CARDIAC PARAMETERS	MR VMAX (m/s)	TR VMAX (m/s)	LA/AO (M-Mode)	LA/AO (Heart Base; Swe)	FS (%)	EF (%)	EPSS (cm)
NORMAL PARAMETER	4.5-5.5	<2.7	1.3	Up to 1.6	28-40	40-100	<0.6
PATIENT				1.6	52	85	0.2
CANINE CARDIAC PARAMETERS	HR (BPM)	AV VMAX (m/s)	PV MAX (m/s)	BODY WEIGHT (kg)	LAD LA MAX 4 Chamber	LVIDd Avg; 2D and m-mode short axis (cm)	LVIDs Avg; 2D and m-mode short axis (cm)
NORMAL PARAMETER	50-100	0.7-1.7	0.7-1.6				
PATIENT	110	1.3	1.0		3.3	3.1	

Cardiac Presentation

The echocardiogram in this patient demonstrated mild increased **left atrial** size based on 2 different LA measurement methods. The cranial and caudal **mitral** valve leaflets presented thickening consistent with endocardiosis with mild septal leaflet prolapse. Doppler indicated measurable moderate to significant eccentric insufficiency (MR velocity 5.6 m/s). The **left ventricle** presented mild increased internal dimension with linear contour and was not dilated nor restricted. The **myocardium** presented normal echogenicity without subjective evidence of significant fibrotic or ischemic disease. **Contractility** of the ventricular walls was adequate and in normal range for this patient evidenced by the fractional shortening measurement and subjective evaluation of the different regions of the myocardium. The **left ventricular outflow** tract demonstrated normal laminar flow and subjective structural integrity. The **right atrium** and auricle revealed normal size, structure and content. No evidence of masses was noted or chamber overload. **Tricuspid** valvular assessment demonstrated adequate linear morphology. No evidence of overt significant TR on Doppler. The **right ventricle** was of normal size (1/3 diameter of LV), chordae structure, myocardial echogenicity and thickness. **Pulmonic** tract assessment revealed normal valve structure, laminar flow, and diameter (approx. 1:1 pa/ao ratio). No visible **pericardial** or free pleura fluid was noted. No echographically detectable evidence of cardiac / pericardial tumors was visible. No evidence of arrhythmia was noted.



PATIENT

Jack Costa

SPECIES

Canine

BREED

Cavachon

SEX

MN

AGE

12 yrs

WEIGHT

6.3 kg

ULTRASONOGRAPHIC FINDINGS

- Chronic mitral valve disease with mild valve prolapse (ACVIM B2)

INTERPRETATION OF THE FINDINGS & FURTHER RECOMMENDATIONS

The cause of the murmur is chronic degenerative valvular changes with secondary eccentric mitral valve insufficiency. The left atrial enlargement implies that the risk of complications secondary to mitral valve insufficiency is elevated, yet overall, the heart appears stable. No other clinical issues, such as LV systolic dysfunction or clinical pulmonary hypertension. The coughing in this patient is suspected to be noncardiogenic in origin.

Pimobendan 0.3 mg/kg BID is warranted with concurrent respiratory support. No overt indication for additional medication. Prognosis is considered variable and sonographic monitoring is recommended. Recheck echocardiogram is suggested in 6 months, sooner if clinical signs arise. Anesthetic risk is considered mildly elevated at this stage, yet likely mildly reduced once on Pimobendan for 3-5 days. If required, the following protocol is suggested. Suggested anesthetic protocol may include opioid or Benzodiazepine pre-med, induction with Propofol or Alfaxalone, and appropriate gas anesthesia with avoidance of alpha 2 agonists.

INTERPRETED BY

R. McKenzie Daniel,
 DVM, DABVP
 (Canine and Feline)

IMAGING PERFORMED BY

Kelly Reschny

HOSPITAL NAME

Vet for Life AH

REFERRING VET

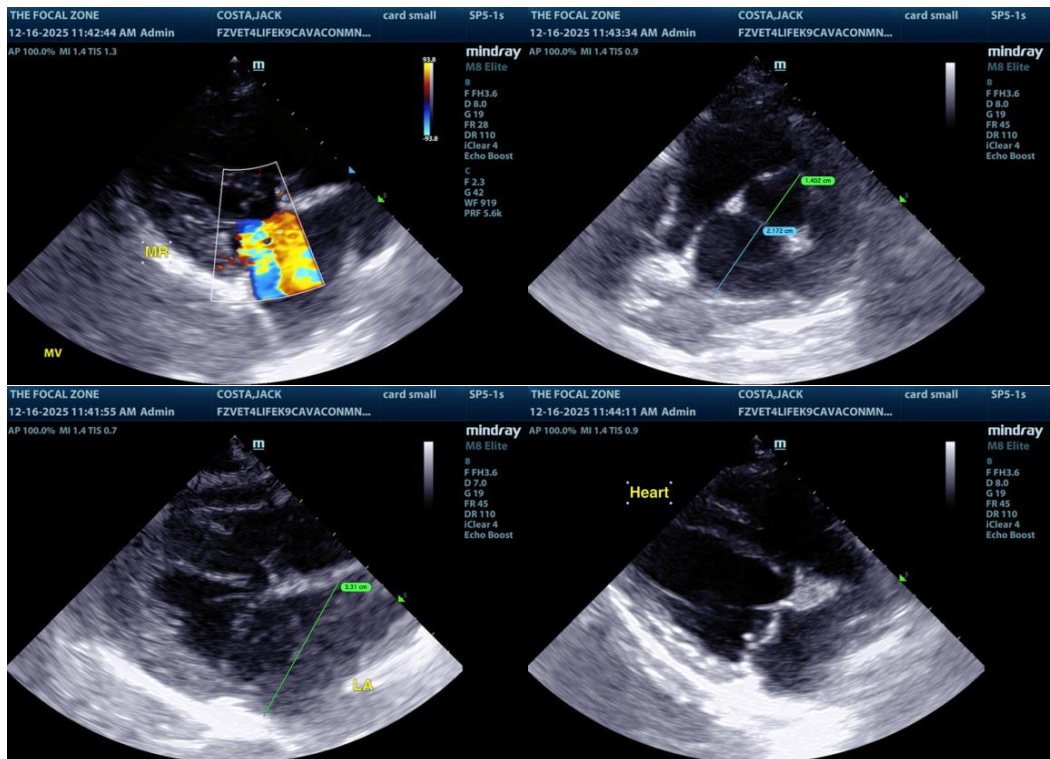
Bajaj

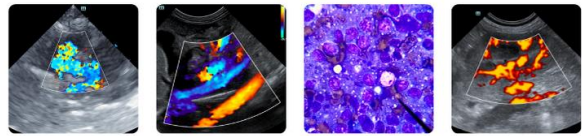
INVOICE

10459

DATE

12/16/25





PATIENT

Jack Costa

SPECIES

Canine

BREED

Cavachon

SEX

MN

AGE

12 yrs

WEIGHT

6.3 kg

INTERPRETED BY

R. McKenzie Daniel,
DVM, DABVP
(Canine and Feline)

**IMAGING
PERFORMED BY**

Kelly Reschny

HOSPITAL NAME

Vet for Life AH

REFERRING VET

Bajaj

INVOICE

10459

DATE

12/16/25

The information and recommendations provided are based on the images presented by the referring veterinarian/sonographer. No evaluation can be communicated regarding pathology that was not visible in the image/video clips provided.

Thank you for this referral. If the clinical or image interpretation does not parallel your findings or if I can be of any further assistance, please contact me.

R. McKenzie Daniel, DVM, DABVP (Canine/Feline Practice)
info@sonopath.com