



**PATIENT PRESENTING CLINICAL SIGNS**

Maizee McKibben

ADR, not wanting to eat vomiting a month ago, o called and we recommended to try chicken and rice, issue resolved p is more lethargic than usual has not wanted to eat in the past 2 days, ate this morning with some scrambled eggs mixed in

**SPECIES**

Canine

Abnormal PE/Chem/CBC/UA Results: Senior Screen Results: CBC Hct 32% (38-56) \*normocytic normochromic Retic 372 (10-110) NRBC 13 (0-2) anisocytosis polychromasia Chem Amyl 1597 (337-1469) Lip 378 (0-250) cPL 296 (0-200) Current Medications Mirtazepine

**BREED**

Boxer

**ULTRASONOGRAPHIC EXAMINATION OF THE ABDOMEN**

**Urinary System**

**SEX**

Spayed Female

The urinary bladder, trigone, cystourethral junction, and visible pelvic urethra to a depth of 3.0 cm exhibited normal thickness and tone. Anechoic urine was present in the lumen with no uroliths or sediment. The ureteral papillae were normal. The ureters were not visible which is normal. No evidence of inflammatory or neoplastic changes were noted.

**AGE**

10 Years

Multiple non-homogeneous cystic to cavitated mass lesions were present in the area of the iliac trifurcation, dorsal to the urinary bladder and potentially within the pelvic inlet. Example of mass lesion measured 5.7 cm x 4.0 cm and 6.0 cm x 5.6 cm.

**WEIGHT**

56 Pounds

Normal size and margination were present in the kidneys. A normal 1:3 cortex / medulla ratio was maintained. The medulla and cortices were uniform in texture with some increased echogenicity and loss of corticomedullary symmetry and definition expected for the age of the patient. No evidence of pelvic dilation was present. The left kidney measured 6.3 cm. The right kidney measured 6.8 cm.

**INTERPRETED BY**

R. McKenzie Daniel,  
DVM, DABVP  
(Canine and Feline)

**Adrenal Glands**

The adrenal glands were uniform in size and contour with a uniformly hypoechoic parenchyma. The left adrenal gland measured 2.4 cm length x 0.58 cm at the caudal pole. The right adrenal gland measured 3.4 cm length x 0.52 cm at the caudal pole.

**IMAGING PERFORMED BY**

Jenna Walsh, CVT

**Spleen**

The spleen exhibited primarily finely textured parenchyma which was hyperechoic to the liver and renal cortical parenchyma. Mild generalized parenchyma heterogeneity was present without evidence of nodular changes. The capsule was smooth and regular without apparent expansion. The splenic vasculature at the hilus was normal in volume with no evidence of congestion or thrombosis. The parenchymal heterogeneity is likely consistent with benign changes such as extramedullary hematopoiesis or age related remodeling with minor potential for inflammatory or neoplastic disease.

**HOSPITAL NAME**

Reid Vet Hospital

**REFERRING VET**

Dr. Heider

**Liver**

The liver was subjectively normal in size, structure, and contour. The liver parenchyma was mildly nonuniform and hypoechoic to the spleen with a moderate coarse echotexture and subjective mild to benign parenchymal remodeling. The hepatic and portal vasculature were normal in appearance without signs of congestion. The gallbladder was non-distended in size with thin walls and primarily anechoic luminal content. The cystic and common bile ducts were normal.

**INVOICE**

33485

**DATE**

12/16/21



## PATIENT

### *Gastrointestinal*

Maizee McKibben

The stomach presented intact wall layering with a normal wall layer ratio. The lumen of the stomach was empty with no signs of ileus, obstruction or foreign material. Gastric body wall measured 0.42 cm.

## SPECIES

Canine

The small intestine presented intact wall layering with 1:3 muscularis/mucosa ratio. The lumen of the small intestine was empty with no signs of ileus, obstruction or foreign material. Jejunum wall measured 0.38 cm.

## BREED

Boxer

Normal visible colon wall layers were present with apparent formed feces in lumen.

## SEX

Spayed Female

The parenchyma of the left limb, body and right limb of the pancreas presented isoechoic to the adjacent omental fat. A normal curvilinear capsule contour of the pancreas was present. The visible pancreatic duct was normal. No signs of active inflammation or neoplastic disease was evident.

## AGE

10 Years

### *Free Abdomen*

No evidence of peritoneal effusion.

## WEIGHT

56 Pounds

Brief sonographic assessment of the thorax revealed subjective moderate pleural effusion. Subjectively, the heart appeared to be overtly normal in structure and likely function without obvious evidence of left or right heart chamber enlargement. Definitive thoracic or pericardial masses were not obvious.

### **ULTRASONOGRAPHIC FINDINGS**

## INTERPRETED BY

R. McKenzie Daniel,  
DVM, DABVP  
(Canine and Feline)

- Multiple non-homogeneous cystic to cavitated masses adjacent to the iliac trifurcation and dorsal to the urinary bladder and potentially within the pelvic inlet.
- Sonographically unremarkable gastrointestinal tract
- Mild age related/benign hepatosplenic changes – no evidence of hepatosplenic neoplastic criteria.
- Non-cardiogenic pleural effusion

## IMAGING PERFORMED BY

Jenna Walsh, CVT

### **INTERPRETATION OF THE FINDINGS & FURTHER RECOMMENDATIONS**

## HOSPITAL NAME

Reid Vet Hospital

The multiple masses in the area of the iliac trifurcation dorsal to the urinary bladder and potentially in the pelvic inlet may indicate severe non-homogeneous medial iliac hypogastric to sublumbar lymphadenopathy, suggestive of primary versus metastatic neoplastic criteria. The possibility of unspecified neoplasia such as unspecified sarcoma or less likely neoplasia deriving from the uterine remnant cannot be definitively excluded. Assuming normal clotting status, ultrasound guided FNA of the mass lesions for screening cytology +/- culture and sensitivity (if clinically indicated) could be considered.

## REFERRING VET

Dr. Heider

## INVOICE

33485

Primary concern for potential multicentric bicavitary neoplastic process given the presence of non-cardiogenic pleural effusion. Further assessment of the pleural effusion via thoracocentesis for sample collection for analysis, cytospin cytology +/- culture and sensitivity recommended. Rectal palpation to assess for anal sac pathology is suggested if not already done.

## DATE

12/16/21



**PATIENT**

Maizee McKibben

**SPECIES**

Canine

**BREED**

Boxer

**SEX**

Spayed Female

**AGE**

10 Years

**WEIGHT**

56 Pounds

**INTERPRETED BY**

R. McKenzie Daniel,  
DVM, DABVP  
(Canine and Feline)

**IMAGING PERFORMED BY**

Jenna Walsh, CVT

**HOSPITAL NAME**

Reid Vet Hospital

**REFERRING VET**

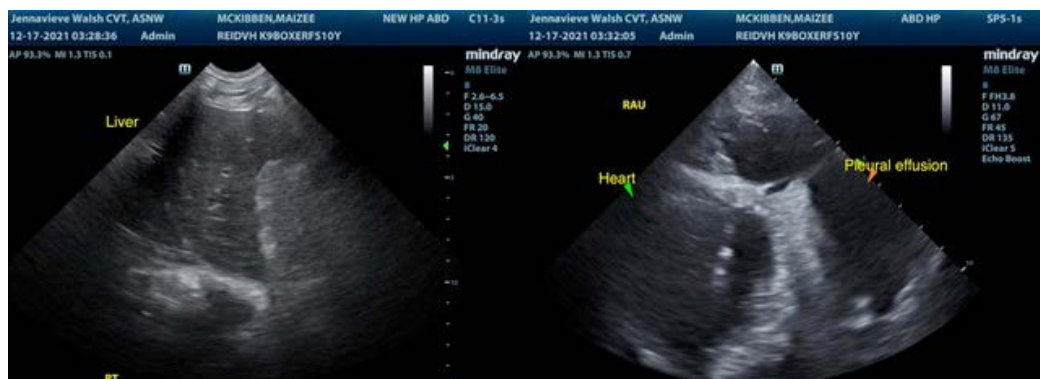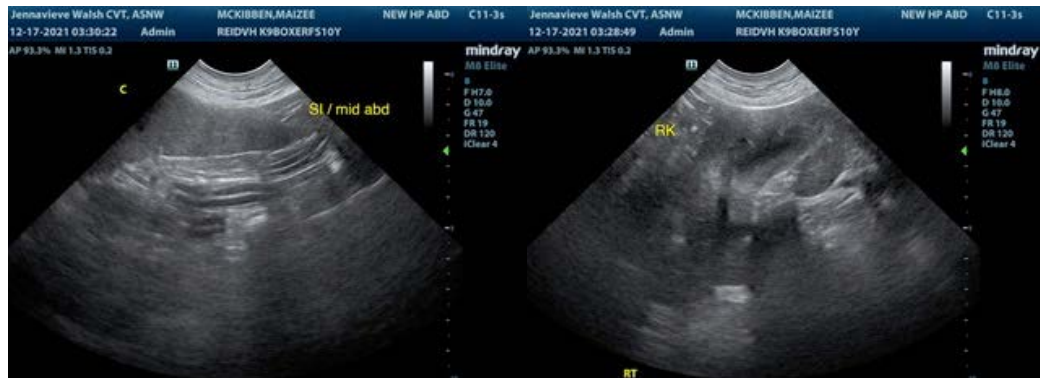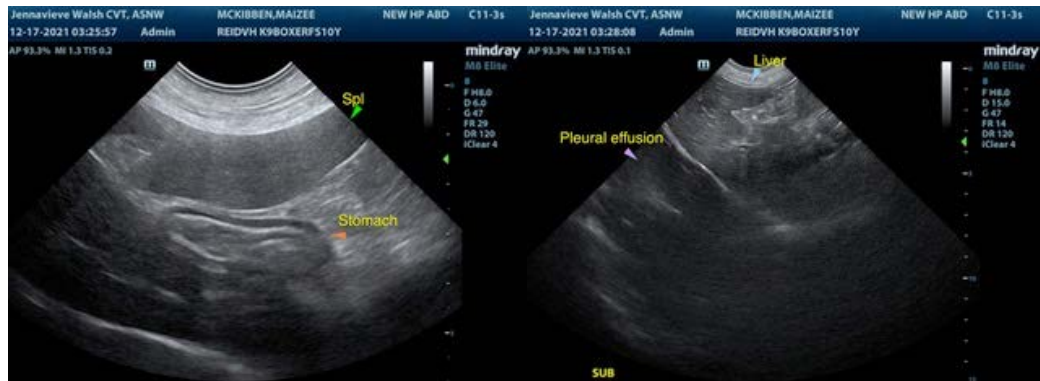
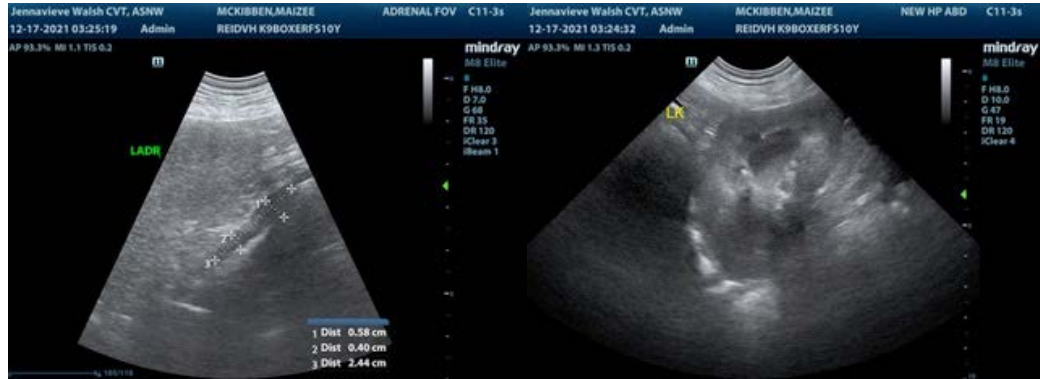Dr. Heider

**INVOICE**

33485

**DATE**

12/16/21





**PATIENT**

Maizee McKibben

**SPECIES**

Canine

**BREED**

Boxer

**SEX**

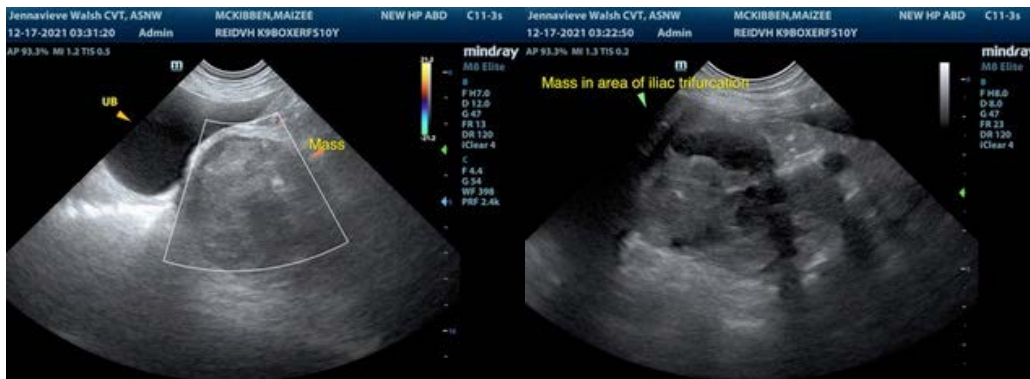Spayed Female

**AGE**

10 Years

**WEIGHT**

56 Pounds



The information and recommendations provided are based on the images presented by the referring veterinarian. No evaluation can be communicated regarding pathology that was not visible in the image/video clips provided.

Thank you for this referral. If the clinical or image interpretation does not parallel your findings or if I can be of any further assistance please contact me.

**R. McKenzie Daniel, DVM, DABVP (Canine / Feline Practice)**  
info@SonoPath.com

**INTERPRETED BY**

R. McKenzie Daniel,  
DVM, DABVP  
(Canine and Feline)

**IMAGING PERFORMED BY**

Jenna Walsh, CVT

**HOSPITAL NAME**

Reid Vet Hospital

**REFERRING VET**

Dr. Heider

**INVOICE**

33485

**DATE**

12/16/21