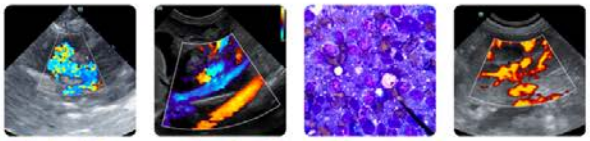

PATIENT
Buddy Degenova

SPECIES
Canine

BREED
Mix

SEX
Neutered Male

AGE
9

WEIGHT
24.5

INTERPRETED BY
R. McKenzie Daniel, DVM, DABVP (Canine and Feline)

IMAGING PERFORMED BY
Jenn

HOSPITAL NAME
Rockaway Animal Hospital

REFERRING VET
Dr. Maniar

INVOICE
72578

DATE
12/15/25

PRESENTING CLINICAL SIGNS

Rechecking splenic nodule Prev abd u/s 6/23/25 Owner reports no concerns.

ULTRASONOGRAPHIC EXAMINATION OF THE ABDOMEN

Urinary System

The urinary bladder, trigone, cystourethral junction, and visible pelvic urethra to a depth of 3.0 cm exhibited normal thickness and tone. Anechoic urine was present in the lumen with no uroliths or sediment. The ureteral papillae were normal. The ureters were not visible which is normal. No evidence of inflammatory or neoplastic changes were noted.

The residual prostate was symmetrically normal in size with uniform parenchyma and slight coarse echotexture.

Normal size and margination were present in the kidneys. A normal 1:3 cortex / medulla ratio and normal corticomedullary definition were maintained. The echogenicity of the cortex was similar to or slightly less than normal liver parenchyma while the medulla echogenicity was hypoechoic to the cortex with no evidence of pelvic dilation. The left kidney measured 4.6 cm in length. The right kidney measured 4.8 cm in length.

Adrenal Glands

The left adrenal gland was uniform in size and contour with a uniformly hypoechoic parenchyma. The left adrenal gland measured 0.53 cm at the caudal pole. The right adrenal gland was uniform in size and contour with a uniformly hypoechoic parenchyma. The right adrenal gland measured 0.58 cm at the caudal pole.

Spleen

The spleen was normal in size and contour with primarily homogeneous parenchyma. The previously noted mildly expansive yet non-capsule deforming, non-homogeneous mid to cranial splenic nodule measured 1.55 cm x 1.0 cm.

Liver

The liver was subjectively normal in size, structure, and contour. The liver parenchyma was uniform and hypoechoic to the spleen with a mild coarse echotexture. The hepatic and portal vasculature were normal in appearance without signs of congestion. The gallbladder was non distended in size with mild, non-organized debris. The cystic duct and common bile ducts were normal without evidence of dilation.

Gastrointestinal

The stomach presented intact wall layering with a normal wall layer ratio. The lumen of the stomach contained moderate, variably echogenic, nonshadowing ingesta most consistent with post prandial presentation without signs of ileus, obstruction or foreign material.

The small intestine presented intact wall layering with 1:3 muscularis/mucosa ratio. The lumen of the small intestine was empty with no signs of ileus, obstruction or foreign material.

Normal visible colon wall layers were present with apparent formed feces in lumen.

PATIENT

Buddy Degenova

SPECIES

Canine

BREED

Mix

SEX

Neutered Male

AGE

9

WEIGHT

24.5

INTERPRETED BY

R. McKenzie Daniel, DVM, DABVP (Canine and Feline)

IMAGING PERFORMED BY

Jenn

HOSPITAL NAME

Rockaway Animal Hospital

REFERRING VET

Dr. Maniar

INVOICE

72578

DATE

12/15/25

Pancreas

The parenchyma of the left limb, body and right limb of the pancreas presented isoechoic to the adjacent omental fat. A normal curvilinear capsule contour of the pancreas was present. The visible pancreatic duct was normal. No signs of active inflammation or neoplastic disease was evident.

Free Abdomen

No overt lymphadenopathy or peritoneal effusion was present.

ULTRASONOGRAPHIC FINDINGS

- Static splenic nodule.
- Non-organized gallbladder debris, non-mucocele.
- Gastric ingesta, consistent with food echogenicity.

INTERPRETATION OF THE FINDINGS & FURTHER RECOMMENDATIONS

The splenic nodule appears similar in size and presentation without evidence of capsule distortion compared to the previous study. Previously mentioned considerations are still applicable i.e., benign process such as lymphoid hyperplasia, hematopoiesis, granuloma or neoplasia such as sarcoma, round cell neoplasia, or other. Neoplastic splenic nodule is considered less likely, given no evidence of significant progression over previous recheck studies. Assuming normal clotting status and using 25-gauge FNA, splenic nodule FNA cytology could be considered for further clarification versus continued monitoring. Diagnostic and prophylactic splenectomy with histopathology likely required for definitive diagnosis.

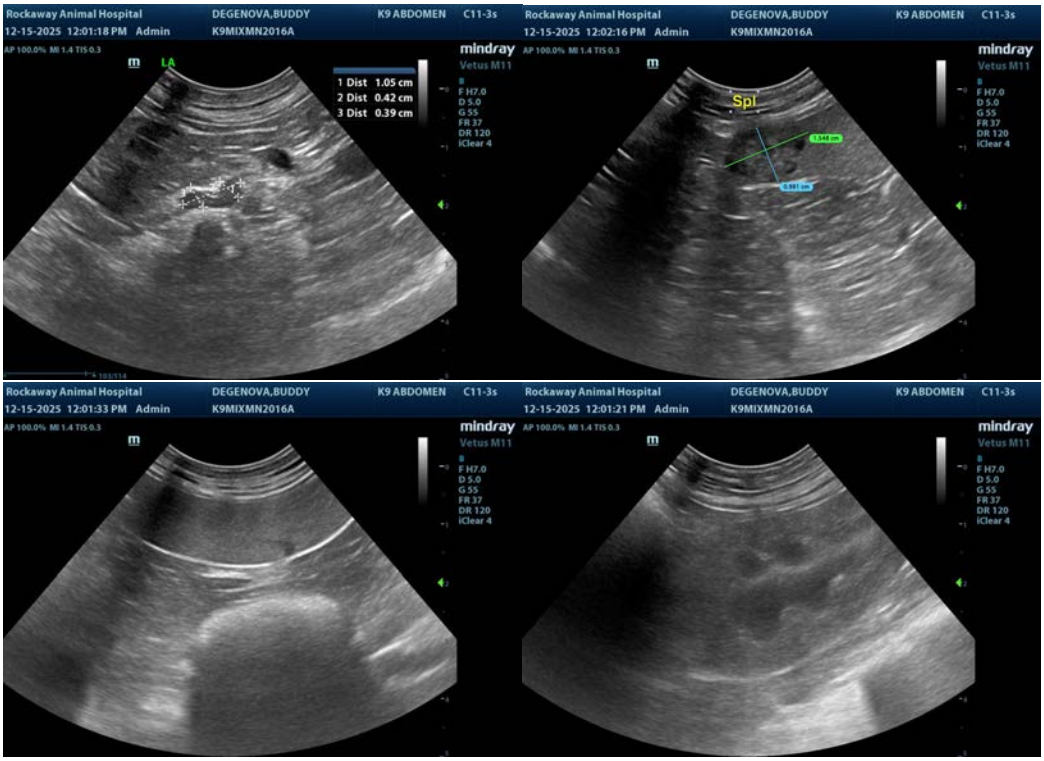

SonoPath

FOSTERING THE ART OF VETERINARY MEDICINE™



Clinical Sonography & Telecytology

Educational Teleconsultation Services™

SonoPath.com info@sonopath.com 1.800.838.4268

PATIENT

Buddy Degenova

SPECIES

Canine

BREED

Mix

SEX

Neutered Male

AGE

9

WEIGHT

24.5

INTERPRETED BY

R. McKenzie Daniel, DVM, DABVP (Canine and Feline)

IMAGING PERFORMED BY

Jenn

HOSPITAL NAME

Rockaway Animal Hospital

REFERRING VET

Dr. Maniar

INVOICE

72578

DATE

12/15/25

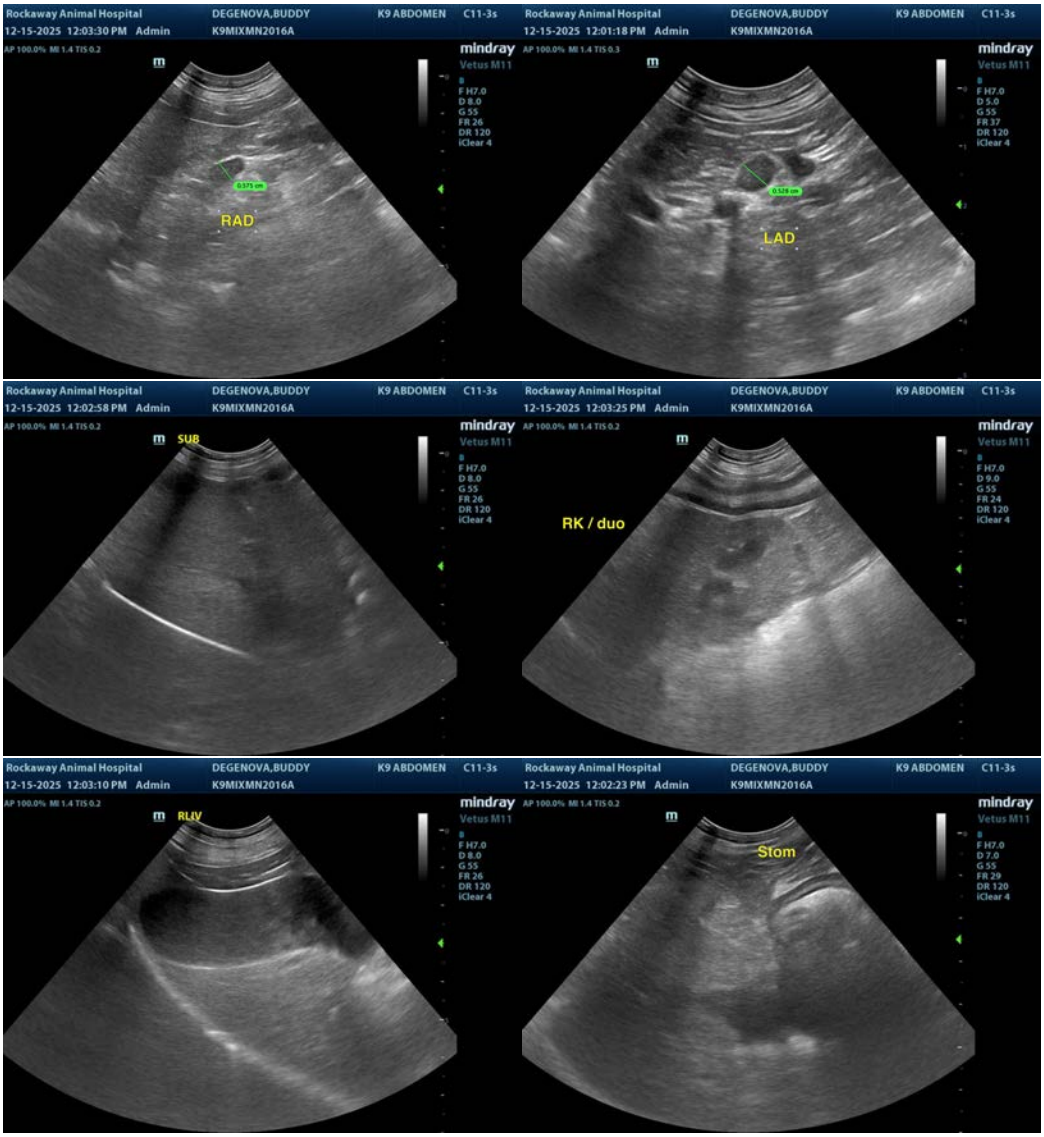

The information and recommendations provided are based on the images presented by the referring veterinarian/sonographer. No evaluation can be communicated regarding pathology that was not visible in the image/video clips provided.

Thank you for this referral. If the clinical or image interpretation does not parallel your findings or if I can be of any further assistance please contact me.

R. McKenzie Daniel, DVM, DABVP (Canine / Feline Practice)

info@SonoPath.com