



**PATIENT**

Rosie Brassard

**PRESENTING CLINICAL SIGNS**

History: Lethargic with pale mucus membranes. History of SharPei fever  
Abnormal PE/Chem/CBC/UA Results: Regenerative anemia chemistry normal

**SPECIES**

Canine

**ULTRASONOGRAPHIC EXAMINATION OF THE ABDOMEN**

**Urinary System**

**BREED**

Shar Pei X

The urinary bladder, trigone, cystourethral junction, and visible pelvic urethra to a depth of 3.0 cm exhibited normal thickness and tone. Mild asymmetrical luminal surface to micropolypoid changes were present likely associated with age related mural changes. Anechoic urine was present in the lumen with no uroliths or sediment. The ureteral papillae were normal. The ureters were not visible which is normal. No evidence of inflammatory or neoplastic changes were noted. Aortic trifurcation was normal.

**SEX**

Spayed Female

Normal size and margination were present in the kidneys. A normal 1:3 cortex / medulla ratio was maintained. The medulla and cortices were uniform in texture with some increased echogenicity and mild loss of corticomedullary symmetry and definition expected for the age of the patient. No evidence of pelvic dilation was present. The left kidney measured 6.6 cm in length. The right kidney measured 6.3 cm in length.

**AGE**

13

**Adrenal Glands**

**WEIGHT**

30 kg

The bilateral adrenal glands were normal in size. Mild parenchyma heterogeneity and mild capsule asymmetry was present without suspicion for overt neoplasia. The left adrenal gland measured 0.50 cm width in the caudal pole. The right adrenal gland measured 0.84 cm at the cranial pole and 0.78 cm in the caudal pole.

**INTERPRETED BY**

R. McKenzie Daniel,  
DVM, DABVP  
(Canine and Feline)

**Spleen**

A moderately sized to large mass involving the spleen with secondary asymmetrical capsule expansion and disruption was present. The parenchyma of the mass was mixed echogenic to cavitated, involving the majority to mid caudal spleen. The subjective larger splenic mass mid to caudal spleen measured potentially 9-10 cm in diameter. Potential for separate to coalescing mass in the cranial spleen was noted, measured 6-7 cm in diameter. Regional perisplenic hyperechoic mesentery was noted. Scant to mild volume peritoneal free fluid was noted. The splenic vasculature at the hilus was normal in volume with no evidence of congestion or thrombosis. around the mass.

**IMAGING PERFORMED BY**

Dr. Belan

**HOSPITAL NAME**

Signal Hill AC

**Liver**

The liver was subjectively normal in size, structure, and contour. The liver parenchyma was uniform and hypoechoic to the spleen with a mild coarse echotexture. The hepatic and portal vasculature were normal in appearance without signs of congestion.

**REFERRING VET**

Dr. Cumyn

The gallbladder was non-distended in size with thin walls and primarily anechoic luminal content. The cystic and common bile ducts were normal.

**INVOICE**

20107

**Gastrointestinal**

The stomach presented intact wall layering with a normal wall layer ratio. The lumen of the stomach was empty with no signs of ileus, obstruction or foreign material.

**DATE**

12/15/22



**PATIENT**

Rosie Brassard

The small intestine presented intact wall layering with 1:3 muscularis/mucosa ratio. The lumen of the small intestine was empty with no signs of ileus, obstruction or foreign material.

Normal visible colon wall layers were present with apparent formed feces in lumen.

**SPECIES**

Canine

***Pancreas***

The pancreas was normal in size and contour with isoechoic to heterogeneous parenchyma compared to adjacent omentum. No signs of active inflammation or neoplasia. This is consistent with age-related pancreatic changes and incidental.

**BREED**

Shar Pei X

***Free Abdomen***

No overt lymphadenopathy.

**SEX**

Spayed Female

***Other***

A rapid view of the heart revealed no overt evidence of pericardial effusion or primary versus metastatic neoplastic criteria in the visible window. Overtly normal left and right chamber sizes and normal LV systolic function noted.

**AGE**

13

**ULTRASONOGRAPHIC FINDINGS**

- Large asymmetrical mixed echogenic cavitated, potentially coalescing splenic mass/masses
- Hepatic parenchymal remodeling- subjectively benign
- Mild chronic renal changes
- Associated perisplenic hyperechoic mesentery, potential for adhesions
- Scant to mild volume peritoneal free fluid

**WEIGHT**

30 kg

**INTERPRETED BY**

R. McKenzie Daniel,  
DVM, DABVP  
(Canine and Feline)

**INTERPRETATION OF THE FINDINGS & FURTHER RECOMMENDATIONS**

Although histopathology is required for definitive diagnosis, the splenic mass is most suggestive of neoplasia such as sarcoma or other. Benign pathologies are possible yet considered less likely.

**IMAGING PERFORMED BY**

Dr. Belan

No overt evidence of intraabdominal or pericardial metastasis, although the possibility of omental adhesions, potential early regional perisplenic omental seeding or non-sonographically detectable metastasis in these case cannot be definitively excluded. Assuming no evidence of pathology on three view chest radiographs, splenectomy with gross inspection of the perisplenic omentum and liver could be considered. Guarded to possible very guarded long term prognosis pending splenic histopathology.

**HOSPITAL NAME**

Signal Hill AC

**REFERRING VET**

Dr. Cumyn

**INVOICE**

20107

**DATE**

12/15/22



**PATIENT**

Rosie Brassard

**SPECIES**

Canine

**BREED**

Shar Pei X

**SEX**

Spayed Female

**AGE**

13

**WEIGHT**

30 kg

**INTERPRETED BY**

R. McKenzie Daniel,  
DVM, DABVP  
(Canine and Feline)

**IMAGING PERFORMED BY**

Dr. Belan

**HOSPITAL NAME**

Signal Hill AC

**REFERRING VET**

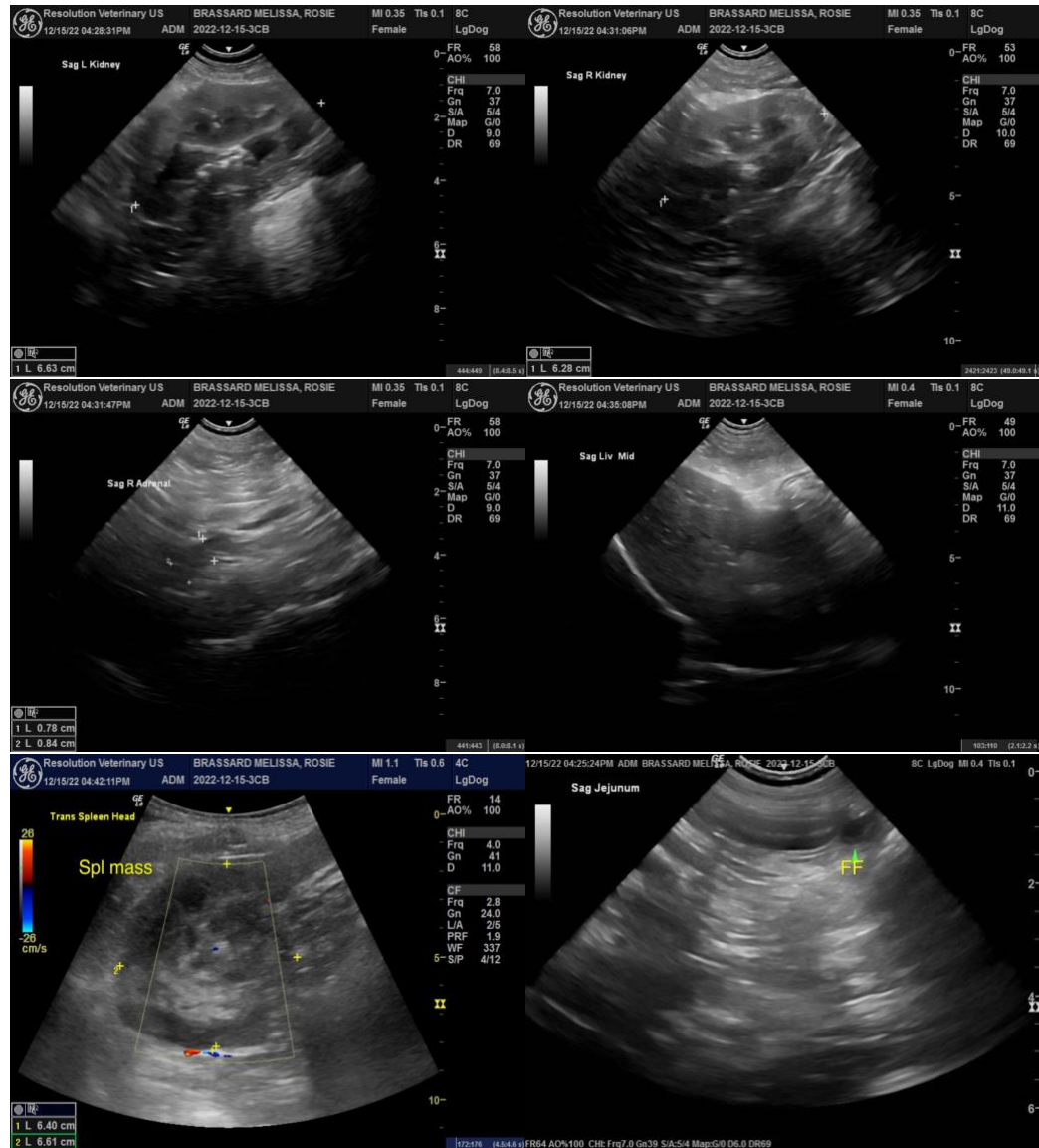
Dr. Cumyn

**INVOICE**

20107

**DATE**

12/15/22





**PATIENT**

Rosie Brassard

**SPECIES**

Canine

**BREED**

Shar Pei X

**SEX**

Spayed Female

**AGE**

13

**WEIGHT**

30 kg

**INTERPRETED BY**

R. McKenzie Daniel,  
DVM, DABVP  
(Canine and Feline)

**IMAGING PERFORMED BY**

Dr. Belan

**HOSPITAL NAME**

Signal Hill AC

**REFERRING VET**

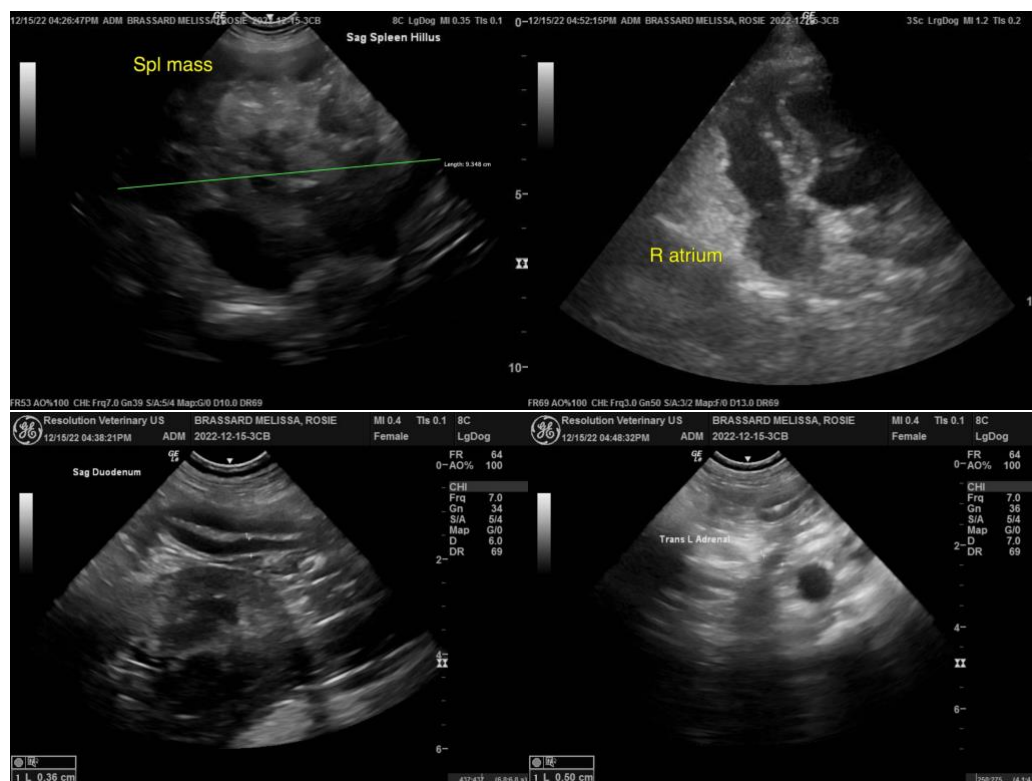
Dr. Cumyn

**INVOICE**

20107

**DATE**

12/15/22



The information and recommendations provided are based on the images presented by the referring veterinarian. No evaluation can be communicated regarding pathology that was not visible in the image/video clips provided.

Thank you for this referral. If the clinical or image interpretation does not parallel your findings or if I can be of any further assistance please contact me.

**R. McKenzie Daniel, DVM, DABVP (Canine / Feline Practice)**  
info@SonoPath.com