



PATIENT PRESENTING CLINICAL SIGNS

Sabbath Greenwood Had 2 PU surgeries in past two years, now has blood in urine again.

SPECIES ULTRASONOGRAPHIC EXAMINATION OF THE ABDOMEN

Feline Urinary System

The urinary bladder was mildly subnormal in size owing to lack of urine distention. Generalized mild uniform urinary bladder mural thickening was present without evidence of mural mineralization. Ventral urinary bladder wall measured 0.48 cm in width. A solitary calculus to accumulated small calculi were present in the dependent lumen along with mild non-dependent, potentially congealed particulate sediment, which may indicate concurrent cellular or crystalline debris. The area of urinary bladder mineral measured approximately 1.4 cm in diameter. No overt evidence of neoplastic criteria. Subtle evidence of regional inflammation around the urinary bladder was present. The proximal urethra exhibited normal subjective tone and structure to a depth of 2.0 cm, measuring 0.37 cm in width.

BREED

DLH

SEX

Neutered Male

The area of the aortic trifurcation was free of pathology.

AGE

5 Years

Normal size and margination were present in the kidneys. A normal 1:3 cortex / medulla ratio and normal corticomedullary definition were maintained. The echogenicity of the cortex was similar to or slightly less than normal liver parenchyma while the medulla echogenicity was hypoechoic to the cortex with no evidence of pelvic dilation. No retroperitoneal inflammation. The left kidney measured 3.9 cm. The right kidney measured 4.1 cm.

WEIGHT

15 Pounds

Adrenal Glands

The adrenal glands were uniform in size and contour with a uniformly hypoechoic parenchyma. The right adrenal gland measured 0.47 cm in width. The left adrenal gland measured 0.32 cm in width.

INTERPRETED BY

R. McKenzie Daniel, DVM,
DABVP (Canine and
Feline)

Spleen

The spleen exhibited a finely textured and homogenous parenchyma which was hyperechoic to the liver and renal cortical parenchyma. The capsule was smooth and regular without apparent expansion. The splenic vasculature at the hilus was normal in volume with no evidence of congestion or thrombosis. Acute to chronic inflammatory, neoplastic, or benign parenchyma changes were not noted.

IMAGING PERFORMED BY

Kelly Reschny

Liver

The liver was subjectively normal in size, structure, and contour. The liver parenchyma was uniform and hypoechoic to the spleen with a mild coarse echotexture. The hepatic and portal vasculature were normal in appearance without signs of congestion. The gallbladder was non-distended in size with thin walls and primarily anechoic luminal content. The cystic and common bile ducts were normal.

HOSPITAL NAME

Beech Mobile Services

REFERRING VET

Dr. Beech

Gastrointestinal

The stomach presented intact wall layering with a normal wall layer ratio. The lumen of the stomach was empty with no signs of ileus, obstruction or foreign material.

INVOICE

33452

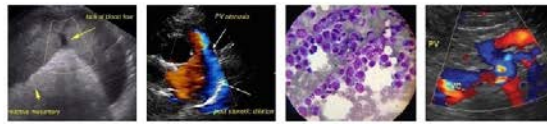
The small intestine presented intact wall layering with 1:3 muscularis/mucosa ratio. The lumen of the small intestine was empty with no signs of ileus, obstruction or foreign material.

DATE

12/15/21

Normal visible colon wall layers were present with apparent formed feces in lumen.

Pancreas



PATIENT

Sabbath Greenwood

The parenchyma of the left limb, body and right limb of the pancreas presented isoechoic to the adjacent omental fat. A normal curvilinear capsule contour of the pancreas was present. The visible pancreatic duct was normal. No signs of active inflammation or neoplastic disease was evident.

SPECIES

Feline

ULTRASONOGRAPHIC FINDINGS

- Cystic calculus to accumulated small calculi with concurrent particulate urinary bladder sediment, probable generalized chronic cystitis.
- Sonographically unremarkable bilateral kidneys, no evidence of pyelectasia.

BREED

DLH

INTERPRETATION OF THE FINDINGS & FURTHER RECOMMENDATIONS

SEX

Neutered Male

The cystitis pattern exhibited by the urinary bladder may be chronic in nature given the patient's history, or secondary to the urinary bladder mineral. Given the presence of mineral and current hematuria, cystotomy with urinary bladder flush, urine culture and sensitivity on sterile urine sample +/- mural biopsies for histopathology and tissue culture and sensitivity is warranted. Conservatively, medical therapy for feline idiopathic cystitis +/- underlying infection (if clinically indicated) would be appropriate. If conservative therapy is elected, sonographic monitoring of the urinary bladder for progressive inflammatory changes or mineral accumulation recommended.

AGE

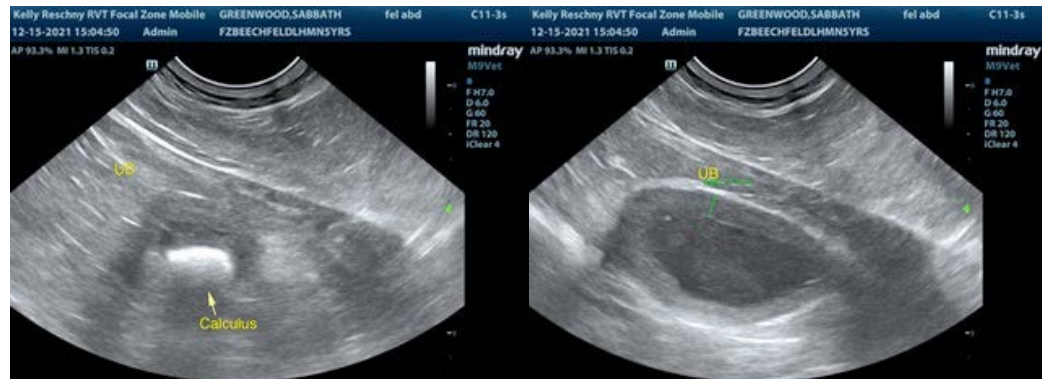
5 Years

WEIGHT

15 Pounds

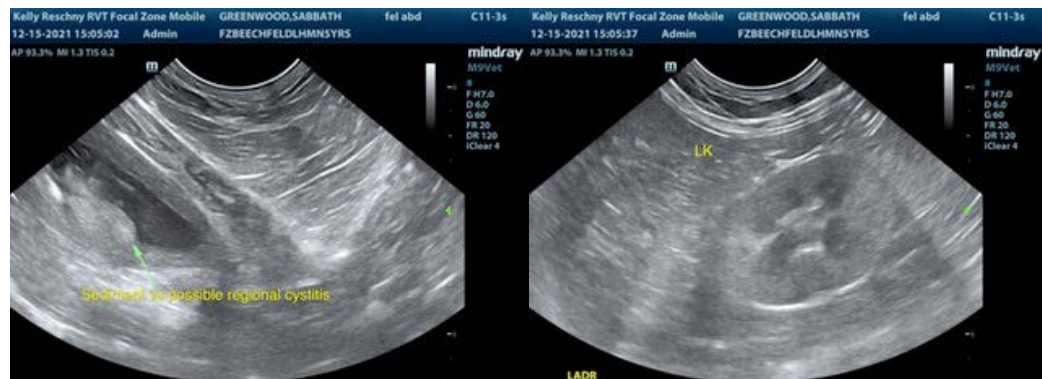
INTERPRETED BY

R. McKenzie Daniel, DVM,
DABVP (Canine and Feline)



IMAGING PERFORMED BY

Kelly Reschny



HOSPITAL NAME

Beech Mobile Services

REFERRING VET

Dr. Beech

INVOICE

33452

DATE

12/15/21



PATIENT

Sabbath Greenwood

SPECIES

Feline

BREED

DLH

SEX

Neutered Male

AGE

5 Years

WEIGHT

15 Pounds

INTERPRETED BY

R. McKenzie Daniel, DVM,
DABVP (Canine and
Feline)

**IMAGING
PERFORMED BY**

Kelly Reschny

HOSPITAL NAME

Beech Mobile Services

REFERRING VET

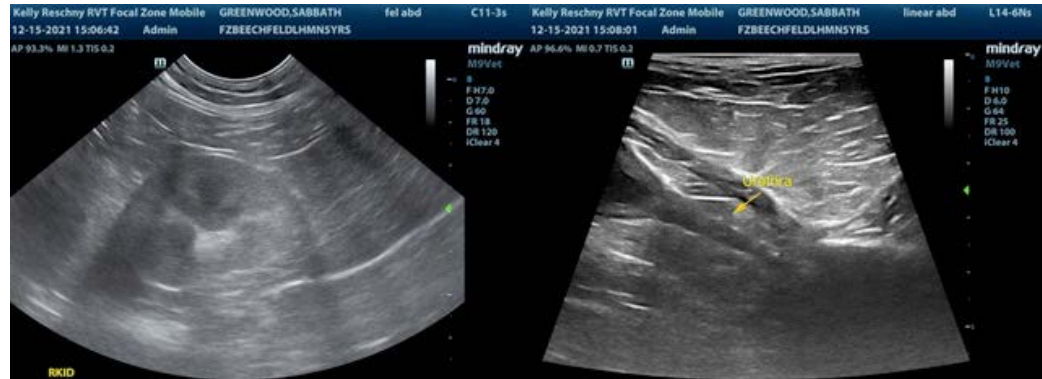Dr. Beech

INVOICE

33452

DATE

12/15/21



The information and recommendations provided are based on the images presented by the referring veterinarian. No evaluation can be communicated regarding pathology that was not visible in the image/video clips provided.

Thank you for this referral. If the clinical or image interpretation does not parallel your findings or if I can be of any further assistance please contact me.

R. McKenzie Daniel, DVM, DABVP (Canine / Feline Practice)
info@SonoPath.com



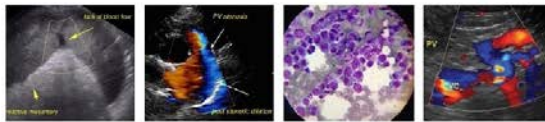
The following is an applicable excerpt from the *Curbside Guide to Diagnosis & Treatment of Sonographic Disease* offered by SonoPath.com Lindquist, Frank, Lobetti, and Modler.

An essential quick guide for every general practitioner and sonographer.

<https://sonopath.com/products/curbside-guide-editing-due-release-12012015>

Feline Idiopathic Cystitis

<http://www.sonopath.com/FelineCystitis>



PATIENT

Sabbath Greenwood

SPECIES

Feline

BREED

DLH

SEX

Neutered Male

AGE

5 Years

WEIGHT

15 Pounds

INTERPRETED BY

R. McKenzie Daniel, DVM,
DABVP (Canine and
Feline)

**IMAGING
PERFORMED BY**

Kelly Reschny

HOSPITAL NAME

Beech Mobile Services

REFERRING VET

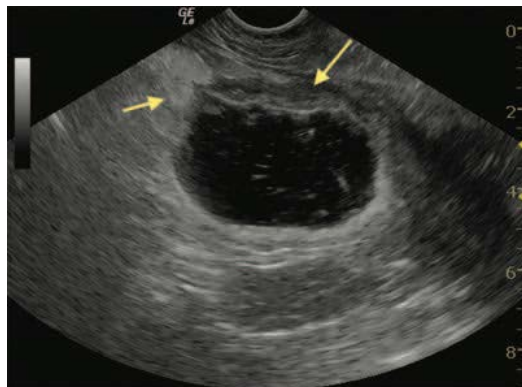Dr. Beech

INVOICE

33452

DATE

12/15/21



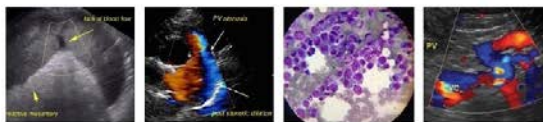
Short axis of the urinary bladder in a cat with chronic cystitis. Note the severe thickening and undulating surface of the bladder wall. The regular layers of the urinary bladder wall cannot be discerned (large arrow). There is a moderate amount of echogenic debris seen within the anechoic urine. Mild focal peritonitis is seen as echogenic perivesical fat (small arrow) consistent with adhesion formation stimulated by transmural pathology.

Description: Feline idiopathic cystitis (FIC) is defined as recurrent stranguria and hematuria in cats in the absence of an underlying cause. It is considered to be an exclusionary diagnosis once radiographs, ultrasound, coagulation profile, and aerobic urine culture by cystocentesis have eliminated the possibilities of urinary tract infection, urolithiasis, coagulopathies, and neoplasia. Clinical signs may resolve spontaneously within 3-7 days, with 30-50% recurrence within a year. Cats most frequently acquire the disease between the ages of 2 and 6, and although any breed is susceptible, Persian cats are overrepresented among those affected. Overweight spayed females and neutered males in a multi-cat household are at higher risk than their lean, solitary, or intact counterparts. Indoor, sedentary, dry-food eaters are at higher risk than outdoor cats that eat *ad libitum*. Psychosomatic influences—change of residence, new household members, pet additions, change of household objects—on the urinary bladder have been shown to play an important role in the pathophysiology of the disease. Neurogenic inflammation, decreased glycosaminoglycan concentration, and increased bladder permeability are tissue alterations found on histopathological review of affected bladders. Neurotransmitter P is increased in affected tissue and may be specifically targeted in eventual courses of treatment.

Clinical Signs: In the absence of an underlying urinary tract infection or evidence of neoplasia, FIC may present in an acute or chronic form with the following intermittent lower urinary tract symptoms: inappropriate urination (> 6 times/week in 70% of cases); stranguria (70%); hematuria (50%); and pollakiuria (80%).

Diagnostics: Since FIC is a diagnosis of exclusion, abdominal radiographs, abdominal ultrasound, blood pressure, coagulation profile, and urine culture are all required to rule out other differentials. Biopsy of the bladder wall can be useful to evaluate for lymphocytic plasmacytic inflammation, which can occur in some cases. Taking a history and having a thorough conversation about the cat's environmental stressors are imperative.

Treatment: Given that no specific cause has been cited and that FIC is considered a multifactorial disease, multimodal therapy is recommended. To date, no specific therapeutic has been effective in treating FIC. Palliation with pain management can be achieved with buprenorphine (0.02 mg/kg PO, IM, or IV BID-TID for 3-4 days). Practitioners have attempted the following with varying results: the introduction of a strict canned food diet; a change of feeding location in multi-cat households; and stimulating increased water intake using tuna or clam juice additives or circulating water fountains. To date, the most scientifically valid evidence points to the need for reducing urine concentration, which is achieved with canned food diets. In multiple studies, the simple act of switching to a canned therapeutic diet has been shown to reduce the risk of recurrence significantly. One study showed that only 11% of cats on a canned diet exhibited recurrent signs after a year, while those on a dry food diet displayed a 40% recurrence rate. Urine concentration can be reduced further by adding additional water into servings of canned food. Reduction of stress may be achieved by increasing litter box hygiene, placing the litter box in a quieter



PATIENT

Sabbath Greenwood

SPECIES

Feline

BREED

DLH

SEX

Neutered Male

AGE

5 Years

WEIGHT

15 Pounds

INTERPRETED BY

R. McKenzie Daniel, DVM,
DABVP (Canine and
Feline)

**IMAGING
PERFORMED BY**

Kelly Reschny

HOSPITAL NAME

Beech Mobile Services

REFERRING VET

Dr. Beech

INVOICE

33452

DATE

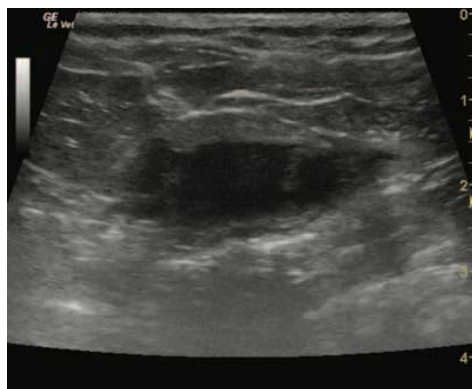12/15/21

environment, and providing separate food, water, and litter areas for the affected patient in a multi-cat household. It has been suggested that Feliway, the feline facial pheromone, can be used as a calming agent for cats when they are in unfamiliar surroundings. Feliway mimics the natural facial hormone released when a cat marks his or her territory by face rubbing. For unresponsive or severe cases, amitriptyline (10 mg PO Q24hr at bedtime) has been shown to have visceral analgesic, anticholinergic, mucosal mast cell inhibition, and anti-noradrenergic properties. Amitriptyline is considered standard therapy, but is only pursued once the preceding husbandry and feeding practices have proven to be ineffective. Amitriptyline should be used with caution in patients with cardiac disease or arrhythmias, and if instituted, should be used long-term. Studies indicate that short-term use of amitriptyline can result in faster recurrences. Note: Urine retention may occur while therapy is being administered. Biochemical panels should be monitored while a patient is undergoing amitriptyline therapy as liver enzyme elevation can occur. Glycosaminoglycan supplementation (pentosan polysulphate 2-10 mg/kg PO BID) has shown modest success (10-20%) in human trials for idiopathic cystitis. If used, a powder form is recommended to avoid the stress of pill administration (feline Cosequin capsules contain a powder that can be sprinkled onto food). Antiviral agents have not been shown to be effective, and even though researchers have suggested that the concurrent presence of *Calicivirus* may play a role and virus-like particles have been identified in urethral plugs and urine, no adequate evidence of a viral etiology has yet been demonstrated. A double-blind placebo trial suggested that glucocorticoids had no clinical benefits in 12 cases. All cases were self-limiting, in spite of whether the subjects were medicated with corticosteroids or not.

If hematuria seems persistent despite therapy and does not follow a typical FIC pattern (i.e., resolving within one week but recurring within a few weeks), cystoscopy or surgical evaluation may be indicated. Biopsies can be obtained, which allows for histopathology and bladder wall culture.

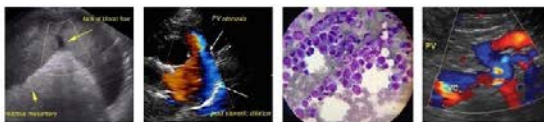
Environmental enrichment is also important to reduce stress. Providing vertical climbing surfaces, such as cat trees, increasing the number of litter boxes on different floors of the house (the rule of thumb is the number of litter boxes per house should equal the number of cats plus one), and increasing owner attention time, scheduled playtime, as well as supervised outdoor activity can decrease stress for cats.

Conclusion: Effective treatment of FIC involves a multi-modal approach with a strong emphasis on husbandry. Pet owners should focus on the fastidious upkeep of litter boxes and feed their cats canned food to both increase dietary water intake and maintain their cat's lean body weight. Stress management is also key and can be facilitated with environmental enrichment as well as an understanding of feline behavior.



Long axis view of 5-year-old FS feline bladder suffering from clinical signs of hematuria, inappropriate urination and straining. The ventral bladder wall is segmentally thickened. Feline interstitial cystitis is highly variable in presentation and can change sonographically from day to day. This enigma of a disease necessitates further investigation but sonographically, transmural erosion should be monitored as necrosis and perforation can occur.

References:



PATIENT

Sabbath Greenwood

Buffington CA, Westropp JL, et al. Clinical evaluation of multimodal environmental modification (MEMO) in the management of cats with idiopathic cystitis. *J Feline Med Surg* 2006;8:261-68.

SPECIES

Feline

Chew DJ, Buffington CA, Kendall MS, et al. Amitriptyline treatment for severe recurrent idiopathic cystitis in cats. *J Am Vet Med Assoc* 1998;213(9):1282-86.

BREED

DLH

Defauw PAM, Van de Maele I, et al. Risk factors and clinical presentation of cats with feline idiopathic cystitis. *J Feline Med Surg* 2011;13(12):967-75.

SEX

Neutered Male

Kraijer M, Fink-Gremmels J, Nickel RF. The short-term efficacy of amitriptyline in the management of idiopathic feline lower urinary tract disease: a controlled clinical study. *J Feline Med Surg* 2003;5(3):191-96.

AGE

5 Years

Kruger JM, Conway TS, Kaneene JB, et al. Randomized controlled trial of the efficacy of short-term amitriptyline administration for treatment of acute, nonobstructive, idiopathic lower urinary tract disease in cats. *J Am Vet Med Assoc* 2003;222(6):749-58.

WEIGHT

15 Pounds

Westropp JL, Kass PH, Buffington CA. Evaluation of the effects of stress in cats with idiopathic cystitis. *Am J Vet Res* 2006;67:731-36.

INTERPRETED BY

R. McKenzie Daniel, DVM,
DABVP (Canine and
Feline)

**IMAGING
PERFORMED BY**

Kelly Reschny

HOSPITAL NAME

Beech Mobile Services

REFERRING VET

Dr. Beech

INVOICE

33452

DATE

12/15/21