



PATIENT PRESENTING CLINICAL SIGNS

PATIENT Piper Yard
History: Vomiting began last night. Presented for referral hosp for supportive care at 1am. Presented here today for an ultrasound and consult. O reports she did get into the trash monday (tampons) and vomited some on tuesday.

SPECIES

Canine

Abnormal PE/Chem/CBC/UA Results: Pending

BREED

Lab

ULTRASONOGRAPHIC EXAMINATION OF THE ABDOMEN

Urinary System

SEX

Spayed Female

The urinary bladder, trigone, cystourethral junction, and visible pelvic urethra to a depth of 3.0 cm exhibited normal thickness and tone. Anechoic urine was present in the lumen with no uroliths or sediment. The ureteral papillae were normal. The ureters were not visible which is normal. No evidence of inflammatory or neoplastic changes were noted. Aortic trifurcation was normal.

AGE

4 Years

Normal size and margination were present in the kidneys. A normal 1:3 cortex / medulla ratio and normal corticomedullary definition were maintained. The echogenicity of the cortex was similar to or slightly less than normal liver parenchyma while the medulla echogenicity was hypoechoic to the cortex with no evidence of pelvic dilation. The left kidney measured 6.4 cm in length. The right kidney measured 6.6 cm in length.

WEIGHT

84 Pounds

Adrenal Glands

The left adrenal gland was uniform in size and contour with a uniformly hypoechoic parenchyma. The left adrenal gland measured 0.37 cm width at the caudal pole and 0.45 cm width at the cranial pole.

INTERPRETED BY

R. McKenzie Daniel,
DVM, DABVP
(Canine and Feline)

The right adrenal gland was uniform in size and contour with a uniformly hypoechoic parenchyma. The right adrenal gland measured 0.57 cm width at the caudal pole and 0.65 cm width at the cranial pole.

IMAGING PERFORMED BY

A. Rodriguez

Spleen

The spleen exhibited a finely textured and homogenous parenchyma which was hyperechoic to the liver and renal cortical parenchyma. The capsule was smooth and regular without apparent expansion. The splenic vasculature at the hilus was normal in volume with no evidence of congestion or thrombosis. Acute to chronic inflammatory, neoplastic, or benign parenchyma changes were not noted.

HOSPITAL NAME

Foxfield VS

Liver

The liver was subjectively normal in size, structure, and contour. The liver parenchyma was uniform and hypoechoic to the spleen with a mild coarse echotexture. The hepatic and portal vasculature were normal in appearance without signs of congestion.

REFERRING VET

A. Rodriguez

The gallbladder was non-distended in size with thin walls and primarily anechoic luminal content. The cystic and common bile ducts were normal.

INVOICE

20074

Gastrointestinal

The stomach presented intact wall layering with a normal wall layer ratio. The lumen of the stomach contained mild to moderate retained echogenic fluid, along with strongly shadowing luminal echo, appearing to extend into the area of the pyloric outflow.

DATE

12/14/22



PATIENT

Piper Yard

The small intestine presented intact sonographically unremarkable wall layering with segmental intestinal plication with concurrent segmental obstructive pattern. Within the areas of plicated small intestine, a hyperechoic linear echo was present, potentially involving the duodenum and/or segmental jejunum. Possible, although not definitive, intussusception noted focally within the plicated intestinal segment.

SPECIES

Canine

Normal visible colon wall layers were present with apparent formed feces in lumen.

BREED

Lab

Pancreas

The parenchyma of the left limb, body and right limb of the pancreas presented isoechoic to the adjacent omental fat. A normal curvilinear capsule contour of the pancreas was present. The visible pancreatic duct was normal. No signs of active inflammation or neoplastic disease was evident.

SEX

Spayed Female

Free Abdomen

Subtle evidence of periintestinal mild hyperechoic mesentery was noted. No evidence of peritoneal free fluid or evidence to suggest intestinal perforation. No overt or significant lymphadenopathy, although minor subjective benign or reactive periintestinal mesenteric lymphadenopathy is suspected.

AGE

4 Years

ULTRASONOGRAPHIC FINDINGS

WEIGHT

84 Pounds

Primary Findings

- Gastric foreign body, suspected anchored with concurrent segmental small intestinal linear foreign body with secondary segmental intestinal plication, segmental obstructive pattern, potential for focal intussusception

INTERPRETED BY

R. McKenzie Daniel,
DVM, DABVP
(Canine and Feline)

Secondary Findings

- Subjective borderline subnormal left to bilateral adrenal glands- nonspecific

IMAGING PERFORMED BY

A. Rodriguez

INTERPRETATION OF THE FINDINGS & FURTHER RECOMMENDATIONS

Exploratory laparotomy with expectation toward gastrotomy, as well as enterotomy to possible enterotomies are recommended. Subjectively, the intestinal walls appeared to be overtly normal without evidence of significant inflammatory criteria, yet gross inspection of the intestine at the time of surgery is recommended. The possibility of potential resection anastomosis cannot be definitively excluded.

HOSPITAL NAME

Foxfield VS

The borderline to subnormal left to bilateral adrenal glands is suspected to be a patient variant yet resting cortisol level may be considered if clinically indicated.

REFERRING VET

A. Rodriguez

INVOICE

20074

DATE

12/14/22



PATIENT

Piper Yard

SPECIES

Canine

BREED

Lab

SEX

Spayed Female

AGE

4 Years

WEIGHT

84 Pounds

INTERPRETED BY

R. McKenzie Daniel,
DVM, DABVP
(Canine and Feline)

IMAGING PERFORMED BY

A. Rodriguez

HOSPITAL NAME

Foxfield VS

REFERRING VET

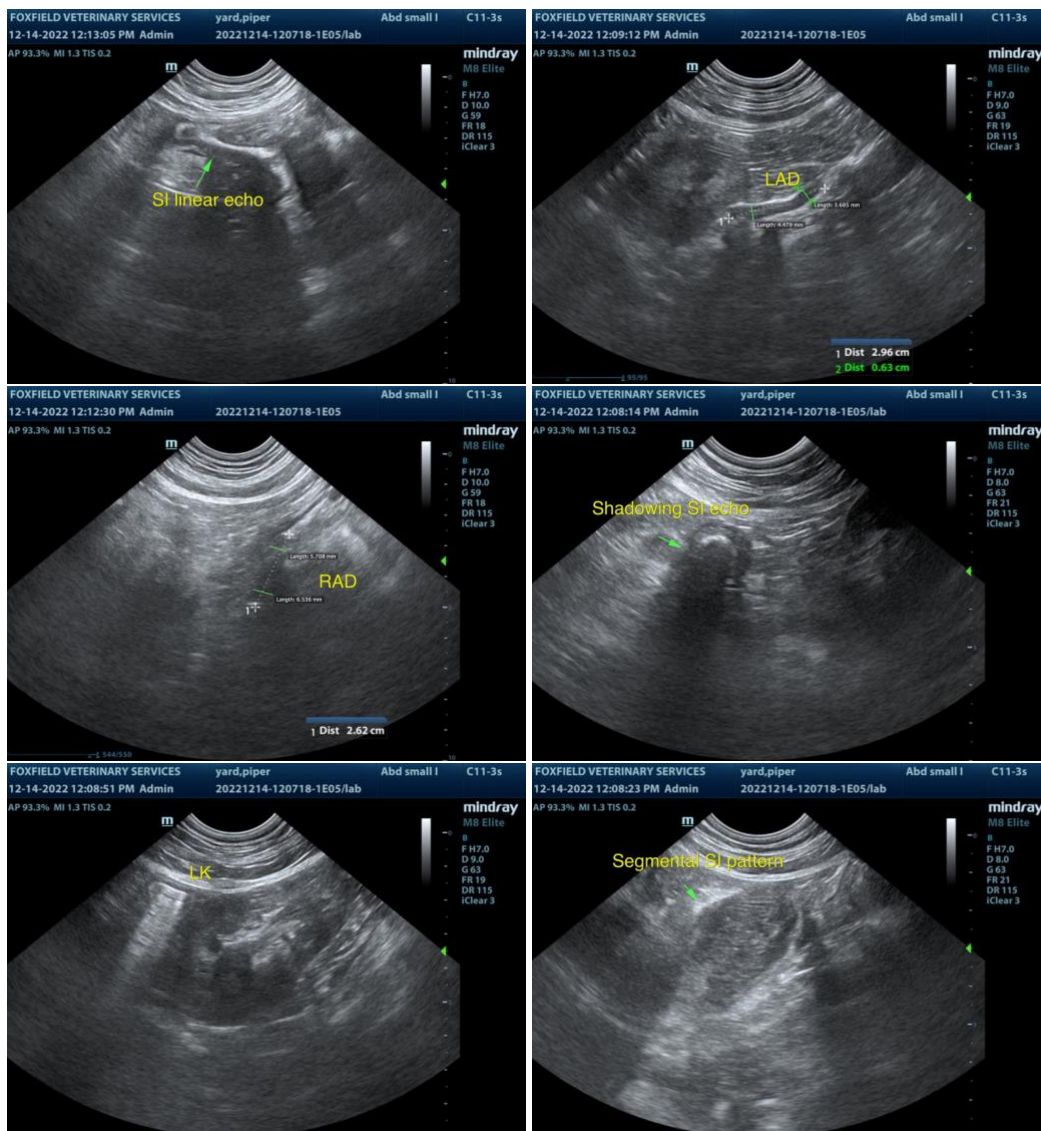
A. Rodriguez

INVOICE

20074

DATE

12/14/22





PATIENT

Piper Yard

SPECIES

Canine

BREED

Lab

SEX

Spayed Female

AGE

4 Years

WEIGHT

84 Pounds

INTERPRETED BY

R. McKenzie Daniel,
DVM, DABVP
(Canine and Feline)

IMAGING PERFORMED BY

A. Rodriguez

HOSPITAL NAME

Foxfield VS

REFERRING VET

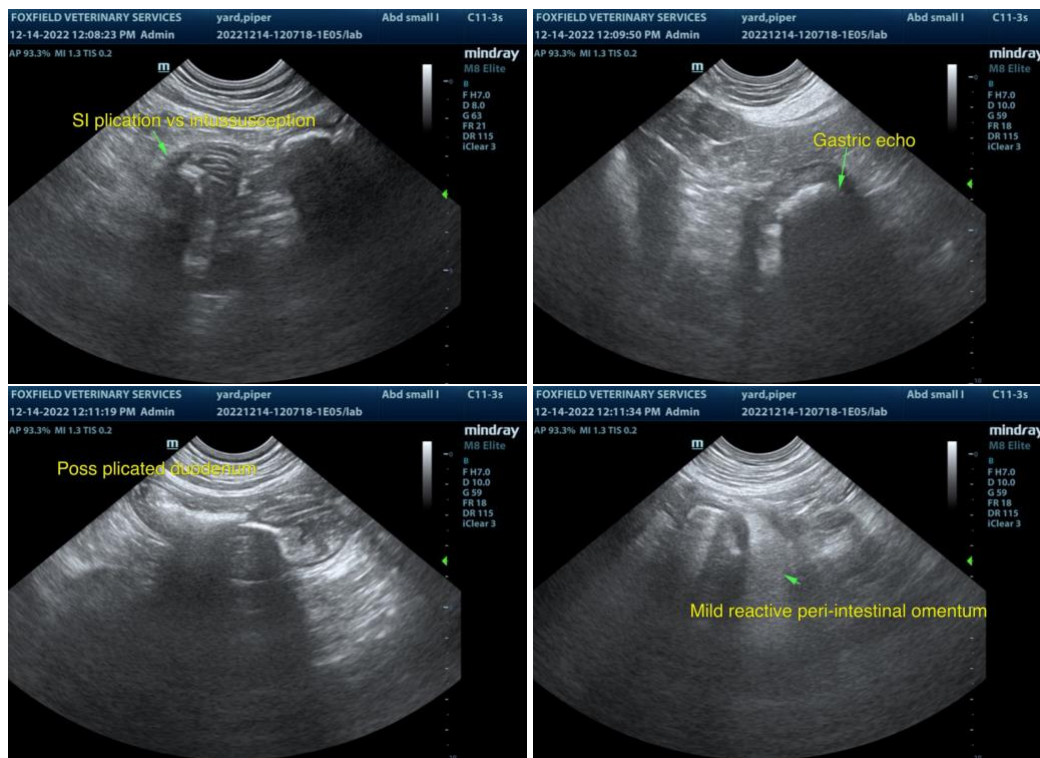
A. Rodriguez

INVOICE

20074

DATE

12/14/22



The information and recommendations provided are based on the images presented by the referring veterinarian. No evaluation can be communicated regarding pathology that was not visible in the image/video clips provided.

Thank you for this referral. If the clinical or image interpretation does not parallel your findings or if I can be of any further assistance please contact me.

R. McKenzie Daniel, DVM, DABVP (Canine / Feline Practice)
info@SonoPath.com