



## PATIENT

Stewie Crawford

## SPECIES

Canine

## BREED

Boxer

## SEX

MN

## AGE

9 years

## WEIGHT

79 lbs.

## INTERPRETED BY

R. McKenzie Daniel,  
DVM, DABVP  
(Canine and Feline)

## IMAGING PERFORMED BY

Kelly Vazquez

## HOSPITAL NAME

Ho-Ho-Kus VH

## REFERRING VET

Dr. Dan Eisenberg

## INVOICE

12800

## DATE

12/14/21

## PRESENTING CLINICAL SIGNS

Acute ADR, not eating, and lethargic. Tachycardia with occasional VPCs. No current meds.  
Abnormal PE/Chem/CBC/UA Results: CBC/Chem: WNL.

## ULTRASONOGRAPHIC EXAMINATION OF THE HEART & ABDOMEN

CANINE CARDIAC PARAMETERS	MR VMAX (m/s)	TR VMAX (m/s)	LA/AO (Boon method)	LA/AO (Heart Base; Swe)	FS (%)	EF (%)	EPSS (cm)
NORMAL PARAMETER	4.5-5.5	<2.7	1.3	<1.6	28-40	40-100	<0.6
PATIENT			--	1.45	41.2	75.4	0.2
CANINE CARDIAC PARAMETERS	HR (BPM)	AV VMAX (m/s)	PV MAX (m/s)	BODY WEIGHT (kg)	LA 2D short axis Base view (cm)	LVIDd Avg; 2D and m-mode short axis (cm)	LVIDs Avg; 2D and m-mode short axis (cm)
NORMAL PARAMETER	50-100	0.7-1.7	0.7-1.6	BELOW	BELOW	BELOW	BELOW
PATIENT	136	1.4	1.2		3.6	3.4	

### Cardiac Presentation

The echocardiogram in this patient demonstrated normal **left atrial** size based on 3 separate methods of LA evaluation. The cranial and caudal **mitral** valve leaflets presented normal linear structure, extension in systole, and union in diastole with normal kinesis. The **left ventricle** presented thicknesses with linear contour and was not dilated nor restricted. The **myocardium** presented normal echogenicity without subjective evidence of significant fibrotic or ischemic disease.

**Contractility** of the ventricular walls was adequate and in normal range for this patient evidenced by the fractional shortening measurement and subjective evaluation of the different regions of the myocardium. The **left ventricular outflow** tract demonstrated normal laminar flow and subjective structural integrity. The **right atrium** and auricle revealed normal size, structure and content. No evidence of masses was noted. **Tricuspid** valvular assessment demonstrated adequate linear morphology and kinesis. The **right ventricle** was of normal size (1/3 diameter of LV), chordae structure, myocardial echogenicity and thickness. **Pulmonary outflow** tract assessment revealed normal valve structure, laminar flow, and diameter (approx. 1:1 pa/ao ratio). No visible **pericardial** or free pleura fluid was noted. The cranial **mediastinum and pericardial and extra-cardiac regions** were free of masses in the visible window. Overt evidence of tachycardia or arrhythmogenic disease was not definitively evident in this study.

### Urinary System

The urinary bladder, trigone, cystourethral junction, and visible pelvic urethra to a depth of 3.0 cm exhibited normal thickness and tone. Anechoic urine was present in the lumen with no uroliths or



<b>PATIENT</b>	sediment. The ureteral papillae were normal. The ureters were not visible which is normal. No evidence of inflammatory or neoplastic changes was noted.
Stewie Crawford	
<b>SPECIES</b>	The residual prostate was symmetrically normal in size with uniform parenchyma and slight coarse echotexture measuring 0.8 cm in diameter.
Canine	The area of the aortic trifurcation was free of pathology. No evidence of medial iliac or sublumbar lymphadenopathy was noted.
<b>BREED</b>	
Boxer	Normal size and margination were present in the kidneys. A normal 1:3 cortex / medulla ratio and normal corticomedullary definition were maintained. The echogenicity of the cortex was similar to or slightly less than normal liver parenchyma while the medulla echogenicity was hypoechoic to the cortex with no evidence of pelvic dilation. The left kidney measured 6.6 cm in length. The right kidney measured 5.5 cm in length.
<b>SEX</b>	
MN	
<b>AGE</b>	<b>Adrenal Glands</b>
9 years	The left adrenal gland was uniform in size and contour with a uniformly hypoechoic parenchyma. The left adrenal gland measured 2.7 cm length x 0.67 cm width at the caudal pole. The right adrenal gland was uniform in size and contour with a uniformly hypoechoic parenchyma. The right adrenal gland measured 0.59 cm width at the caudal pole.
<b>WEIGHT</b>	
79 lbs.	
<b>INTERPRETED BY</b>	<b>Spleen</b>
R. McKenzie Daniel, DVM, DABVP (Canine and Feline)	The spleen exhibited overall subjective normal size and generalized mild splenic heterogeneity with multiple, mildly hypoechoic, non-expansive parenchymal nodules. An example measured 1.0 cm in diameter. The nodules did not appear to distort the splenic capsule. Normal splenic vascularity was present.
<b>IMAGING PERFORMED BY</b>	<b>Liver/ Gallbladder</b>
Kelly Vazquez	The liver was subjectively normal in size, structure, and contour. The liver parenchyma was mildly nonuniform and hypoechoic to the spleen with a moderate coarse echotexture and subjective mild to benign parenchymal remodeling. The hepatic and portal vasculature were normal in appearance without signs of congestion. The gallbladder was non-distended in size with thin walls and primarily anechoic luminal content. The cystic and common bile ducts were normal.
<b>HOSPITAL NAME</b>	<b>Gastrointestinal</b>
Ho-Ho-Kus VH	The visualized gastric walls were sonographically unremarkable. The lumen of the stomach contained moderate, ingesta exhibiting subtle progressive distal acoustic shadowing. The stomach contained concurrent luminal gas. No overt evidence of mechanical pyloric outflow obstruction was noted. The ventral gastric body wall width measured 0.36 cm.
<b>REFERRING VET</b>	
Dr. Dan Eisenberg	The small intestine presented intact wall layering with 1:3 muscularis/mucosa ratio. The lumen of the small intestine was empty with no signs of ileus, obstruction, or foreign material. The duodenum wall width measured 0.48 cm.
<b>INVOICE</b>	
12800	Normal visible colon wall layers were present with apparent formed feces in lumen.
<b>DATE</b>	
12/14/21	



**PATIENT**

Stewie Crawford

**SPECIES**

Canine

**BREED**

Boxer

**SEX**

MN

**AGE**

9 years

**WEIGHT**

79 lbs.

**INTERPRETED BY**

R. McKenzie Daniel,  
DVM, DABVP  
(Canine and Feline)

**IMAGING  
PERFORMED BY**

Kelly Vazquez

**HOSPITAL NAME**

Ho-Ho-Kus VH

**REFERRING VET**

Dr. Dan Eisenberg

**INVOICE**

12800

**DATE**

12/14/21

***Pancreas***

The parenchyma of the left limb, body, and right limb of the pancreas presented isoechoic to the adjacent omental fat. A normal curvilinear capsule contour of the pancreas was present. The visible pancreatic duct was normal. No signs of active inflammation or neoplastic disease were evident.

***Free Abdomen***

No omental masses, lymphadenopathy or peritoneal effusion were present.

**ULTRASONOGRAPHIC FINDINGS**

***Primary Findings***

- Overtly normal cardiac structure and function
- Multiple, non-expansive, hypoechoic splenic nodules
- Gastric ingesta - nonspecific

**INTERPRETATION OF THE FINDINGS & FURTHER RECOMMENDATIONS**

Potential etiologies for the hypoechoic splenic nodules may include benign processes such as nodular hyperplasia, extramedullary hematopoiesis, hematoma, infection, infarction, or neoplasia. Ultrasound guided FNA of the nodule using 25-gauge needle and assuming normal coagulation parameters is recommended. Otherwise, sonographic monitoring of the splenic nodules for any changes in size or appearance with initial recheck in 3-4 weeks would be a more conservative approach.

The presence of gastric ingesta, in light of the patient's history of inappetence, is nonspecific. Considerations may include unknown post prandial presentation with potential of gastric hypomotility if documented NPO. The possibility of gastric foreign material such as fabric, stuffing, or similar cannot be definitively excluded. Radiographic or sonographic monitoring for evidence of gastric emptying following a documented fast is recommended.

No overt evidence of structural or functional cardiomyopathy was present. Given the reported tachycardia and VPCs, considerations may include emerging cardiomyopathy such as arrhythmogenic right ventricular cardiomyopathy, in light of breed, although drug / toxin exposure, electrolyte abnormalities (not present in light of normal lab work), intraabdominal disease (potential splenic disease in this case), or nonspecific infectious / inflammatory disease may also result in VPCs. Potential Holter Monitor may be indicated in this patient.



**PATIENT**

Stewie Crawford

**SPECIES**

Canine

**BREED**

Boxer

**SEX**

MN

**AGE**

9 years

**WEIGHT**

79 lbs.

**INTERPRETED BY**

R. McKenzie Daniel,  
DVM, DABVP  
(Canine and Feline)

**IMAGING PERFORMED BY**

Kelly Vazquez

**HOSPITAL NAME**

Ho-Ho-Kus VH

**REFERRING VET**

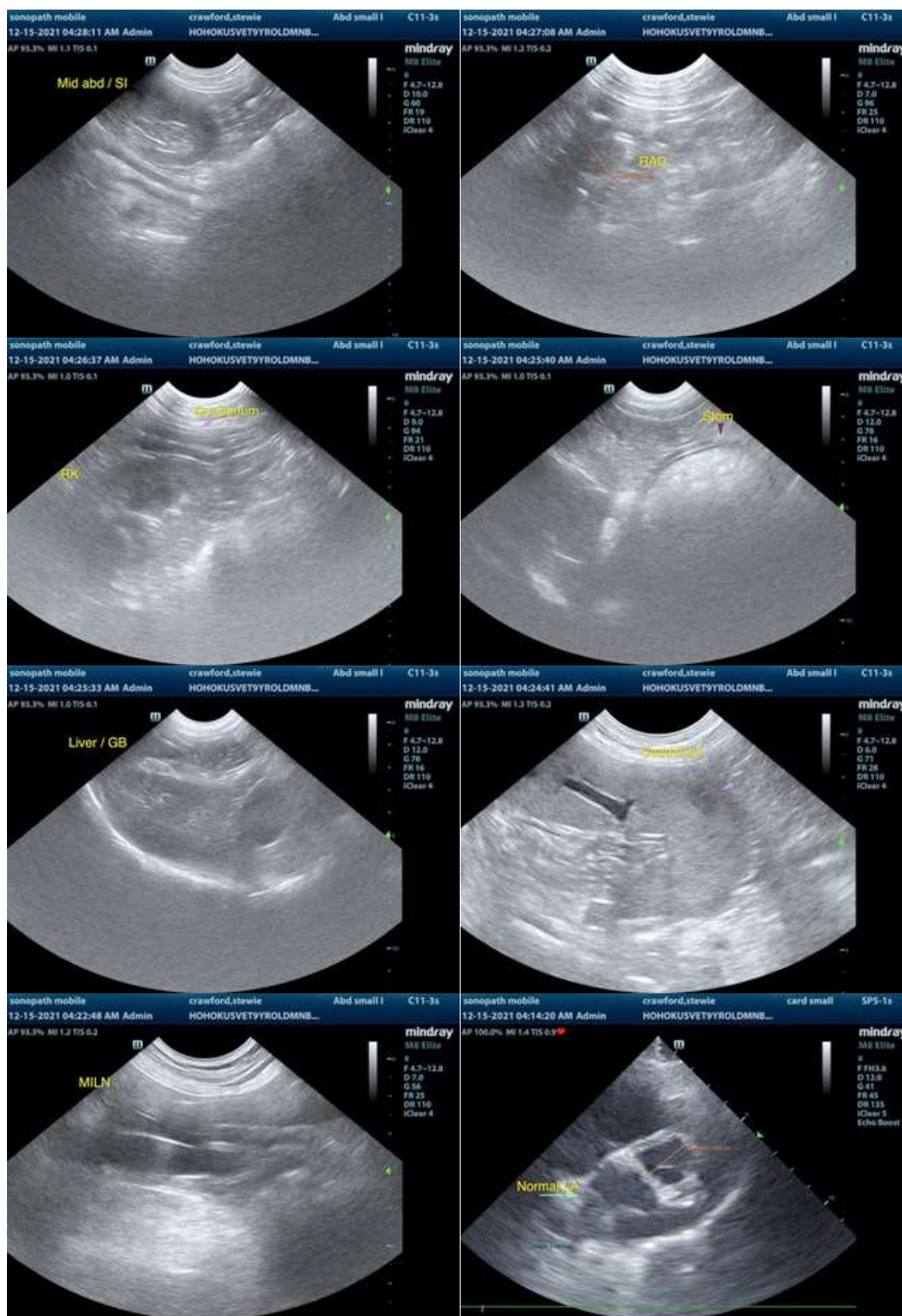
Dr. Dan Eisenberg

**INVOICE**

12800

**DATE**

12/14/21





**PATIENT**

Stewie Crawford

**SPECIES**

Canine

**BREED**

Boxer

**SEX**

MN

**AGE**

9 years

**WEIGHT**

79 lbs.

**INTERPRETED BY**

R. McKenzie Daniel,  
DVM, DABVP  
(Canine and Feline)

**IMAGING PERFORMED BY**

Kelly Vazquez

**HOSPITAL NAME**

Ho-Ho-Kus VH

**REFERRING VET**

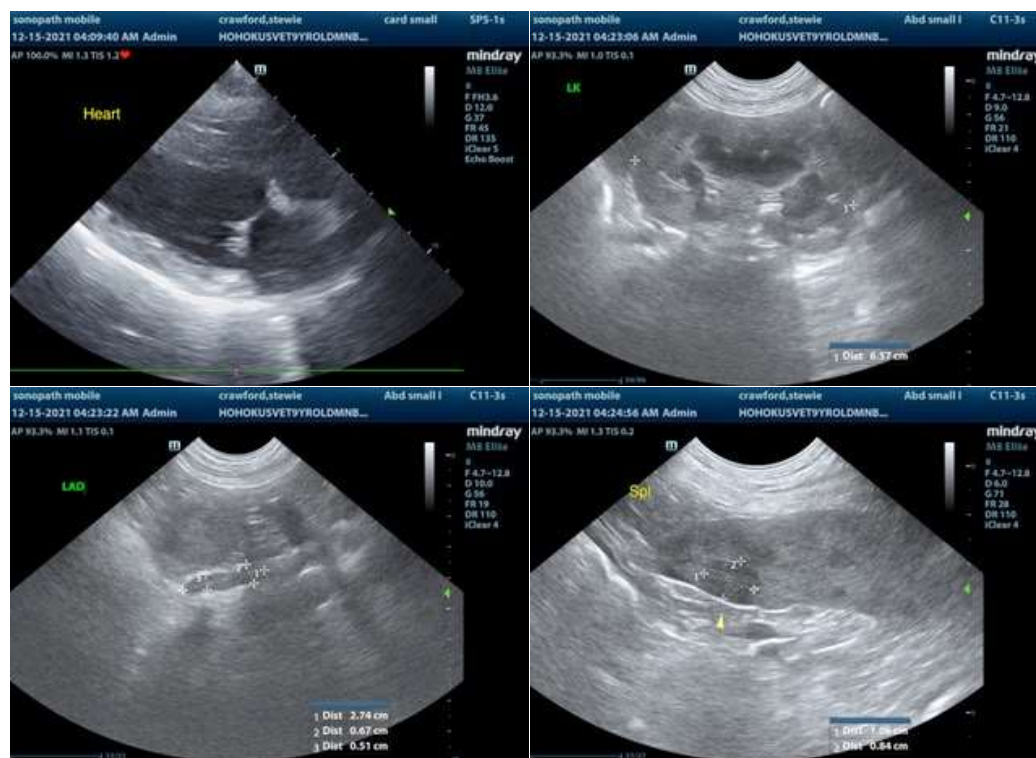
Dr. Dan Eisenberg

**INVOICE**

12800

**DATE**

12/14/21



**The information and recommendations provided are based on the images presented by the referring veterinarian. No evaluation can be communicated regarding pathology that was not visible in the image/video clips provided.**

Thank you for this referral. If the clinical or image interpretation does not parallel your findings or if I can be of any further assistance please contact me.

**R. McKenzie Daniel, DVM, DABVP (Canine / Feline Practice)**  
info@SonoPath.com