



PATIENT

Mia McNeil

SPECIES

Canine

BREED

Jack Russ X

SEX

FS

AGE

10

WEIGHT

6.4 kg

INTERPRETED BY

R. McKenzie Daniel,
DVM, DABVP
(Canine and Feline)

IMAGING PERFORMED BY

Dr. Belan

HOSPITAL NAME

Beddington Trail AH

REFERRING VET

Dr. Bahadur

INVOICE

12816

DATE

12/14/21

PRESENTING CLINICAL SIGNS

4/6 murmur on wellness exam, Chest x ray showed enlarged LA and liver. Non clinical not on any cardiac meds. Assess heart disease

ULTRASONOGRAPHIC EXAMINATION OF THE HEART

CANINE CARDIAC PARAMETERS	MR VMAX (m/s)	TR VMAX (m/s)	LA/AO (Boon method)	LA/AO (Heart Base; Swe)	FS (%)	EF (%)	EPSS (cm)
NORMAL PARAMETER	4.5-5.5	<2.7	1.3	<1.6	28-40	40-100	<0.6
PATIENT	6.1	1.7	NM	1.4	47.8	80.8	0.2
CANINE CARDIAC PARAMETERS	HR (BPM)	AV VMAX (m/s)	PV MAX (m/s)	BODY WEIGHT (kg)	LA 2D short axis Base view (cm)	LVIDd Avg; 2D and m-mode short axis (cm)	LVIDs Avg; 2D and m-mode short axis (cm)
NORMAL PARAMETER	50-100	0.7-1.7	0.7-1.6	BELOW	BELOW	BELOW	BELOW
PATIENT	134	1.6	0.85		3.2	2.8	

Cardiac Presentation

The echocardiogram in this patient demonstrated minor enlarged **left atrial** size based on 3 different LA measurement methods. Subtle deviation of the atrial septum towards the right atrium suggestive of potential minor increased left atrial pressure was present. The cranial and caudal **mitral** valve leaflets presented vegetative thickening consistent with endocardiosis. Doppler indicated measurable eccentric insufficiency. The **left ventricle** presented thicknesses with linear contour and was not dilated nor restricted. The **myocardium** presented normal echogenicity without subjective evidence of significant fibrotic or ischemic disease. **Contractility** of the ventricular walls was adequate and in normal range for this patient evidenced by the fractional shortening measurement and subjective evaluation of the different regions of the myocardium. The **left ventricular outflow** tract demonstrated normal laminar flow and subjective structural integrity. The **right atrium** and auricle revealed normal size, structure and content. No evidence of masses was noted or chamber overload. **Tricuspid** valvular assessment demonstrated adequate linear morphology. Mild tricuspid valve insufficiency was present on color doppler assessment. The **right ventricle** was of normal size (1/3 diameter of LV), chordae structure, myocardial echogenicity and thickness. **Pulmonic** tract assessment revealed normal valve structure, laminar flow, and diameter (approx. 1:1 pa/ao ratio). No visible **pericardial** or free pleura fluid was noted. No echographically detectable evidence of infiltrative disease was visible. The cranial **mediastinum and pericardial regions** were free of masses in the visible window.



PATIENT

Mia McNeil

SPECIES

Canine

BREED

Jack Russ X

SEX

FS

AGE

10

WEIGHT

6.4 kg

INTERPRETED BY

R. McKenzie Daniel,
DVM, DABVP
(Canine and Feline)

IMAGING PERFORMED BY

Dr. Belan

ULTRASONOGRAPHIC FINDINGS

Primary Findings

- Chronic mitral valve disease (ACVIM Early B2)
- Mild TV insufficiency - estimated pulmonary pressure gradient not consistent with clinical pulmonary hypertension

INTERPRETATION OF THE FINDINGS & FURTHER RECOMMENDATIONS

The cause of the murmur is consistent with chronic degenerative valvular changes with secondary eccentric mitral valve insufficiency. The minor left atrium enlargement indicates that the overall current and future risk is mildly elevated, yet the overall heart is compensated at this time. In a nonclinical patient without evidence of significant left heart chamber enlargement, cardiac medications are not specifically Indicated. However, at this stage prognosis is highly variable and serial sonographic monitoring is recommended for further prognosis. Blood pressure assessment is suggested given the mild elevated MR velocity. Conservative monitoring at this stage would be appropriate, which may include initial baseline monitoring of resting respiration rate at home. Recheck echocardiogram is suggested in 6 months, sooner if clinical signs suggestive of left-sided heart disease develop. No overt anesthetic contraindications if needed. The following anesthetic protocol is suggested if clinically indicated.

Suggested anesthetic protocol may include opioid or Benzodiazepine pre-med, induction with Propofol or Alfaxalone, and appropriate gas anesthesia with avoidance of alpha 2 agonists.

<https://www.antechdiagnostics.com/cadet-braf>

HOSPITAL NAME

Beddington Trail AH

REFERRING VET

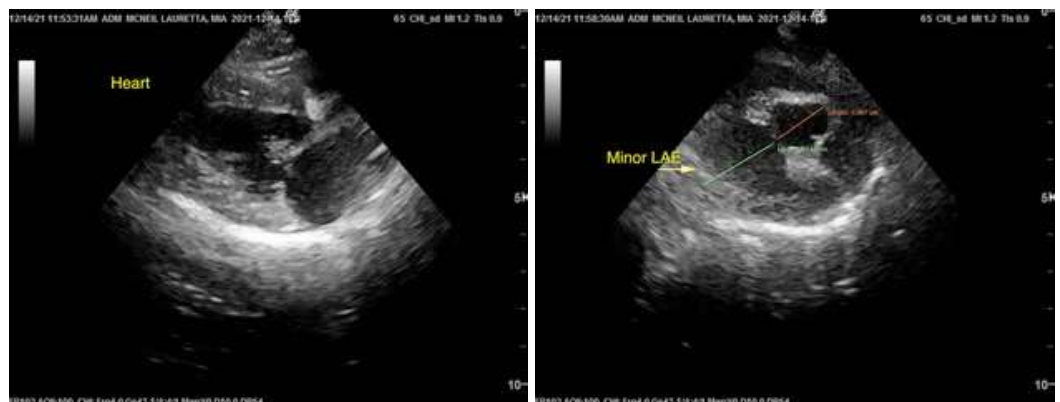
Dr. Bahadur

INVOICE

12816

DATE

12/14/21





PATIENT

Mia McNeil

SPECIES

Canine

BREED

Jack Russ X

SEX

FS

AGE

10

WEIGHT

6.4 kg

INTERPRETED BY

R. McKenzie Daniel,
DVM, DABVP
(Canine and Feline)

IMAGING PERFORMED BY

Dr. Belan

HOSPITAL NAME

Beddington Trail AH

REFERRING VET

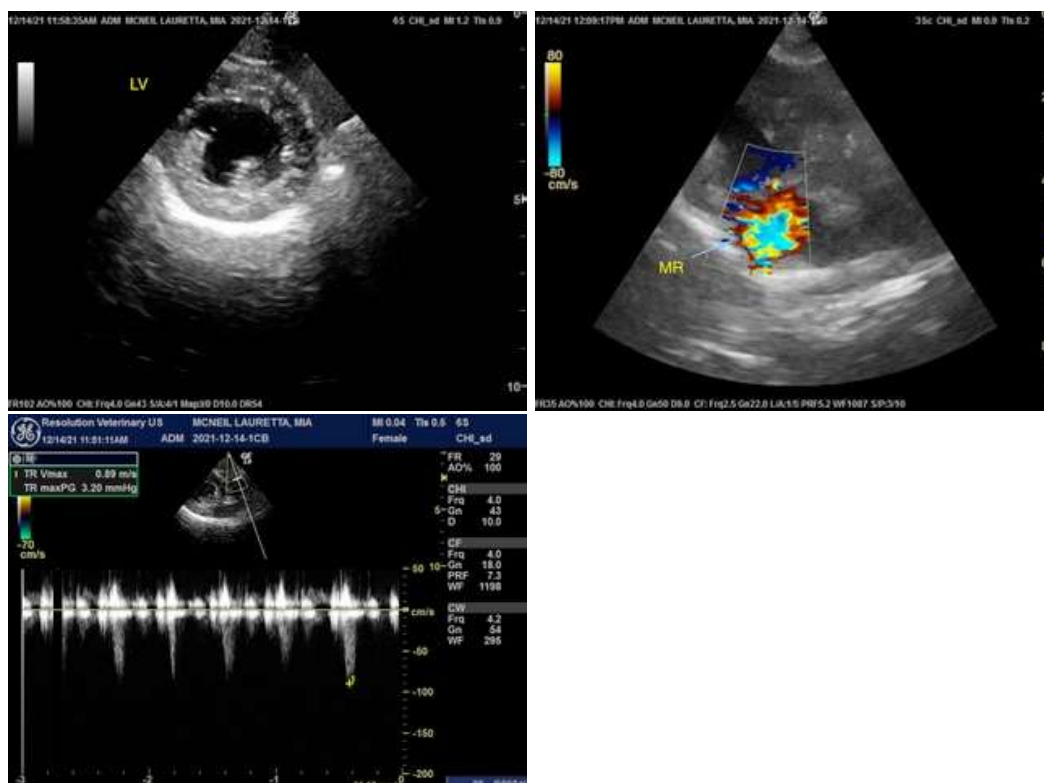
Dr. Bahadur

INVOICE

12816

DATE

12/14/21



The information and recommendations provided are based on the images presented by the referring veterinarian. No evaluation can be communicated regarding pathology that was not visible in the image/video clips provided.

Thank you for this referral. If the clinical or image interpretation does not parallel your findings or if I can be of any further assistance please contact me.

R. McKenzie Daniel, DVM, DABVP (Canine / Feline Practice)
info@SonoPath.com