



PATIENT

Tessa Abelman

SPECIES

Canine

BREED

Chihuahua

SEX

Spayed Female

AGE

10 Years

WEIGHT

6.9 Lbs.

INTERPRETED BY

R. McKenzie Daniel, DVM,
DABVP (Canine and Feline)

IMAGING PERFORMED BY

Sarah Pender, CVT

HOSPITAL NAME

SVS Imaging QC

REFERRING VET

Dr. Jessica
Fishbaugher

INVOICE

13050

DATE

12/13/21

PRESENTING CLINICAL SIGNS

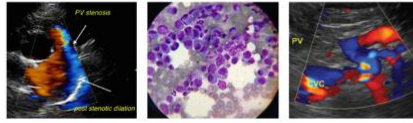
History: Requested consult for removal of mass in right axilla area. Abnormal PE/Chem/CBC/UA Results: 1.5x1.75in firm, slightly lobulated mass. Feels to be fixed at middle portion to chest. Edges are able to get fingers under slightly. Heart murmur grade 2/6. No clinical signs related to heart. Recommended further workup for heart murmur before pursuing surgery.

ULTRASONOGRAPHIC EXAMINATION OF THE HEART

CANINE CARDIAC PARAMETERS	MR VMAX (m/s)	TR VMAX (m/s)	LA/AO (Boon method)	LA/AO (Heart Base; Swe)	FS (%)	EF (%)	EPSS (cm)
NORMAL PARAMETER	4.5-5.5	<2.7	1.3	<1.6	28-40	40-100	<0.6
PATIENT	--	--	NM	1.65	35	65	0.3
CANINE CARDIAC PARAMETERS	HR (BPM)	AV VMAX (m/s)	PV MAX (m/s)	BODY WEIGHT (kg)	LA 2D short axis Base view (cm)	LVIDd Avg; 2D and m-mode short axis (cm)	LVIDs Avg; 2D and m-mode short axis (cm)
NORMAL PARAMETER	50-100	0.7-1.7	0.7-1.6				
PATIENT	105	1.1	0.8	--	2.0	2.2	--

Cardiac Presentation

The echocardiogram for this patient presented mild excessive **left atrial size** expressed both in the LA/AO and LA max measurements Chamber volumes and echogenicity were normal. The cranial and caudal **mitral** valve leaflets presented vegetative thickening consistent with endocardiosis. No evidence of valvular prolapse or chordae tendineae rupture. Doppler indicated measurable eccentric insufficiency. The **left ventricle** presented thicknesses with linear contour and was not dilated nor restricted. The **myocardium** presented normal echogenicity without subjective evidence of significant fibrotic or ischemic disease. **Contractility** of the ventricular walls was adequate and in normal range for this patient evidenced by the fractional shortening measurement and subjective evaluation of the different regions of the myocardium. The **left ventricular outflow** tract demonstrated normal laminar flow and subjective structural integrity. The **right atrium** and auricle revealed normal size, structure and content. No evidence of masses was noted or chamber overload. **Tricuspid** valvular assessment demonstrated adequate linear morphology. The **right ventricle** was of normal size (1/3 diameter of LV), chordae structure, myocardial echogenicity and thickness. **Pulmonic** tract assessment revealed normal valve structure, laminar flow, and diameter (approx.1:1 pa/ao ratio). No visible **pericardial** or free pleura fluid was noted. No echographically detectable evidence of infiltrative disease was visible. The cranial **mediastinum and pericardial regions** were free of masses in the visible window. Non-homogeneous to cystic subcutaneous mass, subjectively in the right lateral thorax (based on location and submitted pictures) was present. This subcutaneous mass measured approximately 3.5-4 cm length x 2 cm width. The subcutaneous mass exhibited pinpoint hyperechoic foci which may suggest pinpoint areas of mineralization while cystic component to the mass may indicate a cyst with potential for intramass necrosis or possible hemorrhage. The subcutaneous mass appeared to extend to the



PATIENT

Tessa Abelman

SPECIES

Canine

BREED

Chihuahua

SEX

Spayed Female

AGE

10 Years

WEIGHT

6.9 Lbs.

INTERPRETED BY

R. McKenzie Daniel, DVM,
DABVP (Canine and Feline)

IMAGING PERFORMED BY

Sarah Pender, CVT

HOSPITAL NAME

SVS Imaging QC

REFERRING VET

Dr. Jessica
Fishbaugher

INVOICE

13050

DATE

12/13/21

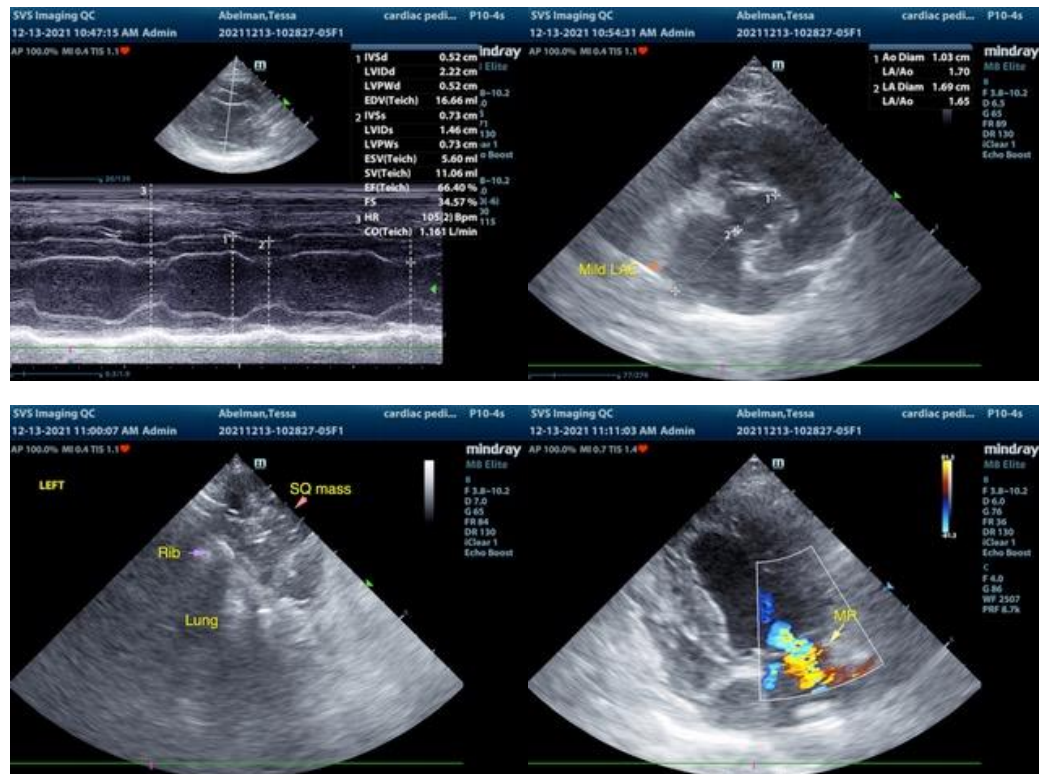
level of the thoracic wall yet did not overtly appear to invade the adjacent to regional thoracic cavity. Potential for possible adherent or potential invasion of the regional thoracic wall is certainly possible yet overt invasion into the thoracic cavity was not evident. Normal appearing lung, moving with respiration noted deep to the subcutaneous mass along with intermittent ribs.

ULTRASONOGRAPHIC FINDINGS

- Chronic mitral valve disease (Early ACVIM B-2)
- Non-homogeneous to cystic subcutaneous mass right lateral thorax

INTERPRETATION OF THE FINDINGS & FURTHER RECOMMENDATIONS

Given the lack of significant left atrium enlargement, the risk of current and future complication secondary to mitral valve insufficiency is considered low at this time yet prognosis is highly variable. In a nonclinical patient without evidence of significant chamber enlargement, specific cardiac medications are not indicated. No overt anesthetic contraindications, although, judicious fluid use under anesthesia is advised as the patient may be more susceptible to fluid overload. Recheck echocardiogram suggested in 6 months or sooner if clinical signs suggestive of heart disease develop. Although not definitive, concern for neoplastic criteria associated with the subcutaneous mass is warranted given its appearance which was not consistent with lipoma. FNA of the mass could be considered prior to surgical resection.



IMAGING PERFORMED BY

svsimaging.net 309-737-3070



Clinical Sonography & Telecytology

EDUCATIONAL TELECONSULTATION SERVICES™

1-800-838-4268 info@sonopath.com SonoPath.com

PATIENT

Tessa Abelman

SPECIES

Canine

BREED

Chihuahua

SEX

Spayed Female

AGE

10 Years

WEIGHT

6.9 Lbs.

INTERPRETED BY

R. McKenzie Daniel, DVM,
DABVP (Canine and Feline)

IMAGING PERFORMED BY

Sarah Pender, CVT

HOSPITAL NAME

SVS Imaging QC

REFERRING VET

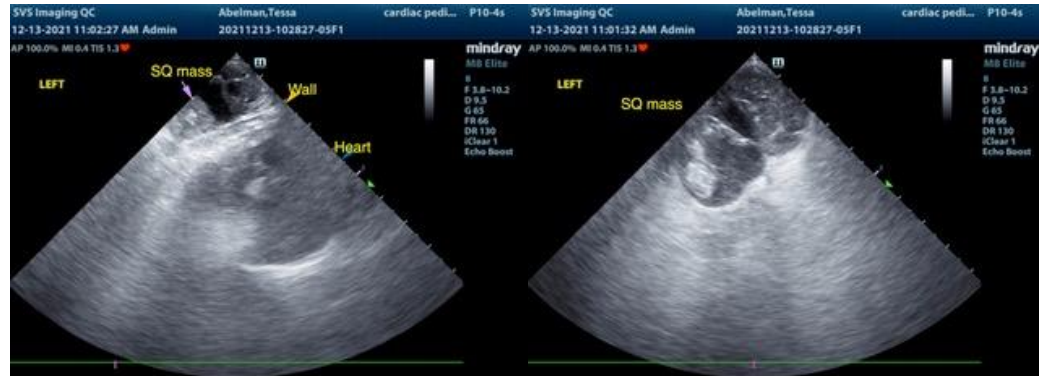
Dr. Jessica
Fishbaugter

INVOICE

13050

DATE

12/13/21



The information and recommendations provided are based on the images presented by the referring veterinarian. No evaluation can be communicated regarding pathology that was not visible in the image/video clips provided.

Thank you for this referral. If the clinical or image interpretation does not parallel your findings or if I can be of any further assistance please contact me.

R. McKenzie Daniel, DVM, DABVP (Canine / Feline Practice)
info@SonoPath.com