



PATIENT PRESENTING CLINICAL SIGNS

Miley Harris

Multiple bouts of gastro intestinal issues including melena, vomiting and diarrhea. Grade 4-5/6 heart murmur. Has been on Cerenia, Sucralfate, Omeprazole and Metronidazole. Abnormal PE/Chem/CBC/UA Results: Sept 2021 - CPLi 940(0-200), Lipase 702(0-250), otherwise chemistry unremarkable. CBC WNL except retics 137.7(10-110).

SPECIES

Canine

ULTRASONOGRAPHIC EXAMINATION OF THE HEART & ABDOMEN

BREED

Terrier X Spaniel

SEX

FS

AGE

9 years

WEIGHT

31.2 lbs.

INTERPRETED BY

R. McKenzie Daniel,
DVM, DABVP

IMAGING PERFORMED BY

Crystal Hill

HOSPITAL NAME

Beamsville AH

REFERRING VET

Dr. Hagar

INVOICE

12794

DATE

12/13/21

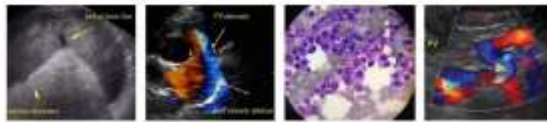
CANINE	MR	TR	LA/AO	LA/AO	FS	EF	EPSS
CARDIAC PARAMETERS	VMAX (m/s)	VMAX (m/s)	(Boon method)	(Heart Base; Swe)	(%)	(%)	(cm)
NORMAL PARAMETER	4.5-5.5	<2.7	1.3	<1.6	28-40	40-100	<0.6
PATIENT	6.4	<2.0	--	1.53	43.8	78.4	0.4
CANINE CARDIAC PARAMETERS	HR (BPM)	AV VMAX (m/s)	PV MAX (m/s)	BODY WEIGHT (kg)	LA 2D short axis Base view (cm)	LVIDd Avg; 2D and m-mode short axis (cm)	LVIDs Avg; 2D and m-mode short axis (cm)
NORMAL PARAMETER	50-100	0.7-1.7	0.7-1.6	BELOW	BELOW	BELOW	BELOW
PATIENT	NM	1.9	1.3		3.5	3.2	

Cardiac Presentation

The echocardiogram in this patient demonstrated mildly enlarged **left atrial** size based on 3 different LA measurement methods. Chamber volumes and echogenicity were normal. The cranial and caudal **mitral** valve leaflets presented vegetative thickening consistent with endocardiosis. Doppler indicated measurable eccentric insufficiency. The **left ventricle** presented thicknesses with linear contour and was not dilated nor restricted. The **myocardium** presented normal echogenicity without subjective evidence of significant fibrotic or ischemic disease. **Contractility** of the ventricular walls was adequate and in normal range for this patient evidenced by the fractional shortening measurement and subjective evaluation of the different regions of the myocardium. The **left ventricular outflow** tract demonstrated normal laminar flow and subjective structural integrity. The **right atrium** and auricle revealed normal size, structure and content. No evidence of masses was noted or chamber overload. **Tricuspid** valvular assessment demonstrated adequate linear morphology. The **right ventricle** was of normal size (1/3 diameter of LV), chordae structure, myocardial echogenicity and thickness. **Pulmonic** tract assessment revealed normal valve structure, laminar flow, and diameter (approx. 1:1 pa/ao ratio). No visible **pericardial** or free pleura fluid was noted. No echographically detectable evidence of infiltrative disease was visible. The cranial **mediastinum and pericardial regions** were free of masses in the visible window.



PATIENT	<i>Urinary System</i>
Miley Harris	The urinary bladder, trigone, and cystourethral junction exhibited normal thickness and tone. Anechoic urine was present in the lumen with no uroliths or sediment. The ureteral papillae were normal. The ureters were not visible which is normal. No evidence of inflammatory or neoplastic changes was noted.
SPECIES	
Canine	The area of the aortic trifurcation was free of pathology.
BREED	
Terrier X Spaniel	Normal size and margination were present in the kidneys. A normal 1:3 cortex / medulla ratio was maintained. The medulla and cortices were uniform in texture with some increased echogenicity and mild loss of corticomedullary symmetry and definition expected for the age of the patient. No evidence of pelvic dilation was present. The left kidney measured 5.8 cm in length. The right kidney measured 5.4 cm in length.
SEX	
FS	<i>Adrenal Glands</i>
AGE	
9 years	The left adrenal gland was uniform in size and contour with a uniformly hypoechoic parenchyma. The left adrenal gland measured 0.65 cm width at the caudal pole and 0.65 cm width at the cranial pole. The right adrenal gland was uniform in size and contour with a uniformly hypoechoic parenchyma. The right adrenal gland measured 0.44 cm width at the caudal pole and 0.65 cm width at the cranial pole.
WEIGHT	
31.2 lbs.	<i>Spleen</i>
INTERPRETED BY	
R. McKenzie Daniel, DVM, DABVP	The spleen exhibited a finely textured and homogenous parenchyma which was hyperechoic to the liver and renal cortical parenchyma. The capsule was smooth and regular without apparent expansion. The splenic vasculature at the hilus was normal in volume with no evidence of congestion or thrombosis. Acute to chronic inflammatory, neoplastic, or benign parenchyma changes were not noted.
IMAGING PERFORMED BY	
Crystal Hill	<i>Liver/ Gallbladder</i>
HOSPITAL NAME	
Beamsville AH	The liver was subjectively normal in size, structure, and contour. The liver parenchyma was uniform and hypoechoic to the spleen with a mild coarse echotexture. The hepatic and portal vasculature were normal in appearance without signs of congestion. The gallbladder was non-distended in size with thin walls and primarily anechoic luminal content. The cystic and common bile ducts were normal.
REFERRING VET	
Dr. Hagar	<i>Gastrointestinal</i>
INVOICE	
12794	The visualized gastric walls were sonographically normal. The lumen of the stomach contained moderate, echogenic, nonshadowing ingesta most consistent with post prandial presentation without signs of ileus, obstruction or foreign material. The ventral gastric body wall width measured 0.31 cm. No evidence of gastric mural hypertrophy or overt masses was noted.
DATE	
12/13/21	The small intestine presented intact wall layering with 1:3 muscularis/mucosa ratio. The lumen of the small intestine was empty with no signs of ileus, obstruction, or foreign material. Mild segmental jejunal mucosal speckling was present. The jejunum wall width measured 0.40 cm. No evidence of loss of small intestinal wall layering or overt small intestinal masses.
	Normal visible colon wall layers were present with apparent formed feces in lumen.



PATIENT	<i>Pancreas</i>
Miley Harris	The parenchyma of the left limb, body, and right limb of the pancreas presented isoechoic to the adjacent omental fat. A normal curvilinear capsule contour of the pancreas was present. The visible pancreatic duct was normal. No signs of active inflammation or neoplastic disease were evident.
SPECIES	
Canine	<i>Free Abdomen</i>
	No overt lymphadenopathy or peritoneal effusion was present.
BREED	
Terrier X Spaniel	ULTRASONOGRAPHIC FINDINGS
	<i>Primary Findings</i>
SEX	<ul style="list-style-type: none"> • Chronic mitral valve disease (ACVIM B2)
FS	<ul style="list-style-type: none"> • Minor TR
AGE	<ul style="list-style-type: none"> • Minor age-related kidneys
9 years	<ul style="list-style-type: none"> • Gastric ingesta
	<ul style="list-style-type: none"> • Sonographically unremarkable small bowel with mild segmental jejunal mucosal speckling
WEIGHT	<u>INTERPRETATION OF THE FINDINGS & FURTHER RECOMMENDATIONS</u>
31.2 lbs.	The cause of the murmur is chronic degenerative valvular changes with secondary eccentric mitral valve insufficiency. The lack of significant left atrium enlargement indicates that the risk for complication is low at this time although the prognosis is highly variable. In a non-clinical patient without evidence of significant cardiac change, cardiac medications are not overtly indicated. Conservative monitoring at this time is recommended. Assessment of systemic blood pressure is suggested given the elevated mitral regurgitation velocity.
INTERPRETED BY	
R. McKenzie Daniel, DVM, DABVP	The presence of gastric ingesta is nonspecific and likely indicates post-prandial presentation. Correlation with most recent meal ingestion is recommended. If documented NPO prior to the ultrasound, the presence of gastric ingesta may indicate some degree of gastric hypomotility or metabolic stasis. The sonographic presentation of the ingesta was most consistent with food, without evidence of foreign material.
IMAGING PERFORMED BY	
Crystal Hill	
HOSPITAL NAME	
Beamsville AH	The mild jejunal mucosal speckling is nonspecific yet may be associated with underlying inflammation / enteritis. Potential for low-grade to chronic pancreatitis may be possible yet ultrasonographically normal.
REFERRING VET	
Dr. Hagar	In patients with recurrent or chronic gastrointestinal signs, mild pancreatitis, dysbiosis, food hypersensitivity / dietary intolerance, IBD, or less likely intestinal neoplasia are possible. A GI panel to include PLI/TLI/Cobalamin/Folate is recommended. Fresh fecal analysis to assess for parasitic ova / giardia is suggested.
INVOICE	
12794	
DATE	Although though less likely, adrenal screening with resting cortisol would be warranted to rule out occult Addison's disease.
12/13/21	



PATIENT

Miley Harris

SPECIES

Canine

BREED

Terrier X Spaniel

SEX

FS

AGE

9 years

WEIGHT

31.2 lbs.

INTERPRETED BY

R. McKenzie Daniel,
DVM, DABVP

**IMAGING
PERFORMED BY**

Crystal Hill

HOSPITAL NAME

Beamsville AH

REFERRING VET

Dr. Hagar

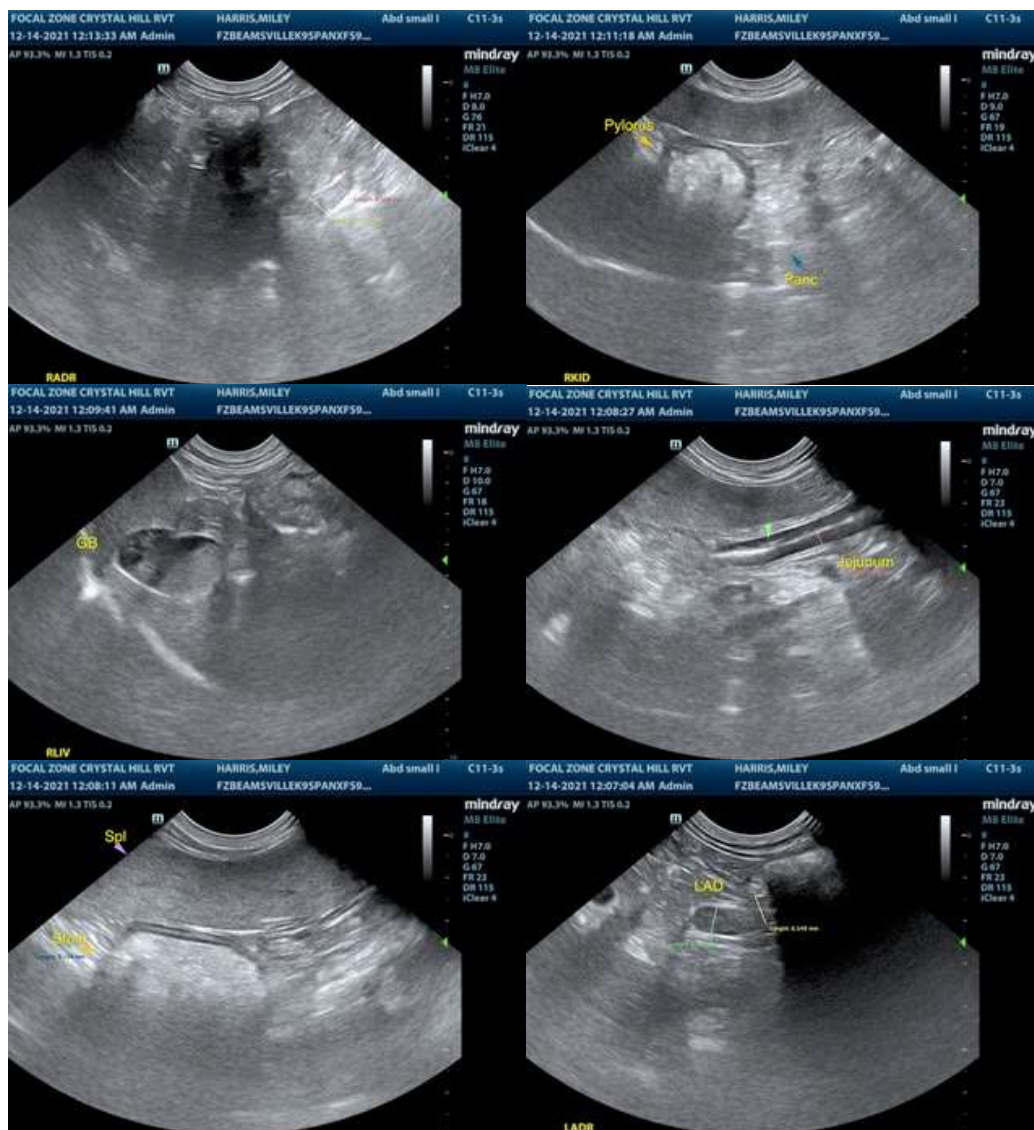
INVOICE

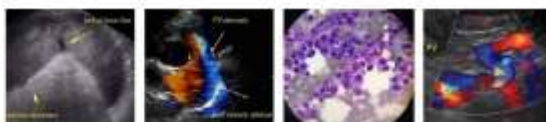
12794

DATE

12/13/21

Empirically, a limited antigen or hydrolyzed diet trial with potential long term dietary therapy, prophylactic deworming (Panacur 50 mg/kg SID x 5 consecutive days with repeat protocol in 3 weeks even if fecal testing is negative), high colony count probiotic (Provable or Visbiome), antibiotic trial and as needed gastrointestinal support with assessment of clinical response may prove beneficial. Intestinal biopsies may be indicated if GI signs continue despite empirical therapy.





PATIENT

Miley Harris

SPECIES

Canine

BREED

Terrier X Spaniel

SEX

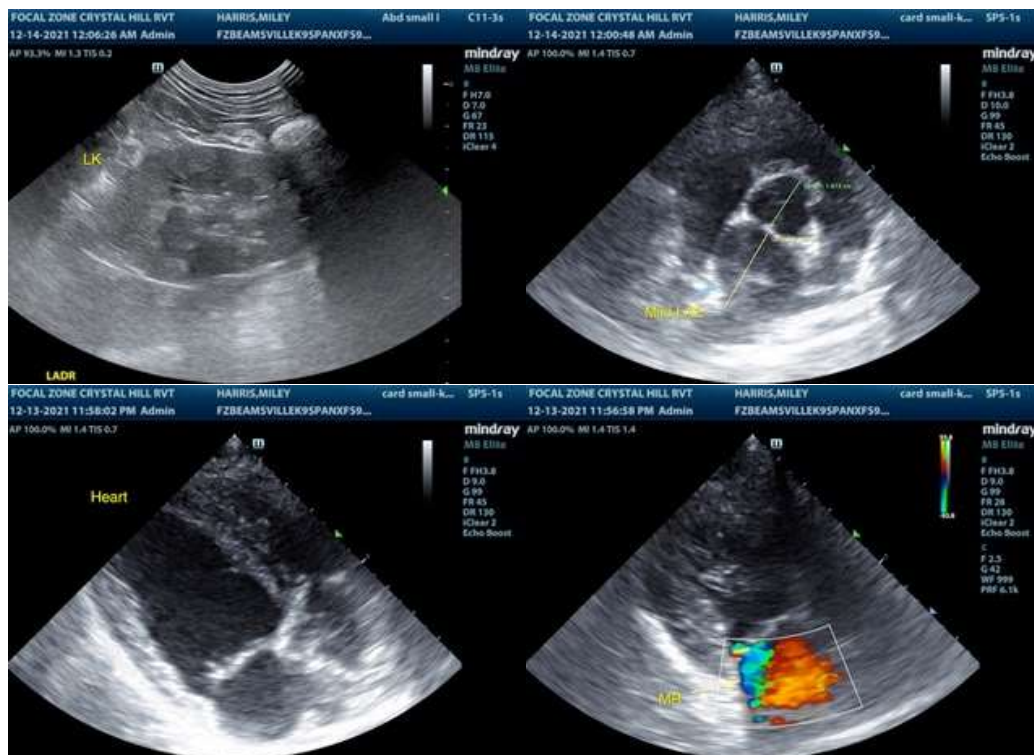
FS

AGE

9 years

WEIGHT

31.2 lbs.



INTERPRETED BY

R. McKenzie Daniel,
DVM, DABVP

IMAGING PERFORMED BY

Crystal Hill

HOSPITAL NAME

Beamsville AH

REFERRING VET

Dr. Hagar

INVOICE

12794

DATE

12/13/21

The information and recommendations provided are based on the images presented by the referring veterinarian. No evaluation can be communicated regarding pathology that was not visible in the image/video clips provided.

Thank you for this referral. If the clinical or image interpretation does not parallel your findings or if I can be of any further assistance please contact me.

R. McKenzie Daniel, DVM, DABVP (Canine / Feline Practice)
info@SonoPath.com