



PATIENT

Chewy Defilippo

SPECIES

Canine

BREED

Bernedoodle

SEX

Male Neutered

AGE

5 y

WEIGHT

63.5 lbs

INTERPRETED BY

R. McKenzie Daniel,
DVM, DABVP
(Canine and Feline)

IMAGING PERFORMED BY

Pamela Harrigan,
RDCS, Certified
Veterinary
Sonographer

HOSPITAL NAME

Norfolk County VS

REFERRING VET

Tami Ilovich, DVM

INVOICE

12926

DATE

12/12/25

PRESENTING CLINICAL SIGNS

History: Presented in November for vomiting, soft stools - resolved. History pancreatitis. R/O IBD. Has been on GI diet. Normal GI panel.

ULTRASONOGRAPHIC EXAMINATION OF THE ABDOMEN

Urinary System

The urinary bladder, trigone, cystourethral junction, and visible pelvic urethra exhibited normal thickness and tone. Anechoic urine was present in the lumen with no uroliths or sediment. The ureteral papillae were normal. The ureters were not visible which is normal. No evidence of inflammatory or neoplastic changes were noted.

The residual prostate was sonographically normal.

Normal size and margination was present in the kidneys. A normal 1:3 cortex / medulla ratio and normal corticomedullary definition were maintained. The echogenicity of the cortex was similar to or slightly less than normal liver parenchyma while the medulla echogenicity was hypoechoic to the cortex with no evidence of pelvic dilation. The left kidney measured 7.5 cm in length. The right kidney measured 7.9 cm in length.

Adrenal Glands

The left adrenal gland was uniform in size and contour with a uniformly hypoechoic parenchyma. The left adrenal gland measured 0.54 cm width at the caudal pole. The right adrenal gland was uniform in size and contour with a uniformly hypoechoic parenchyma. The right adrenal gland measured 0.58 cm width at the caudal pole.

Spleen

The spleen exhibited a finely textured and homogenous parenchyma which was hyperechoic to the liver and renal cortical parenchyma. The capsule was smooth and regular without apparent expansion. The splenic vasculature at the hilus was normal in volume with no evidence of congestion or thrombosis. Acute to chronic inflammatory, neoplastic, or benign parenchyma changes were not noted.

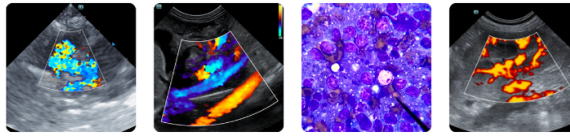
Liver

The liver was subjectively normal in size, structure, and contour. The liver parenchyma was uniform and hypoechoic to the spleen with a mild coarse echotexture. The hepatic and portal vasculature were normal in appearance without signs of congestion. The gallbladder was non-distended in size with thin walls and primarily anechoic luminal content. The cystic and common bile ducts were normal.

Gastrointestinal

The stomach presented intact wall layering with a normal wall layer ratio. The lumen of the stomach was empty with no signs of ileus, obstruction or foreign material.

The small intestine presented intact overall non-thickened wall exhibiting propensity for mildly prominent duodenojejunal mucosa with duodenal and intermittent jejunal hyperechoic mucosal speckling to indistinct striations. Duodenum wall measured 0.53 cm and jejunum wall measured 0.42 cm. Subjectively mild prominent ileal submucosal layer.



PATIENT

Normal visible colon wall layers were present with apparent formed feces in lumen.

Chewy Defilippo

Pancreas

SPECIES

The parenchyma of the left limb, body and right limb of the pancreas presented isoechoic to the adjacent omental fat. A normal curvilinear capsule contour of the pancreas was present. The visible pancreatic duct was normal. No signs of active inflammation or neoplastic disease was evident.

Canine

BREED

Free Abdomen

Bernedoodle

Intermittent, mildly prominent to enlarged mesenteric nodes were present. The lymph nodes were essentially isoechoic to adjacent omentum without evidence of peripheral inflammation and maintaining a normal width: length ratio (<0.5). An example of lymph node measurement was 2.1 cm x 0.49 cm. No evidence of peritoneal effusion present.

SEX

Male Neutered

ULTRASONOGRAPHIC FINDINGS

AGE

- Normal empty stomach
- Duodenojejunal hyperechoic mucosal speckling/striations and subjective mild prominent ileum submucosa layer
- Sonographically normal pancreas

5 y

WEIGHT

63.5 lbs

INTERPRETATION OF THE FINDINGS & FURTHER RECOMMENDATIONS

INTERPRETED BY

Although nonspecific, the small intestine exhibited mild mucosa/mural changes which may suggest inflammatory criteria, i.e. nonspecific enteritis, IBD or other. No evidence of active or chronic pancreatitis given normal GI panel. Dietary support which may include hydrolyzed diet trial, possible long-term dietary therapy, as needed high colony count probiotics such as Provable. Consideration for as needed gastro protectants and empirical deworming, sonographic monitoring or reassessment indicated if recurrent or progressive gastrointestinal signs.

R. McKenzie Daniel,
DVM, DABVP
(Canine and Feline)

IMAGING PERFORMED BY

Pamela Harrigan,
RDCS, Certified
Veterinary
Sonographer

HOSPITAL NAME

Norfolk County VS

REFERRING VET

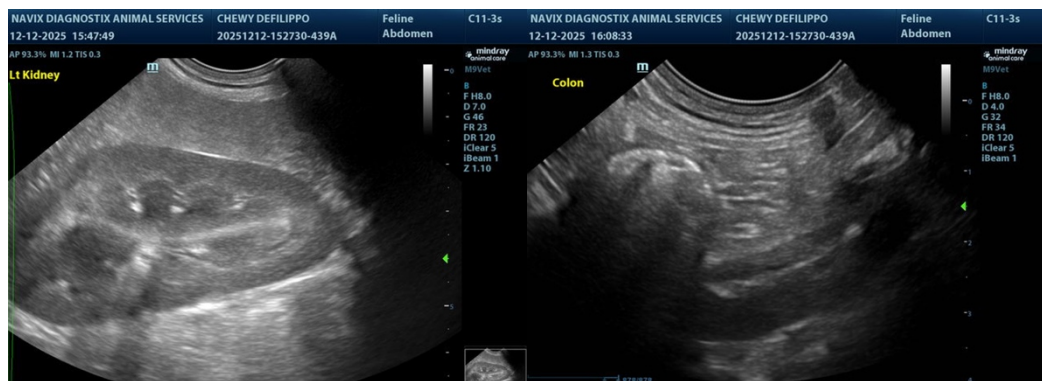
Tami Ilovich, DVM

INVOICE

12926

DATE

12/12/25





PATIENT

Chewy Defilippo

SPECIES

Canine

BREED

Bernedoodle

SEX

Male Neutered

AGE

5 y

WEIGHT

63.5 lbs

INTERPRETED BY

R. McKenzie Daniel,
DVM, DABVP
(Canine and Feline)

IMAGING PERFORMED BY

Pamela Harrigan,
RDCS, Certified
Veterinary
Sonographer

HOSPITAL NAME

Norfolk County VS

REFERRING VET

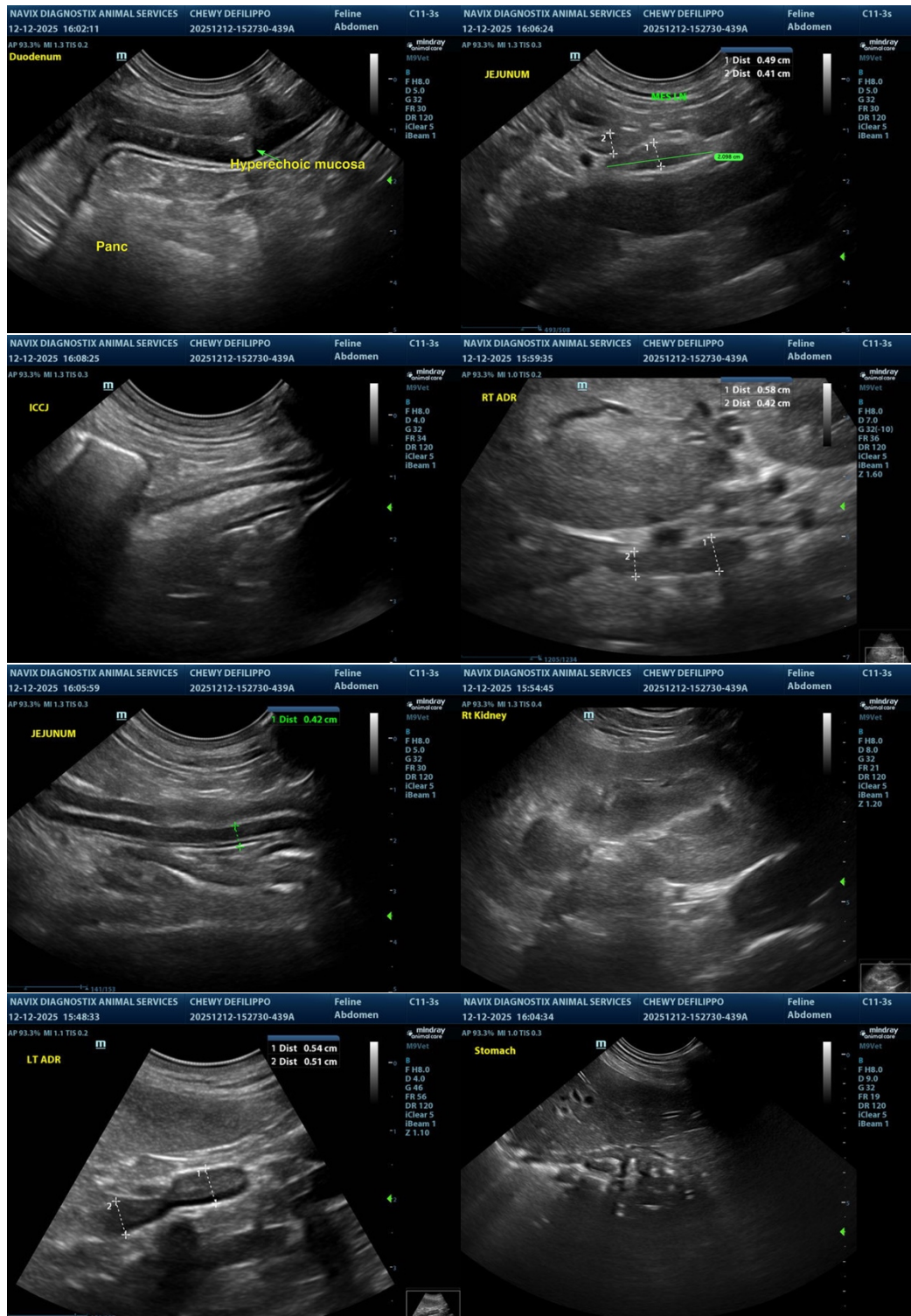
Tami Ilovich, DVM

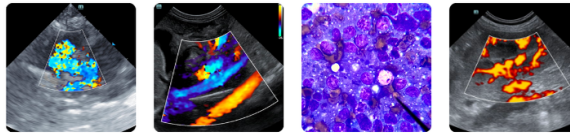
INVOICE

12926

DATE

12/12/25





PATIENT

Chewy Defilippo

SPECIES

Canine

BREED

Bernedoodle

SEX

Male Neutered

AGE

5 y

WEIGHT

63.5 lbs

INTERPRETED BY

R. McKenzie Daniel,
DVM, DABVP
(Canine and Feline)

**IMAGING
PERFORMED BY**

Pamela Harrigan,
RDCS, Certified
Veterinary
Sonographer

HOSPITAL NAME

Norfolk County VS

REFERRING VET

Tami Ilovich, DVM

INVOICE

12926

DATE

12/12/25

The information and recommendations provided are based on the images presented by the referring veterinarian/sonographer. No evaluation can be communicated regarding pathology that was not visible in the image/video clips provided.

Thank you for this referral. If the clinical or image interpretation does not parallel your findings or if I can be of any further assistance, please contact me.

R. McKenzie Daniel, DVM, DABVP (Canine / Feline Practice)

info@sonopath.com