



PATIENT

Deacon Millett

SPECIES

Canine

BREED

Maltese

SEX

MN

AGE

12 yrs

WEIGHT

6.3 lbs.

INTERPRETED BY

R. McKenzie Daniel,
DVM, DABVP
(Canine and Feline)

IMAGING PERFORMED BY

Kerri Becker

HOSPITAL NAME

American AH

REFERRING VET

Dr. Pascucci

INVOICE

10450

DATE

12/11/25

PRESENTING CLINICAL SIGNS

Grade 3/6 hm and want to pursue dental. Sometimes coughs.
Abnormal PE/Chem/CBC/UA Results: PLT-475k Mild neut and eos

ULTRASONOGRAPHIC EXAMINATION OF THE HEART

CANINE CARDIAC PARAMETERS	MR VMAX (m/s)	TR VMAX (m/s)	LA/AO (M-Mode)	LA/AO (Heart Base; Swe)	FS (%)	EF (%)	EPSS (cm)
NORMAL PARAMETER	4.5-5.5	<2.7	1.3	Up to 1.6	28-40	40-100	<0.6
PATIENT	6.0			1.6	36	68	0.2
CANINE CARDIAC PARAMETERS	HR (BPM)	AV VMAX (m/s)	PV MAX (m/s)	BODY WEIGHT (kg)	LAD LA MAX4 Chamber	LVIDd Avg; 2D and m-mode short axis (cm)	LVIDs Avg; 2D and m-mode short axis (cm)
NORMAL PARAMETER	50-100	0.7-1.7	0.7-1.6				
PATIENT	204	1.2	1.4		2.7	2.3	

Cardiac Presentation

The echocardiogram in this patient demonstrated mild increased **left atrial** size based on 2 different LA measurement methods. The cranial and caudal **mitral** valve leaflets presented thickening (anterior > posterior) consistent with endocardiosis with mild valve prolapse. Doppler indicated measurable borderline increased MR (MR velocity 6.0 m/s). The **left ventricle** presented thicknesses with linear contour and was not dilated nor restricted. The **myocardium** presented normal echogenicity without subjective evidence of significant fibrotic or ischemic disease. **Contractility** of the ventricular walls was adequate and in normal range for this patient evidenced by the fractional shortening measurement and subjective evaluation of the different regions of the myocardium. The **left ventricular outflow** tract demonstrated normal laminar flow and subjective structural integrity. The **right atrium** and auricle revealed normal size, structure and content. No evidence of masses was noted or chamber overload. **Tricuspid** valvular assessment demonstrated adequate linear morphology. The **right ventricle** was of normal size (1/3 diameter of LV), chordae structure, myocardial echogenicity and thickness. **Pulmonic** tract assessment revealed normal valve structure, laminar flow, and diameter (approx.1:1 pa/ao ratio). No visible **pericardial** or free pleura fluid was noted. No echographically detectable evidence of cardiac / pericardial tumors was visible.

ULTRASONOGRAPHIC FINDINGS

- Chronic mitral valve disease (ACVIM B2)



PATIENT

Deacon Millett

SPECIES

Canine

BREED

Maltese

SEX

MN

AGE

12 yrs

WEIGHT

6.3 lbs.

INTERPRETED BY

R. McKenzie Daniel,
 DVM, DABVP
 (Canine and Feline)

IMAGING PERFORMED BY

Kerri Becker

HOSPITAL NAME

American AH

REFERRING VET

Dr. Pascucci

INVOICE

10450

DATE

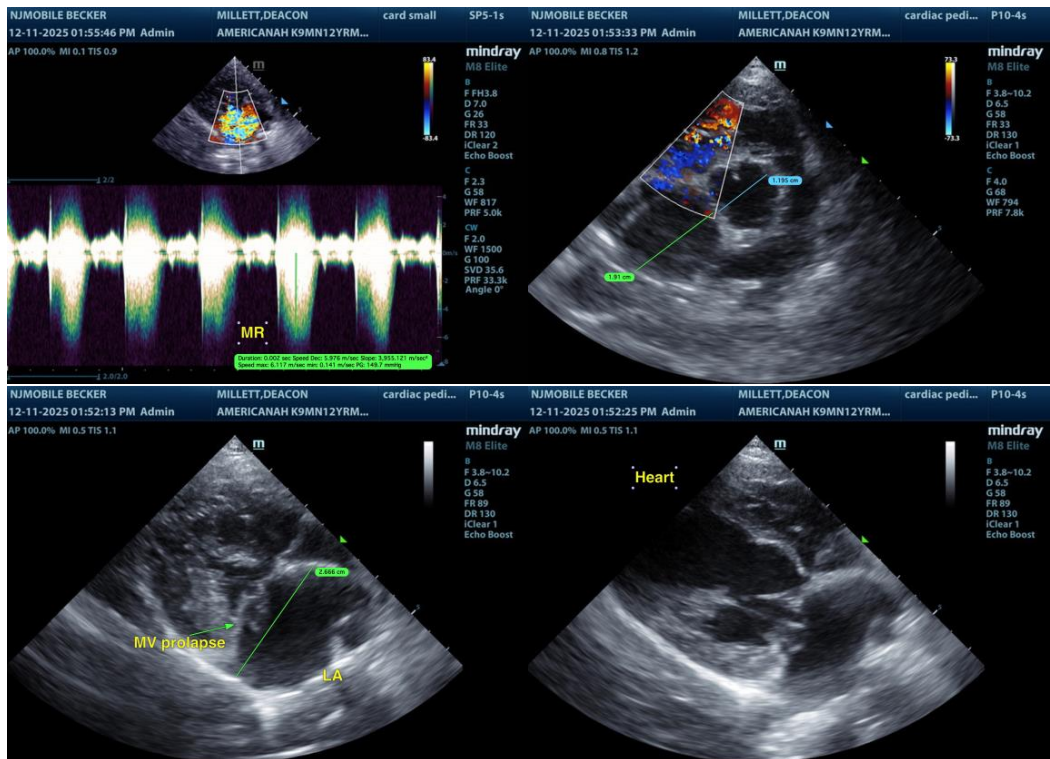
12/11/25

INTERPRETATION OF THE FINDINGS & FURTHER RECOMMENDATIONS

The cause of the murmur is chronic degenerative valvular changes with secondary eccentric mitral valve insufficiency. The left atrial enlargement implies that the risk of complication secondary to mitral valve insufficiency is elevated, yet overall the heart appears stable. No other clinical issues such as LV systolic dysfunction or clinical pulmonary hypertension.

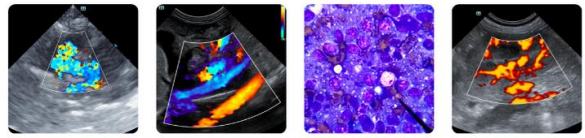
Pimobendan 0.3 mg/kg BID is recommended. No overt indication for additional medication. Prognosis is considered variable and sonographic monitoring is recommended. Recheck echocardiogram is suggested in 6 months, sooner if clinical signs arise. Assessment of systemic BP for evidence of hypertension, given borderline elevated MR velocity, is recommended. If no evidence of hypertension, anesthetic risk is mild, yet likely reduced once on Pimobendan for 3-5 days. The following anesthetic protocol is recommended with clinical monitoring and appropriate to judicious IV fluid use.

Suggested anesthetic protocol may include opioid or Benzodiazepine pre-med, induction with Propofol or Alfaxalone, and appropriate gas anesthesia with avoidance of alpha 2 agonists.



The information and recommendations provided are based on the images presented by the referring veterinarian/sonographer. No evaluation can be communicated regarding pathology that was not visible in the image/video clips provided.

Thank you for this referral. If the clinical or image interpretation does not parallel your findings or if I can be of any further assistance, please contact me.



PATIENT

Deacon Millett

R. McKenzie Daniel, DVM, DABVP (Canine / Feline Practice)
info@sonopath.com

SPECIES

Canine

BREED

Maltese

SEX

MN

AGE

12 yrs

WEIGHT

6.3 lbs.

INTERPRETED BY

R. McKenzie Daniel,
DVM, DABVP
(Canine and Feline)

**IMAGING
PERFORMED BY**

Kerri Becker

HOSPITAL NAME

American AH

REFERRING VET

Dr. Pascucci

INVOICE

10450

DATE

12/11/25