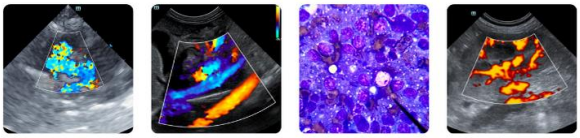

PATIENT
Blackberry Finkelshteyn

SPECIES
Canine

BREED
French Bulldog

SEX
FS

AGE
12 years

WEIGHT
33 lbs.

INTERPRETED BY
R. McKenzie Daniel, DVM, DABVP (Canine and Feline)

IMAGING PERFORMED BY
Rebecca Hamilton

HOSPITAL NAME
Allendale VH

REFERRING VET
Dr. Izar

INVOICE
10451

DATE
12/11/25

PRESENTING CLINICAL SIGNS

Recurrent bacterial cystitis. 10/23/25 Hematuria, cultured Proteus, Tx Clavacillin 250 mg BID X 2 weeks w/ no resolution of signs. Recheck culture: Proteus still present, treated w/ Enroflox 136 mg x 7 days. Symptoms resolved and recheck culture 7 days later - negative. 2 weeks later on 12/9, has hematuria and mild pu/pd again. 12/9 culture pending. Started pet back on Enroflox 136 mg SID, not lethargic.

Abnormal PE/Chem/CBC/UA Results: Rods, no crystals, PH 6.0, RBC + WBC, USG 1..034. Chem: Creat 1.3, SDMA mild ^ 16.8, BUN 21

ULTRASONOGRAPHIC EXAMINATION OF THE ABDOMEN

Urinary System

The urinary bladder was normal in size and tone, exhibiting mildly thickened ventroapical to dorsoapical wall with a mild asymmetrical luminal surface contour. Maintained homogeneous mural echogenicity was noted. No evidence of mural mineralization or tumors. The apical wall measured 0.54 cm. Anechoic urine was present in the lumen with minor particulate urine sediment. The ureteral papillae were normal. The ureters were not visible which is normal. The proximal urethra to a depth of 3.0 cm exhibited a thickened appearance with a possible indistinctly marginated, nonhomogeneous, nonmineralized proximal urethra mass, potentially measuring 3.5 cm x 0.46 cm. The overall proximal urethral width measured 0.58 cm.

No evidence of medial Iliac or sublumbar lymphadenopathy/masses.

Normal size and margination were present in the kidneys. A normal 1:3 cortex / medulla ratio was maintained. The medulla and cortices were uniform in texture with some increased echogenicity and mild loss of corticomedullary symmetry and definition expected for the age of the patient. No evidence of pelvic dilation was present. No evidence of pyelectasia was noted in either kidney. The left kidney measured 4.4 cm in length. The right kidney measured 4.3 cm in length.

Adrenal Glands

The bilateral adrenal glands were normal in size. Mild parenchyma heterogeneity and mild capsule asymmetry were present without suspicion for overt neoplasia. The left adrenal gland measured 0.79 cm width in the caudal pole. The right adrenal gland measured 0.62 cm width in the caudal pole.

Spleen

The spleen exhibited a finely textured and homogenous parenchyma which was hyperechoic to the liver and renal cortical parenchyma. The capsule was smooth and regular without apparent expansion. The splenic vasculature at the hilus was normal in volume with no evidence of congestion or thrombosis. Acute to chronic inflammatory, neoplastic, or benign parenchyma changes were not noted.

Liver/ Gallbladder

The liver was subjectively normal in size, structure, and contour. The liver parenchyma was mildly nonuniform and hypoechoic to the spleen with a moderate coarse echotexture and subjective mild to benign parenchymal remodeling. The hepatic and portal vasculature were normal in appearance without

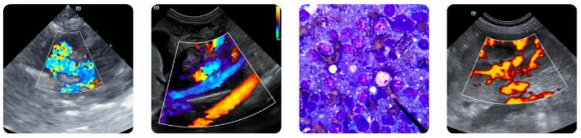

PATIENT
Blackberry Finkelshteyn

SPECIES
Canine

BREED
French Bulldog

SEX
FS

AGE
12 years

WEIGHT
33 lbs.

INTERPRETED BY
R. McKenzie Daniel, DVM, DABVP (Canine and Feline)

IMAGING PERFORMED BY
Rebecca Hamilton

HOSPITAL NAME
Allendale VH

REFERRING VET
Dr. Izar

INVOICE
10451

DATE
12/11/25

signs of congestion. The gallbladder was non-distended in size containing primarily anechoic content with minor gallbladder debris. The cystic and common bile ducts were normal.

Gastrointestinal

The stomach presented intact wall layering with a normal wall layer ratio. The lumen of the stomach contained mild, echogenic, nonshadowing ingesta without signs of obstruction or foreign material.

The small intestine presented intact wall layering with 1:3 muscularis/mucosa ratio. The lumen of the small intestine was empty with no signs of ileus, obstruction, or foreign material.

Normal visible colon wall layers were present with apparent formed feces in lumen.

Pancreas

The parenchyma of the left limb, body, and right limb of the pancreas presented isoechoic to the adjacent omental fat. A normal curvilinear capsule contour of the pancreas was present. The visible pancreatic duct was normal. No signs of active inflammation or neoplastic disease were evident.

Free Abdomen

No overt lymphadenopathy or peritoneal effusion was present.

ULTRASONOGRAPHIC FINDINGS

- Probable mild apical cystitis
- Thickened proximal urethra with possible urethral mass
- Bilateral mild chronic renal changes
- Mild hepatic remodeling with mild gallbladder debris (non mucocele)

INTERPRETATION OF THE FINDINGS & FURTHER RECOMMENDATIONS

Correlation with pending urine C/S is recommended. Proximal urethritis or an indistinct urethral mass are both potentials. A BRAF assay is recommended. Cystoscopy or traumatic catheterization for cytology or histopathology is likely required for a definitive diagnosis. NSAID trial in conjunction with empirical UTI protocol, pending urine C/S with sonographic monitoring of the urinary bladder and proximal urethra would be reasonable.

New Jersey Mobile
FUELED BY SONOPATH VETERINARY ULTRASOUND

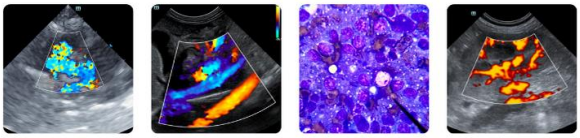

Clinical Sonography & Telecytology
Educational Teleconsultation Services™

SonoPath
FOSTERING THE ART OF VETERINARY MEDICINE™
www.SonoPath.com
info@sonopath.com 800.838.4268

PATIENT
Blackberry Finkelshteyn

SPECIES
Canine

BREED
French Bulldog

SEX
FS

AGE
12 years

WEIGHT
33 lbs.

INTERPRETED BY
R. McKenzie Daniel, DVM, DABVP (Canine and Feline)

IMAGING PERFORMED BY
Rebecca Hamilton

HOSPITAL NAME
Allendale VH

REFERRING VET
Dr. Izar

INVOICE
10451

DATE
12/11/25

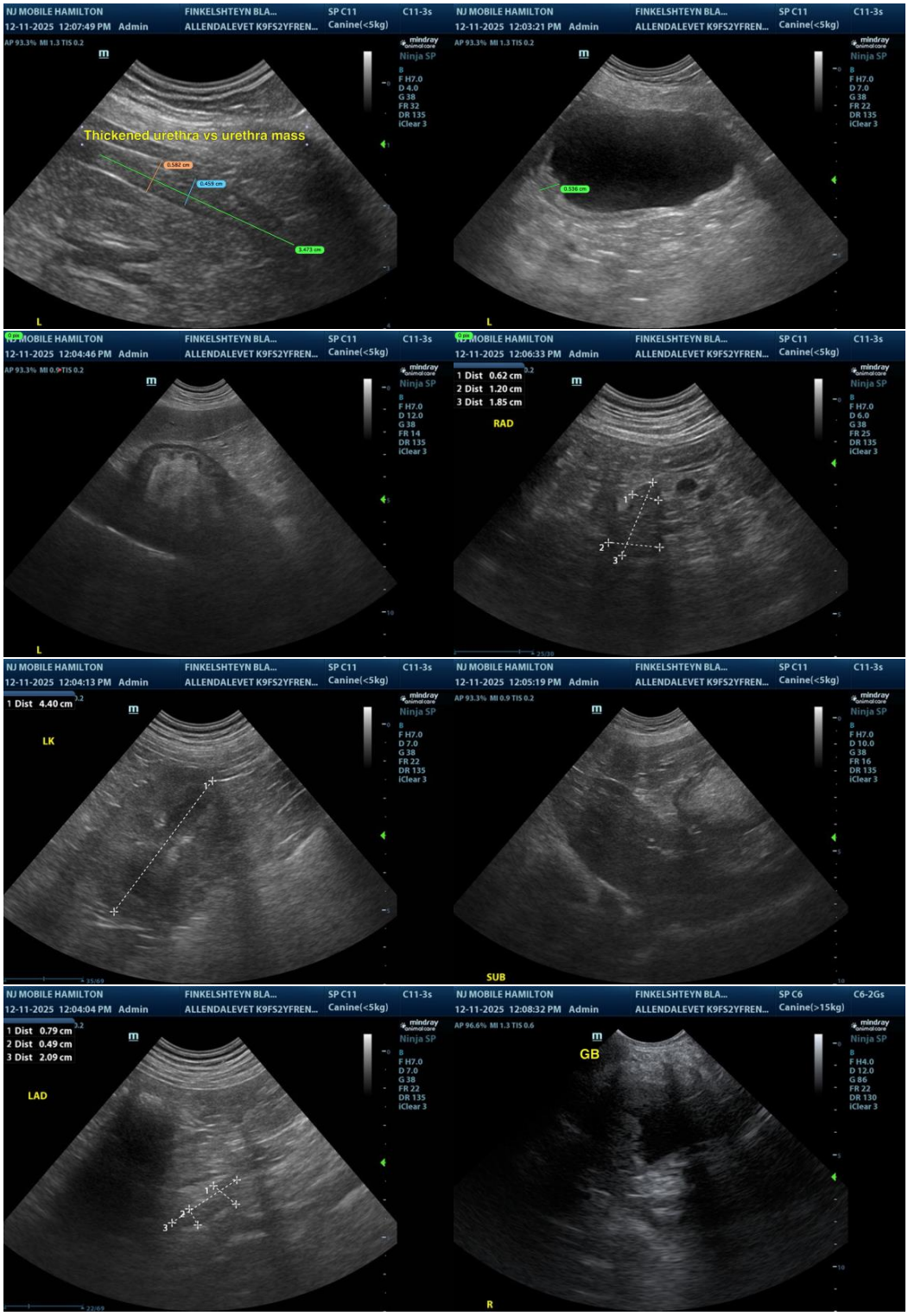

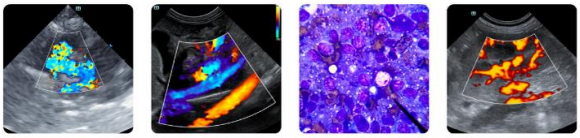

PATIENT
Blackberry Finkelshteyn

SPECIES
Canine

BREED
French Bulldog

SEX
FS

AGE
12 years

WEIGHT
33 lbs.

INTERPRETED BY
R. McKenzie Daniel, DVM, DABVP (Canine and Feline)

IMAGING PERFORMED BY
Rebecca Hamilton

HOSPITAL NAME
Allendale VH

REFERRING VET
Dr. Izar

INVOICE
10451

DATE
12/11/25

The information and recommendations provided are based on the images presented by the referring veterinarian/sonographer. No evaluation can be communicated regarding pathology that was not visible in the image/video clips provided.

Thank you for this referral. If the clinical or image interpretation does not parallel your findings or if I can be of any further assistance, please contact me.

R. McKenzie Daniel, DVM, DABVP (Canine/Feline Practice)
info@sonopath.com