SonoPath
Clinical Sonography & Telecytology
EDUCATIONAL TELECONSULTATION SERVICES™

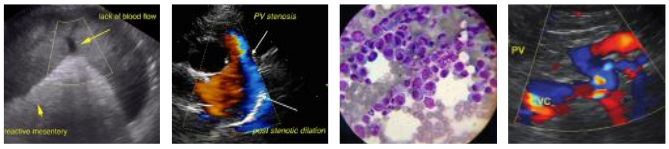

SonoPath.com™
1-800-838-4268 info@sonopath.com

PATIENT
Bucky Romero

SPECIES
Feline

BREED
DSH

SEX
MN

AGE
9 yrs. 9 mo.

WEIGHT
9.9 lbs

INTERPRETED BY
R. McKenzie Daniel, DVM, DABVP (Canine and Feline)

IMAGING PERFORMED BY
Dr. Ebersole

HOSPITAL NAME
Scanvet

REFERRING VET
Dr. McGarvey

INVOICE
15435

DATE
11/9/22

PRESENTING CLINICAL SIGNS

Chronic vomiting and continued weight loss. Most recently will vomit unless on Cerenia daily.
Abnormal PE/Chem/CBC/UA Results: CBC/Chem/T-4/UA: all WNL

ULTRASONOGRAPHIC EXAMINATION OF THE ABDOMEN

Urinary System

The urinary bladder, trigone, cystourethral junction, and visible pelvic urethra to a depth of 2.0 cm exhibited normal thickness and tone. Anechoic urine was present in the lumen with no uroliths or sediment. The ureteral papillae were normal. The ureters were not visible which is normal. No evidence of inflammatory or neoplastic changes was noted.

The area of the aortic trifurcation was free of pathology.

Normal size and margination were present in the kidneys. A normal 1:3 cortex / medulla ratio and normal corticomedullary definition were maintained. The echogenicity of the cortex was similar to or slightly less than normal liver parenchyma while the medulla echogenicity was hypoechoic to the cortex with no evidence of pelvic dilation. The left kidney measured 3.7 cm in length. The right kidney measured 4.2 cm in length.

Adrenal Glands

The left adrenal gland was uniform in size and contour with a uniformly hypoechoic parenchyma. The left adrenal gland measured 0.42 cm width. No overt pathology was noted in the area of the right adrenal gland.

Spleen

The spleen exhibited a finely textured and homogenous parenchyma which was hyperechoic to the liver and renal cortical parenchyma. The capsule was smooth and regular without apparent expansion. The splenic vasculature at the hilus was normal in volume with no evidence of congestion or thrombosis. Acute to chronic inflammatory, neoplastic, or benign parenchyma changes were not noted. The spleen measured 0.84 cm width at the level of the hilus.

Liver/ Gallbladder

The liver was subjectively normal in size, structure, and contour. The liver parenchyma was uniform and hypoechoic to the spleen with a mild coarse echotexture. The hepatic and portal vasculature were normal in appearance without signs of congestion. The gallbladder was non-distended in size with thin walls and primarily anechoic luminal content. The cystic and common bile ducts were normal.

Gastrointestinal

The stomach presented intact wall layering with a normal wall layer ratio. The lumen of the stomach was empty with no signs of ileus, obstruction, or foreign material. The gastric body wall width measured 0.24 cm.

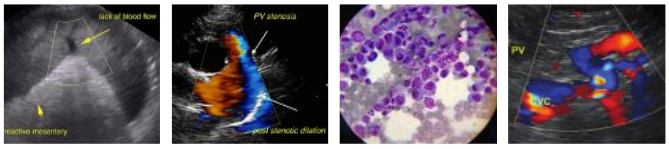

SonoPath.com™
1-800-838-4268 info@sonopath.com

PATIENT
Bucky Romero

SPECIES
Feline

BREED
DSH

SEX
MN

AGE
9 yrs. 9 mo.

WEIGHT
9.9 lbs

INTERPRETED BY
R. McKenzie Daniel, DVM, DABVP (Canine and Feline)

IMAGING PERFORMED BY
Dr. Ebersole

HOSPITAL NAME
Scanvet

REFERRING VET
Dr. McGarvey

INVOICE
15435

DATE
11/9/22

The small intestine presented intact yet generalized mildly prominent to thickened wall layering exhibiting mild altered muscularis: mucosa ratio owing to generalized propensity for variably prominent muscularis layer. The duodenum wall measured 0.30 cm width. The jejunum wall measured up to 0.34 cm width. The ileocolic wall measured 0.32 cm width.

Normal visible colon wall layers were present with apparent formed feces in lumen.

Pancreas

The pancreas was normal in size and contour with isoechoic to heterogeneous parenchyma compared to adjacent omentum. No signs of active inflammation or neoplasia.

Free Abdomen

Intermittent midabdominal mesenteric lymph nodes were present. These lymph nodes were homogenous, mildly hypoechoic and smoothly marginated. A normal width: length ratio was maintained (<0.5). Evidence of perilymphatic inflammation was evident. An example of lymph node size was 3.5 cm x 1.3 cm. No free fluid or omental masses were present.

ULTRASONOGRAPHIC FINDINGS

- Infiltrative enteropathy pattern exhibiting intact yet altered wall layer ratio - inflammatory vs. neoplastic infiltrative enteropathy i.e., IBD/ eosinophilic enteritis vs. intestinal round cell neoplasia such as lymphoma possible
- Associated intermittent mesenteric lymphadenopathy - hyperplasia, reactive lymphadenitis, early neoplastic lymphadenopathy
- Sonographically unremarkable pancreas

INTERPRETATION OF THE FINDINGS & FURTHER RECOMMENDATIONS

A GI panel to include PLI/TLI/Cobalamin/Folate is recommended. Screening mesenteric lymph node FNA cytology could be considered for initial assessment. Full-thickness intestinal +/- lymphatic biopsies are likely required for a definitive diagnosis.

Triad disease is considered a less likely potential in this case given the lack of hepatic enzyme elevations with overall normal sonographic hepatic and pancreatic presentation.

Empirically or if biopsies are not elected, IBD protocol with as-needed gastrointestinal support, monitoring of clinical response and weight loss going forward would be reasonable.

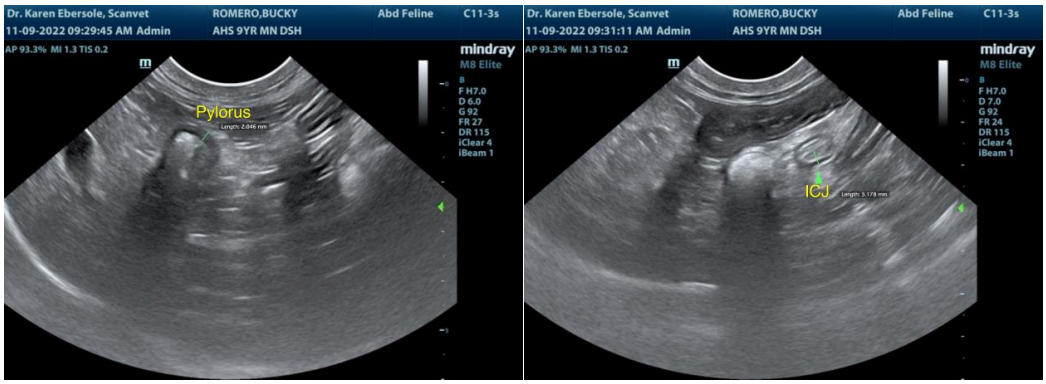

SonoPath

Clinical Sonography & Telecytology

EDUCATIONAL TELECONSULTATION SERVICES™

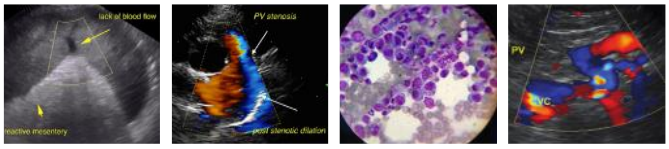

SonoPath.com™
1-800-838-4268 info@sonopath.com

PATIENT

Bucky Romero

SPECIES

Feline

BREED

DSH

SEX

MN

AGE

9 yrs. 9 mo.

WEIGHT

9.9 lbs

INTERPRETED BY

R. McKenzie Daniel, DVM, DABVP (Canine and Feline)

IMAGING PERFORMED BY

Dr. Ebersole

HOSPITAL NAME

Scanvet

REFERRING VET

Dr. McGarvey

INVOICE

15435

DATE

11/9/22

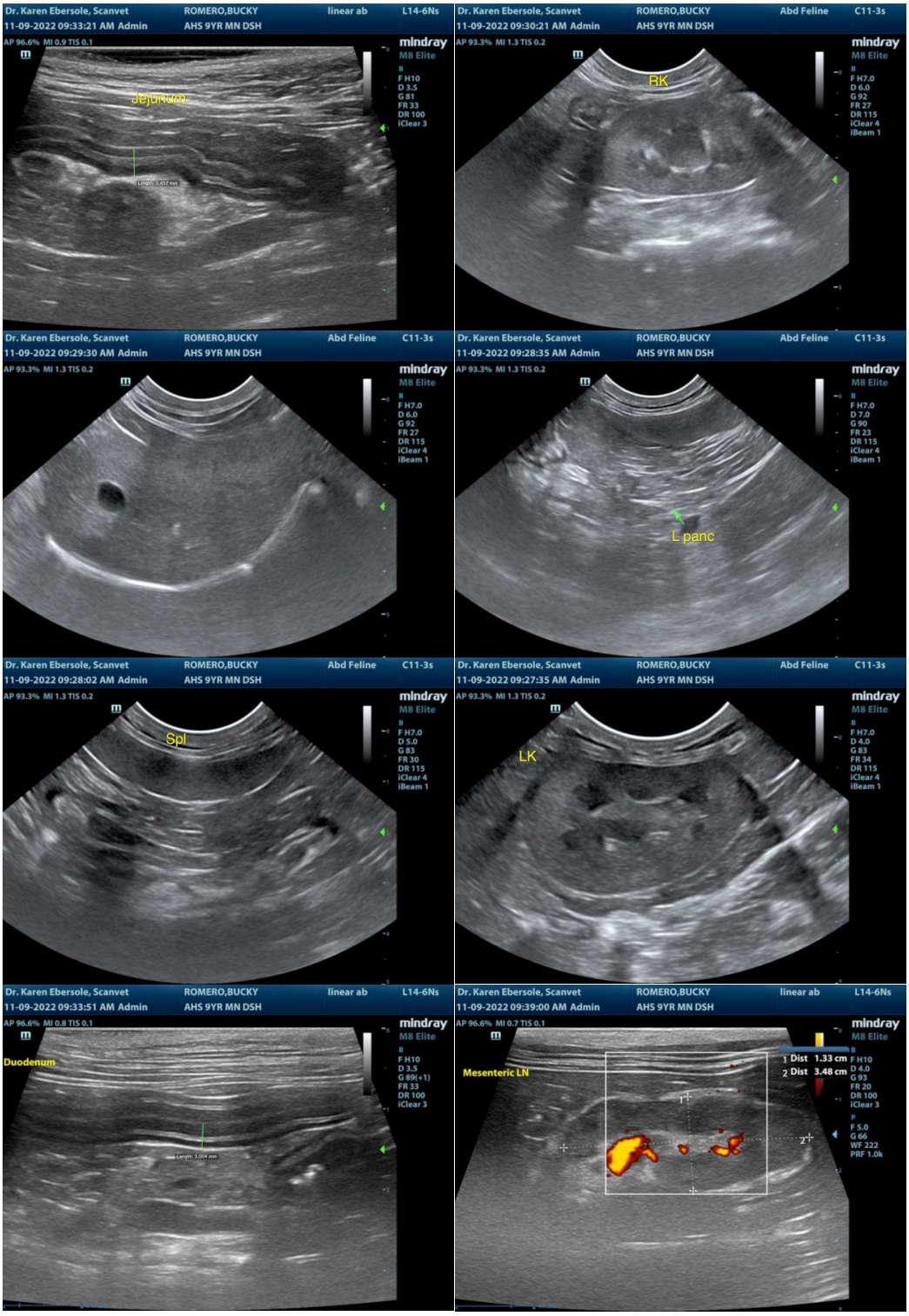

The information and recommendations provided are based on the images presented by the referring veterinarian/sonographer. No evaluation can be communicated regarding pathology that was not visible in the image/video clips provided.

SonoPath
Clinical Sonography & Telecytology

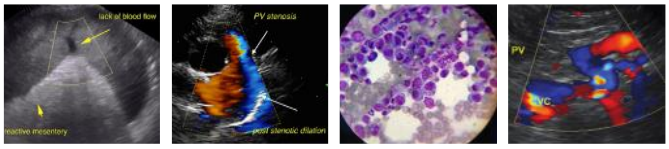

EDUCATIONAL TELECONSULTATION SERVICES™

SonoPath.com™
1-800-838-4268 info@sonopath.com

PATIENT

Bucky Romero

SPECIES

Feline

BREED

DSH

SEX

MN

AGE

9 yrs. 9 mo.

WEIGHT

9.9 lbs

INTERPRETED BY

R. McKenzie Daniel, DVM, DABVP (Canine and Feline)

IMAGING PERFORMED BY

Dr. Ebersole

HOSPITAL NAME

Scanvet

REFERRING VET

Dr. McGarvey

INVOICE

15435

DATE

11/9/22

Thank you for this referral. If the clinical or image interpretation does not parallel your findings or if I can be of any further assistance please contact me.

R. McKenzie Daniel, DVM, DABVP (Canine / Feline Practice)
info@SonoPath.com