

**PATIENT**

Merlot Tohill

SPECIES

Canine

BREED

Dachshund

SEX

FI

AGE

2yr

WEIGHT

6.3kg

INTERPRETED BYR. McKenzie Daniel,
DVM, DABVP
(Canine and Feline)**IMAGING
PERFORMED BY**

Dr. Meghan Myers

HOSPITAL NAMEHershey Animal
Emergency Center**REFERRING VET**

Dr. Victoria Orlando

INVOICE
22884**DATE**
11/8/2025**PRESENTING CLINICAL SIGNS**

presented to ER yesterday for lethargy, falling over, low temp, decreased appetite heat cycle end of sept. PE: Oral Cavity: Mucous membranes pale, dusty with slight icterus, minimal tartar/gingival erythema, sublingual clear Cardiovascular: No murmurs/arrhythmias, snappy pulses Integument: Inner pinna are icteric bilaterally.

Abnormal PE/Chem/CBC/UA Results: IMHA Problem List: Hypokalemia Regenerative anemia Leukocytosis with neutrophilia Agglutination: Macro +, micro + EPOC: pCO2 28.2 (L), BE -6.3 (L), K 2.8 (L), Lactate 6.25 (H), BG 153 (H), HCT <10 (L) CBC: RBC 1.04 (L), HCT 8.0 (L), HGB 2.4 (L), MCV 76.9 (H), MCHC 30.0 (L), Retic 252.9 (H), WBC 31.30 (H), Neut 23.17 (H), Lymph 5.55 (H), Mono 2.44 (H) Chem: Crea 0.3 (L), TBili 2.1 (H) Lepto Witness: neg 4Dx: Negative x 4

ULTRASONOGRAPHIC EXAMINATION OF THE ABDOMEN**Urinary System**

The urinary bladder, trigone, cystourethral junction, and visible pelvic urethra to a depth of 2 cm exhibited normal thickness and tone. Anechoic urine was present in the lumen with no evidence of urine/lumen sediment, mineral, or calculi. The ureteral papillae were normal. The ureters were not visible which is normal. No evidence of inflammatory or neoplastic changes was noted.

Normal size and margination were present in the kidneys. A normal 1:3 cortex / medulla ratio and normal corticomedullary definition were maintained. The echogenicity of the cortex was similar to or slightly less than normal liver parenchyma while the medulla echogenicity was hypoechoic to the cortex with no evidence of pelvic dilation. The left kidney measured 4.3 cm in length. The right kidney measured 4.5 cm in length.

The area of the aortic trifurcation was free of pathology.

The area of the uterus and bilateral ovaries appeared normal and free of pathology

Adrenal Glands

The left adrenal gland was uniform in size and contour with a uniformly hypoechoic parenchyma. The left adrenal gland measured 0.49 cm width at the caudal pole. The right adrenal gland was uniform in size and contour with a uniformly hypoechoic parenchyma. The right adrenal gland measured 0.55 cm width at the caudal pole.

Spleen

The spleen exhibited a finely textured and homogenous parenchyma which was hyperechoic to the liver and renal cortical parenchyma. The capsule was smooth and regular without apparent expansion. The splenic vasculature at the hilus was normal in volume with no evidence of congestion or thrombosis. Acute to chronic inflammatory, neoplastic, or benign parenchyma changes were not noted.

Liver/Gallbladder

The liver was subjectively normal in size, structure, and contour. The liver parenchyma was uniform and hypoechoic to the spleen with a mild coarse echotexture. Normal vascular volume. The hepatic and portal vasculature were normal in appearance without signs of congestion. The gallbladder was non-distended in size. The gallbladder wall was mildly thickened in appearance consisting of an echogenic double rim corresponding to the inner and outer portions of the wall. This is consistent with



PATIENT

Merlot Tohill

gallbladder wall edema. Possible causes may include acute inflammation, edema and anaphylaxis. The gallbladder wall measured 0.28 cm in width.

Gastrointestinal

SPECIES

Canine

The stomach presented intact wall layering with a normal wall layer ratio. The lumen of the stomach contained mild retained pyloric fluid with no signs of obstruction or foreign material.

BREED

Dachshund

The intestinal walls demonstrated intact wall layering and maintained 1:3 muscularis / mucosa ratio. The mucosa exhibited mild decreased echogenicity with occasional mucosal speckling. A segmental mild ileus pattern consisting of mild fluid accumulation in the intestinal lumen was present without obstruction or foreign material.

Normal visible colon wall layers were present with apparent formed feces in lumen.

SEX

Pancreas

FI

The parenchyma of the left limb, body and right limb of the pancreas presented isoechoic to the adjacent omental fat. A normal curvilinear capsule contour of the pancreas was present. The visible pancreatic duct was normal. No signs of active inflammation or neoplastic disease was evident.

AGE

2yr

Free Abdomen

No omental masses, overt lymphadenopathy or peritoneal effusion was present.

WEIGHT

6.3kg

ULTRASONOGRAPHIC FINDINGS

Primary

- Mild gastroenteritis pattern exhibiting mild nonobstructive pyloric and segmental jejunal ileus
- Mild gallbladder edema
- Normal uterus

INTERPRETED BY

R. McKenzie Daniel,
DVM, DABVP
(Canine and Feline)

INTERPRETATION OF THE FINDINGS & FURTHER RECOMMENDATIONS

No evidence of pathology as a definitive cause of the anemia. The gallbladder wall edema may suggest mild or emerging inflammation or anaphylaxis. Gastrointestinal support if GI signs are nonreported or arise. Screening thoracic / abdominal radiographs may be considered if not done.

IMAGING PERFORMED BY

Dr. Meghan Myers

HOSPITAL NAME

Hershey Animal
Emergency Center

REFERRING VET

Dr. Victoria Orlando

INVOICE

22884

DATE

11/8/2025



PATIENT

Merlot Tohill

SPECIES

Canine

BREED

Dachshund

SEX

FI

AGE

2yr

WEIGHT

6.3kg

INTERPRETED BY

R. McKenzie Daniel,
DVM, DABVP
(Canine and Feline)

IMAGING PERFORMED BY

Dr. Meghan Myers

HOSPITAL NAME

Hershey Animal
Emergency Center

REFERRING VET

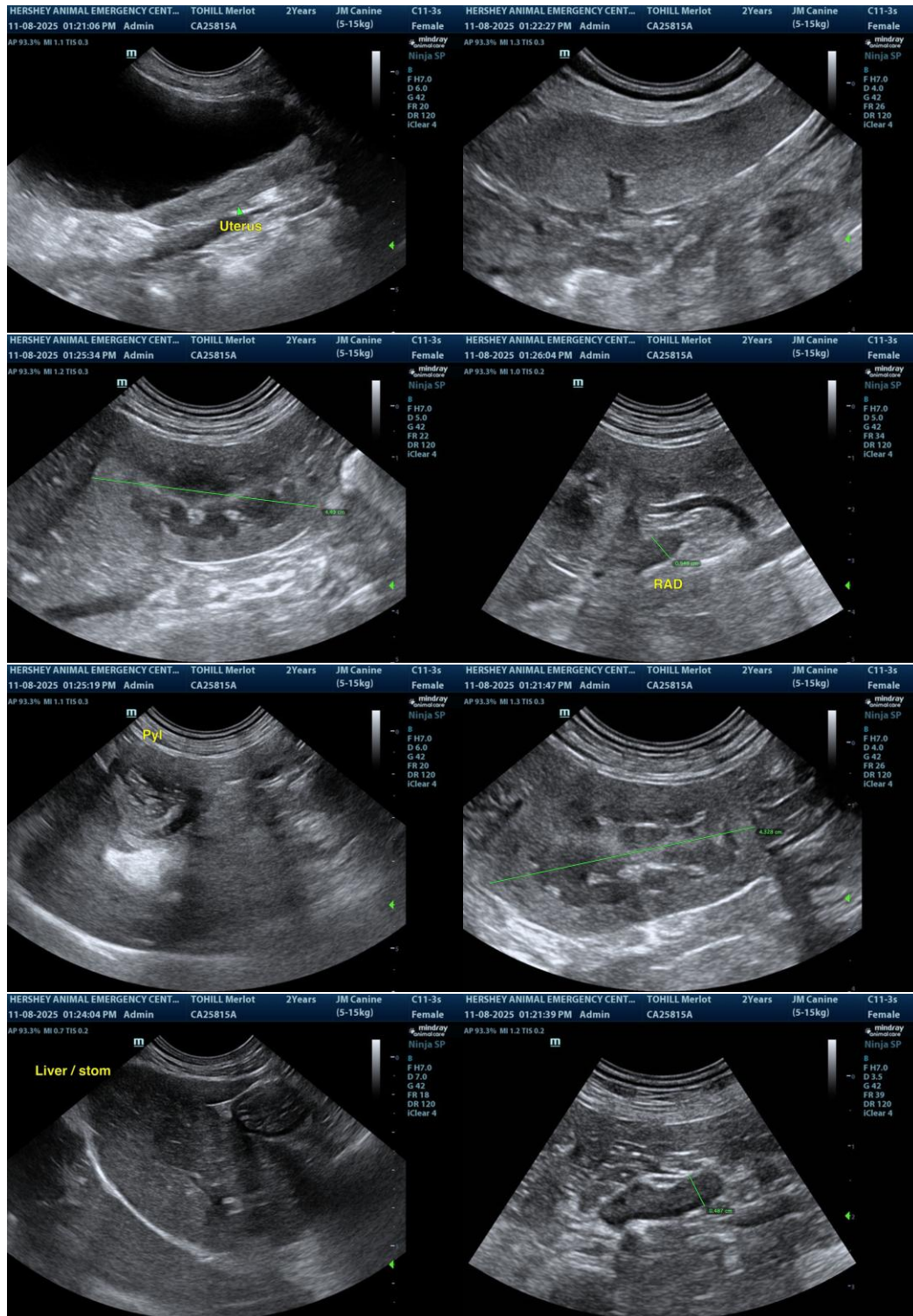
Dr. Victoria Orlando

INVOICE

22884

DATE

11/8/2025





PATIENT

Merlot Tohill

SPECIES

Canine

BREED

Dachshund

SEX

FI

AGE

2yr

WEIGHT

6.3kg

INTERPRETED BY

R. McKenzie Daniel,
DVM, DABVP
(Canine and Feline)

IMAGING PERFORMED BY

Dr. Meghan Myers

HOSPITAL NAME

Hershey Animal
Emergency Center

REFERRING VET

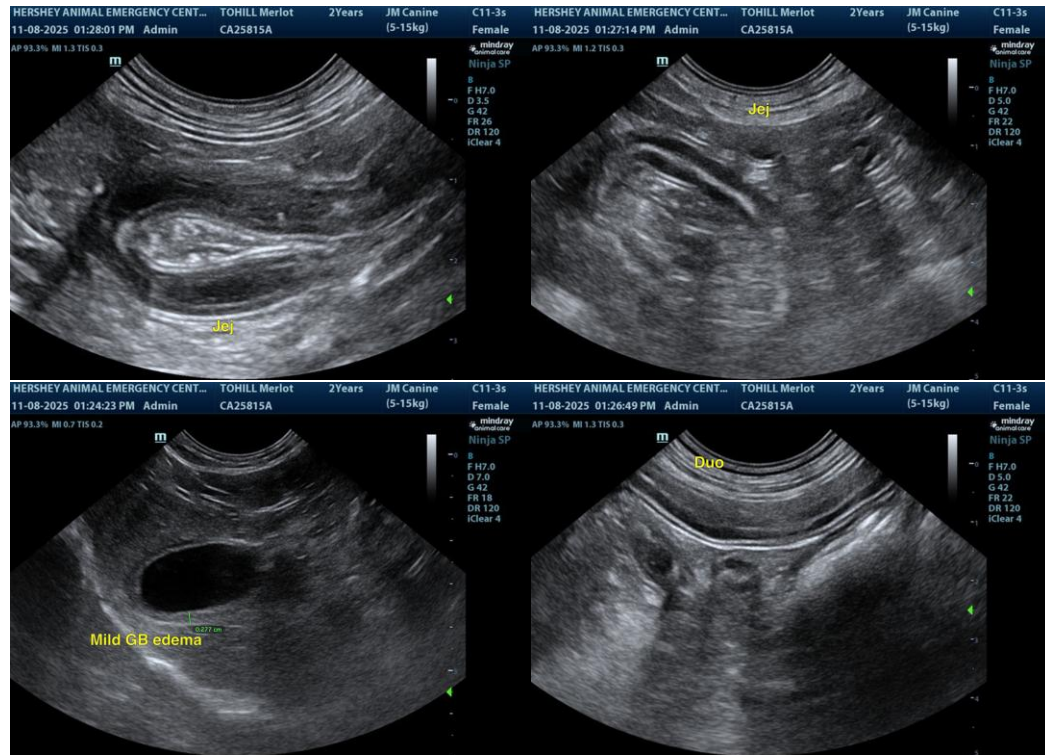
Dr. Victoria Orlando

INVOICE

22884

DATE

11/8/2025



The information and recommendations provided are based on the images presented by the referring veterinarian/sonographer. No evaluation can be communicated regarding pathology that was not visible in the image/video clips provided.

Thank you for this referral. If the clinical or image interpretation does not parallel your findings or if I can be of any further assistance, please contact me.

R. McKenzie Daniel, DVM, DABVP (Canine/Feline Practice)
info@sonopath.com