



PATIENT

Yoshi Nicolay

SPECIES

Canine

BREED

Japanese Chin

SEX

M/N

AGE

10 years 10 months

WEIGHT

5.44 jgs.

INTERPRETED BY

R. McKenzie Daniel,
DVM, DABVP
(Canine and Feline)

IMAGING PERFORMED BY

Dr. Meredith Swart

HOSPITAL NAME

Swart Veterinary
Imaging

REFERRING VET

Dr. Meredith Swart

INVOICE

15419

DATE

11/8/22

PRESENTING CLINICAL SIGNS

Grade II soft left side murmur. No clinical signs of CHF. Echo is pre-operative prior to patients yearly dental cleaning.

Abnormal PE/Chem/CBC/UA Results: none reported

ULTRASONOGRAPHIC EXAMINATION OF THE HEART

CANINE	MR	TR	LA/AO	LA/AO	FS	EF	EPSS
CARDIAC PARAMETERS	VMAX (m/s)	VMAX (m/s)	(Boon method)	(Heart Base; Swe)	(%)	(%)	(cm)
NORMAL PARAMETER	4.5-5.5	<2.7	1.3	<1.3	28-40	40-100	<0.6
PATIENT				1.3	47.2	80	0.21
CANINE	HR	AV	PV	BODY WEIGHT	LA	LVIDd	LVIDs
CARDIAC PARAMETERS	(BPM)	VMAX (m/s)	MAX (m/s)	(kg)	2D short axis Base view (cm)	Avg; 2D and m-mode short axis (cm)	Avg; 2D and m-mode short axis (cm)
NORMAL PARAMETER	50-100	0.7-1.7	0.7-1.6				
PATIENT	NM	1.0	0.8		2.5	2.5	

Cardiac Presentation

The echocardiogram in this patient demonstrated normal **left atrial** size based on 3 different LA measurement methods. Chamber volumes and echogenicity were normal. The cranial and caudal **mitral** valve leaflets presented mild thickening consistent with mild endocardiosis. Doppler indicated mild eccentric insufficiency. The **left ventricle** presented thicknesses with linear contour and was not dilated nor restricted. The **myocardium** presented normal echogenicity without subjective evidence of significant fibrotic or ischemic disease. **Contractility** of the ventricular walls was adequate and in normal range for this patient evidenced by the fractional shortening measurement and subjective evaluation of the different regions of the myocardium. The **left ventricular outflow** tract demonstrated normal laminar flow and subjective structural integrity. The **right atrium** and auricle revealed normal size, structure and content. No evidence of masses was noted or chamber overload. **Tricuspid** valvular assessment demonstrated adequate linear morphology. The **right ventricle** was of normal size (1/3 diameter of LV), chordae structure, myocardial echogenicity and thickness. **Pulmonic** tract assessment revealed normal valve structure, laminar flow, and diameter (approx. 1:1 pa/ao ratio). Minor pulmonic insufficiency was present on Doppler. No visible **pericardial** or free pleura fluid was noted. No echographically detectable evidence of infiltrative disease was visible. The cranial **mediastinum and pericardial regions** were free of masses in the visible window.



PATIENT

Yoshi Nicolay

SPECIES

Canine

BREED

Japanese Chin

SEX

M/N

AGE

10 years 10 months

WEIGHT

5.44 jgs.

ULTRASONOGRAPHIC FINDINGS

- Chronic mitral valve disease (ACVIM B1)
- Minor pulmonic insufficiency

INTERPRETATION OF THE FINDINGS & FURTHER RECOMMENDATIONS

The cause of the murmur is most consistent with mild chronic degenerative valvular changes with secondary mild eccentric mitral valve insufficiency. No other clinical issues such as LV systolic dysfunction or evidence of clinical pulmonary hypertension. The normal left atrium size indicates that the risk of current and future complication secondary to mitral valve insufficiency is low.

In a nonclinical patient without evidence of chamber enlargement, cardiac medications are not indicated. No anesthetic contraindications. The following anesthetic protocol is recommended. Serial sonographic monitoring is required for further prognosis. Recheck echocardiogram is recommended in 6-12 months, sooner if clinical signs arise.

Suggested anesthetic protocol may include opioid or Benzodiazepine pre-med, induction with Propofol or Alfaxalone, and appropriate gas anesthesia with avoidance of alpha 2 agonists.

INTERPRETED BY

R. McKenzie Daniel,
DVM, DABVP
(Canine and Feline)

IMAGING PERFORMED BY

Dr. Meredith Swart

HOSPITAL NAME

Swart Veterinary
Imaging

REFERRING VET

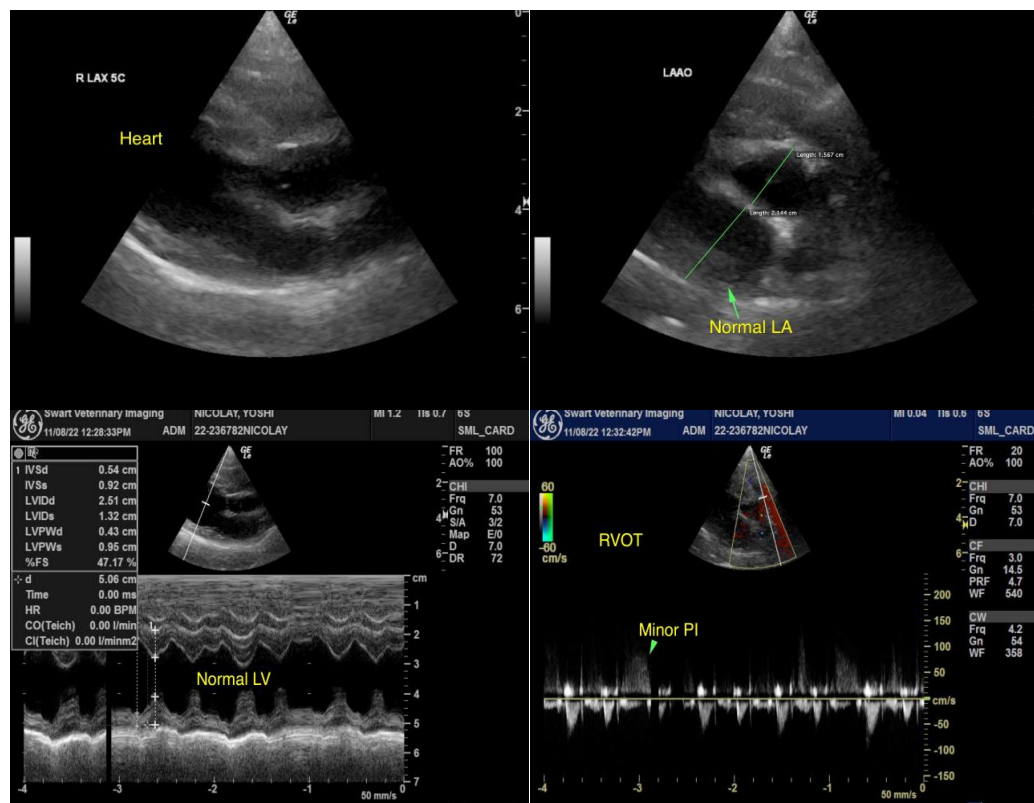
Dr. Meredith Swart

INVOICE

15419

DATE

11/8/22





PATIENT

Yoshi Nicolay

SPECIES

Canine

BREED

Japanese Chin

SEX

M/N

AGE

10 years 10 months

WEIGHT

5.44 jgs.

INTERPRETED BY

R. McKenzie Daniel,
DVM, DABVP
(Canine and Feline)

**IMAGING
PERFORMED BY**

Dr. Meredith Swart

HOSPITAL NAME

Swart Veterinary
Imaging

REFERRING VET

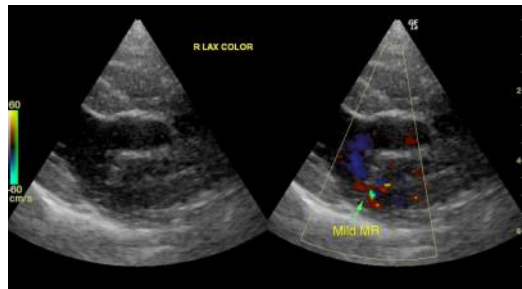
Dr. Meredith Swart

INVOICE

15419

DATE

11/8/22



The information and recommendations provided are based on the images presented by the referring veterinarian/sonographer. No evaluation can be communicated regarding pathology that was not visible in the image/video clips provided.

Thank you for this referral. If the clinical or image interpretation does not parallel your findings or if I can be of any further assistance please contact me.

R. McKenzie Daniel, DVM, DABVP (Canine / Feline Practice)
info@SonoPath.com