



## PATIENT

Bessie Cherry

## SPECIES

Feline

## BREED

DSH

## SEX

FS

## AGE

15 y 6 m

## WEIGHT

7.1 lbs.

## INTERPRETED BY

R. McKenzie Daniel,  
DVM, DABVP  
(Canine and Feline)

## IMAGING PERFORMED BY

Shari Reffi, CVT

## HOSPITAL NAME

Budd Lake AH

## REFERRING VET

Dr. Horn

## INVOICE

15417

## DATE

11/8/22

## PRESENTING CLINICAL SIGNS

Not eating, vomiting. Possible mass in left lung lobe (caudal segment)/mild pleural eff. (rad report attached). Current meds: Cerenia, oral mirtazapine-ate well yesterday

Abnormal PE/Chem/CBC/UA Results: wnl

## ULTRASONOGRAPHIC EXAMINATION OF THE HEART & ABDOMEN

FELINE CARDIAC PARAMETERS	BODY WEIGHT (kg)	HR (BPM)	IVSd (cm)	LVIDd (cm)	LVWd (cm)	FS (%)	EF (%)
NORMAL PARAMETER	-----	150-240	0.3-0.6	1.0-2.1	0.25-0.6	35-67	80-100
PATIENT		187	0.34	1.45	0.33	45.7	80.6
FELINE CARDIAC PARAMETERS	LA/AO (Boon)	LA/AO HEART BASE (Sisson)	LA 2D 4-chamber long axis AS to FW (Sisson) (cm)	LVOT VEL. (m/s)	RVOT VEL. (m/s)	IVRT (m/)	
NORMAL PARAMETER	<1.5	0.88-1.79	0.7-1.7	<1.6	<1.3	40-60	
PATIENT		1.2	1.2	1.0	0.7	NM	
Adapted from June Boon, Veterinary Echocardiography, 1998							
Sisson D et al. JVIM 1991; 5: 232, Jacobs et al. Am J Vet Res 1985; 46:1705							

## Cardiac Presentation

The echocardiogram in this patient demonstrated normal **left atrial** size based on 3 separate LA measurements. The cranial and caudal **mitral** valve leaflets presented normal linear structure and kinetics. The **left ventricle** presented normal thicknesses with mild alinear myocardial contour and was not dilated nor restricted. The **myocardium** presented overall normal echogenicity with evidence of minor myocardial remodeling, yet no evidence of significant fibrotic or ischemic disease.

**Contractility** of the ventricular walls was adequate and in normal range for this patient evidenced by the fractional shortening measurement and subjective evaluation of the different regions and angles of the myocardium. The **left ventricular outflow** tract demonstrated normal laminar flow and subjective structural integrity. The **right atrium** and auricle revealed normal size, structure and content. No evidence of masses was noted or chamber overload. **Tricuspid** valvular assessment demonstrated adequate linear morphology and kinetics. The **right ventricle** was of normal size (1/3 diameter of LV), chordae structure, myocardial echogenicity and thickness. **Pulmonic** tract assessment revealed normal valve structure, laminar flow, and diameter (approx. 1:1 pa/ao ratio). No visible **pericardial** free fluid was noted. Minor volume free pleural fluid was present primarily in the mid-thorax and pericardial regions. Ill-defined nonhomogeneous to echogenic lung tissue was in the pericardial regions primarily within the subjective left thorax. The abnormal lung appeared to be nonaerated and potentially avascular, although vascularity assessment is subjective. No overt



**PATIENT**

Bessie Cherry

evidence of air entrapment or obvious mineralization within the atypical lung. The area of atypical lung potentially measured 3.0-4.0 cm in diameter.

**SPECIES**

Feline

**Urinary System**

The urinary bladder, trigone, cystourethral junction, and visible pelvic urethra to a depth of 2.0 cm exhibited normal thickness and tone. Primarily anechoic urine was present in the lumen. Mild, nondependent, particulate sediment, which may indicate cellular debris / protein, crystalline debris, lipid or mucus, was present without evidence of calculus formation. The ureteral papillae were normal. The ureters were not visible which is normal. No evidence of inflammatory or neoplastic mural changes were noted.

**BREED**

DSH

**SEX**

FS

The area of the aortic trifurcation was free of pathology.

**AGE**

15 y 6 m

Normal size and margination were present in the kidneys. A normal 1:3 cortex / medulla ratio was maintained. The medulla and cortices were uniform in texture with some increased echogenicity and mild to moderate loss of corticomedullary symmetry and definition expected for the age of the patient. Pinpoint medullary mineral was noted. No evidence of pelvic dilation was present. The left kidney measured 3.0 cm in length. The right kidney measured 3.2 cm in length.

**WEIGHT**

7.1 lbs.

**Adrenal Glands**

No overt pathology was noted in the area of the left or right adrenal glands.

**INTERPRETED BY**

R. McKenzie Daniel,  
DVM, DABVP  
(Canine and Feline)

**Spleen**

The spleen exhibited a finely textured and homogenous parenchyma which was hyperechoic to the liver and renal cortical parenchyma. The capsule was smooth and regular without apparent expansion. The splenic vasculature at the hilus was normal in volume with no evidence of congestion or thrombosis. Acute to chronic inflammatory, neoplastic, or benign parenchyma changes were not noted. The spleen measured 0.65 cm width at the level of the hilus.

**IMAGING PERFORMED BY**

Shari Reffi, CVT

**Liver/ Gallbladder**

**HOSPITAL NAME**

Budd Lake AH

The liver was subjectively normal in size, structure, and contour. The liver parenchyma was uniform and hypoechoic to the spleen with a mild coarse echotexture. The hepatic and portal vasculature were normal in appearance without signs of hepatic congestive criteria. The gallbladder was non-distended in size containing primarily anechoic content with minor particulate sludge. No evidence of gallbladder or peripheral gallbladder inflammatory criteria was noted. The gallbladder debris is likely incidental given the lack of cholestasis. The cystic and common bile ducts were normal.

**REFERRING VET**

Dr. Horn

**INVOICE**

15417

Transdiaphragmatic view revealed focal to mild comet tail lung pattern, which is echogenic sound wave interface with microconsolidations within the caudal lung field. The lung field should not be visualized by sonogram unless pathology is present. Chest radiographs are recommended to rule out alveolar/lung disease such as neoplasia, thromboembolic disease, chronic inflammatory disease with microconsolidation.

**DATE**

11/8/22



**PATIENT**

***Gastrointestinal***

Bessie Cherry

The stomach presented intact wall layering with a normal wall layer ratio. The lumen of the stomach was empty with no signs of ileus, obstruction, or foreign material. The gastric body wall width measured 0.24cm.

**SPECIES**

Feline

The small intestine presented intact wall layering without evidence of mural hypertrophy or loss of intestinal wall layering, yet subjective propensity for segmental mildly prominent muscularis layer.

**BREED**

DSH

Normal visible colon wall layers were present with apparent formed feces in lumen.

**SEX**

FS

***Pancreas***

The pancreas exhibited mild prominent size with minor capsule asymmetry. Subtle hypoechoic parenchyma compared to adjacent omentum.

**AGE**

15 y 6 m

***Free Abdomen***

Focal to intermittent, subtly prominent, mesenteric nodes were present, not consistent with inflammatory or neoplastic criteria. The lymph nodes were essentially isoechoic to adjacent omentum without evidence of peripheral inflammation and maintaining a normal width: length ratio (<0.5). No peritoneal free fluid or omental masses were present.

**WEIGHT**

7.1 lbs.

**INTERPRETED BY**

R. McKenzie Daniel,  
DVM, DABVP  
(Canine and Feline)

**ULTRASONOGRAPHIC FINDINGS**

- Normal echocardiogram with minor LV remodeling
- Nonuniform nonaerated left and pericardial lung, concurrent minor volume noncardiogenic pleural effusion - atelectasis, consolidation, chronic inflammatory infectious granulomatous / pyogranulomatous disease, neoplasia, or other
- Mild urinary bladder sediment
- Bilateral chronic renal changes with pinpoint medullary mineral
- Subjective mild segmental to generalized inflammatory enteropathy pattern
- Possible low-grade pancreatitis
- Focal to mild transdiaphragmatic comet tail artifact

**IMAGING**

**PERFORMED BY**

Shari Reffi, CVT

**HOSPITAL NAME**

Budd Lake AH

**REFERRING VET**

Dr. Horn

**INTERPRETATION OF THE FINDINGS & FURTHER RECOMMENDATIONS**

Assuming normal clotting status, FNA cytology of the atypical lung for further assessment +/- C/S if clinically indicated could be considered.

**INVOICE**

15417

The degree of effusion likely precluded effusion analysis at this time.

**DATE**

11/8/22

Urine C/S is recommended if evidence of inflammatory urinary bladder sediment.

Although potential for patient variant, the small intestine exhibited subtle mural changes which may suggest underlying inflammatory criteria, i.e., enteritis / IBD. A GI panel to include PLI/TLI/Cobalamin/Folate is recommended.



**PATIENT**

Bessie Cherry

**SPECIES**

Feline

**BREED**

DSH

**SEX**

FS

**AGE**

15 y 6 m

**WEIGHT**

7.1 lbs.

**INTERPRETED BY**

R. McKenzie Daniel,  
DVM, DABVP  
(Canine and Feline)

**IMAGING PERFORMED BY**

Shari Reffi, CVT

**HOSPITAL NAME**

Budd Lake AH

**REFERRING VET**

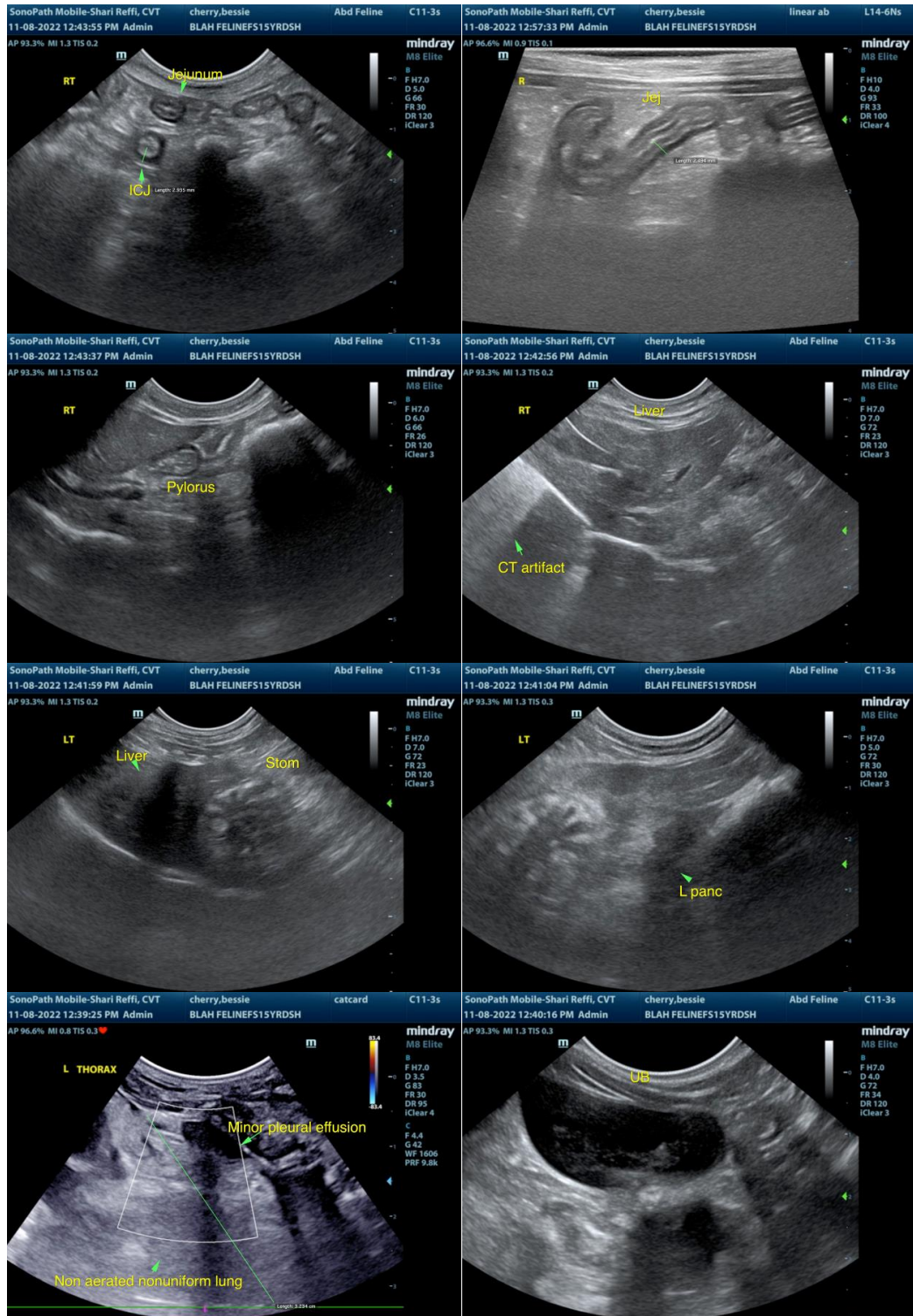
Dr. Horn

**INVOICE**

15417

**DATE**

11/8/22





## PATIENT

Bessie Cherry

## SPECIES

Feline

## BREED

DSH

## SEX

FS

## AGE

15 y 6 m

## WEIGHT

7.1 lbs.

## INTERPRETED BY

R. McKenzie Daniel,  
DVM, DABVP  
(Canine and Feline)

## IMAGING PERFORMED BY

Shari Reffi, CVT

## HOSPITAL NAME

Budd Lake AH

## REFERRING VET

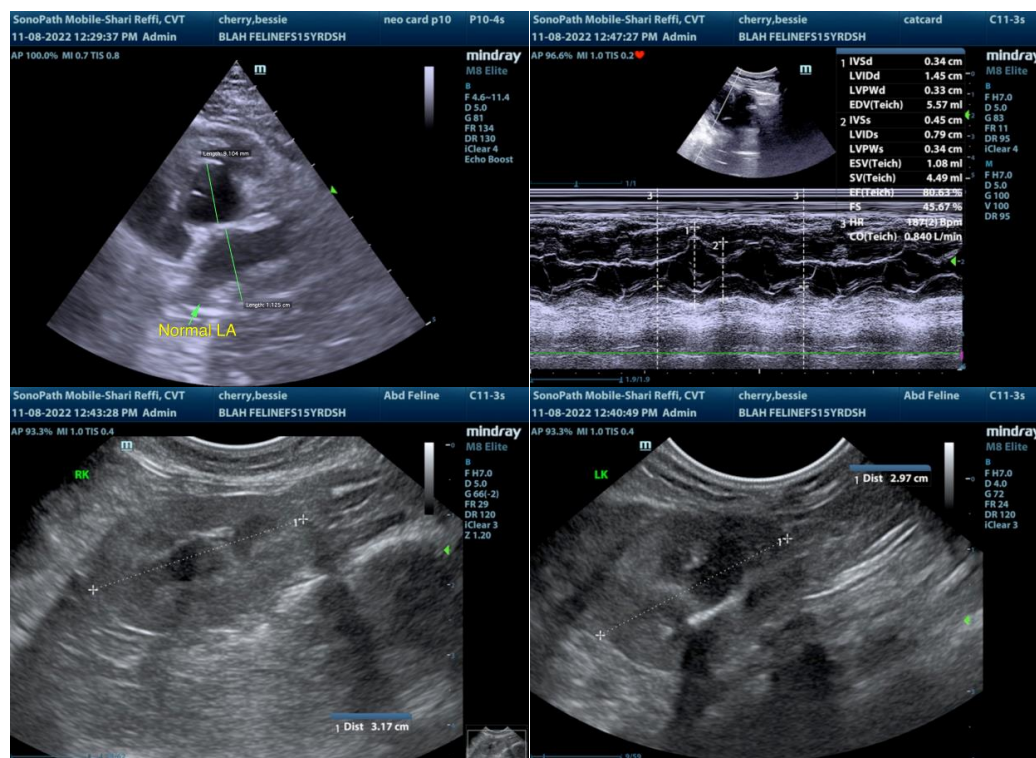
Dr. Horn

## INVOICE

15417

## DATE

11/8/22



The information and recommendations provided are based on the images presented by the referring veterinarian/sonographer. No evaluation can be communicated regarding pathology that was not visible in the image/video clips provided.

Thank you for this referral. If the clinical or image interpretation does not parallel your findings or if I can be of any further assistance please contact me.

R. McKenzie Daniel, DVM, DABVP (Canine / Feline Practice)  
info@SonoPath.com