



PATIENT

Harmony Simms

PRESENTING CLINICAL SIGNS

chronic vag d/c previous vet cultured on several antibiotic d/c continues

SPECIES

Canine

ULTRASONOGRAPHIC EXAMINATION OF THE ABDOMEN

Urinary System

The urinary bladder, trigone, cystourethral junction, and visible pelvic urethra to a depth of 5.0 cm exhibited normal thickness and tone. Anechoic urine was present in the lumen with no uroliths or sediment. The ureteral papillae were normal. The ureters were not visible which is normal. No evidence of inflammatory or neoplastic changes were noted.

BREED

Lab X

No evidence of pathology in the area of the uterine stump.

SEX

Spayed Female

The area of the aortic trifurcation was free of pathology.

AGE

12 Years

Normal size and margination were present in the kidneys. A normal 1:3 cortex / medulla ratio was maintained. The medulla and cortices were uniform in texture with some increased echogenicity and loss of corticomedullary symmetry and definition expected for the age of the patient. No evidence of pelvic dilation was present. The right kidney measured 6.5 cm. The left kidney measured 6.0 cm.

WEIGHT

79.5 Pounds

Adrenal Glands

A focal, well defined, hyperechoic nodule was present in the cranial pole of the left adrenal gland, non-expansive. The nodule measured 1.0 cm x 0.77 cm. Overall left adrenal gland measured 2.8 cm length x 0.64 cm at the caudal pole. The nodule did not exhibit signs of mineralization or vascular invasion. This is likely suggestive of a benign process such as adenoma, granuloma or myelolipoma if no clinical signs of adrenal disease are currently present. Potential emerging aggressive neoplasia cannot be ruled out. Therefore, recheck ultrasound every 3-6 months is suggested to monitor for changes in size or appearance. A screening blood pressure is suggested.

INTERPRETED BY

R. McKenzie Daniel,
DVM, DABVP
(Canine and Feline)

The adrenal glands were uniform in size and contour with a uniformly hypoechoic parenchyma. The right adrenal gland measured 2.5 cm length x 0.74 cm at the caudal pole.

IMAGING PERFORMED BY

Jenn

Spleen

The spleen exhibited a finely textured and homogenous parenchyma which was hyperechoic to the liver and renal cortical parenchyma. The capsule was smooth and regular without apparent expansion. The splenic vasculature at the hilus was normal in volume with no evidence of congestion or thrombosis. Acute to chronic inflammatory, neoplastic, or benign parenchyma changes were not noted.

HOSPITAL NAME

Rockaway AH

Liver

The liver was subjectively normal in size, structure, and contour. The liver parenchyma was mildly nonuniform and hypoechoic to the spleen with a moderate coarse echotexture and subjective mild to benign parenchymal remodeling. The hepatic and portal vasculature were normal in appearance without signs of congestion. The gallbladder was non distended in size with mild to moderate, non-dependent yet non-organized echogenic debris. The cystic duct and common bile ducts were normal without evidence of dilation.

REFERRING VET

Dr. Maniar

INVOICE

26929

Gastrointestinal

DATE

11/8/21

The stomach presented intact wall layering with a normal wall layer ratio. The lumen of the stomach contained mild to moderate echogenic, nonshadowing ingesta with luminal gas.



PATIENT

Harmony Simms

The small intestine presented intact wall layering with 1:3 muscularis/mucosa ratio. The lumen of the small intestine was empty with no signs of ileus, obstruction or foreign material.

Normal visible colon wall layers were present with apparent formed feces in lumen.

SPECIES

Canine

Pancreas

The parenchyma of the left limb, body and right limb of the pancreas presented isoechoic to the adjacent omental fat. A normal curvilinear capsule contour of the pancreas was present. The visible pancreatic duct was normal. No signs of active inflammation or neoplastic disease was evident.

BREED

Lab X

Free Abdomen

No overt lymphadenopathy or peritoneal effusion was present.

SEX

Spayed Female

ULTRASONOGRAPHIC FINDINGS

AGE

12 Years

- Sonographically unremarkable urinary bladder and visible proximal urethra. No overt pathology in the area of the uterine stump.
- Left adrenal nodule – suspect adenoma
- Mild benign hepatic parenchymal remodeling
- Mild to moderate gallbladder debris (non-mucocele)
- Bilateral mild chronic renal changes

WEIGHT

79.5 Pounds

INTERPRETATION OF THE FINDINGS & FURTHER RECOMMENDATIONS

Overall mild geriatric abdomen without evidence of significant visceral pathology. Minor potential for emerging left adrenal neoplasia such as pheochromocytoma or adenocarcinoma possible, yet thought less likely. However, sonographic monitoring of the left adrenal gland for evidence of progressive changes in the cranial nodule recommended. Screening blood pressure recommended. Ursodiol may be considered if evidence of cholestasis. No evidence of uterine stump pathology or stump pyometra.

INTERPRETED BY

R. McKenzie Daniel,
DVM, DABVP
(Canine and Feline)

IMAGING PERFORMED BY

Jenn

HOSPITAL NAME

Rockaway AH

REFERRING VET

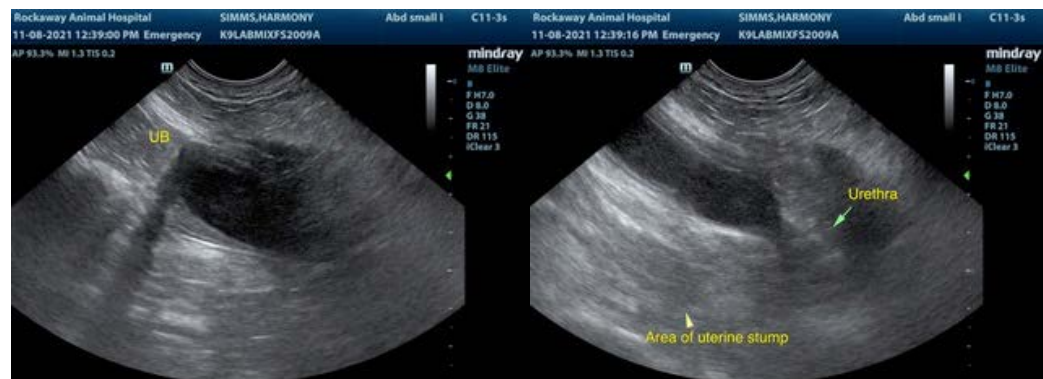Dr. Maniar

INVOICE

26929

DATE

11/8/21





PATIENT

Harmony Simms

SPECIES

Canine

BREED

Lab X

SEX

Spayed Female

AGE

12 Years

WEIGHT

79.5 Pounds

INTERPRETED BY

R. McKenzie Daniel,
DVM, DABVP
(Canine and Feline)

IMAGING PERFORMED BY

Jenn

HOSPITAL NAME

Rockaway AH

REFERRING VET

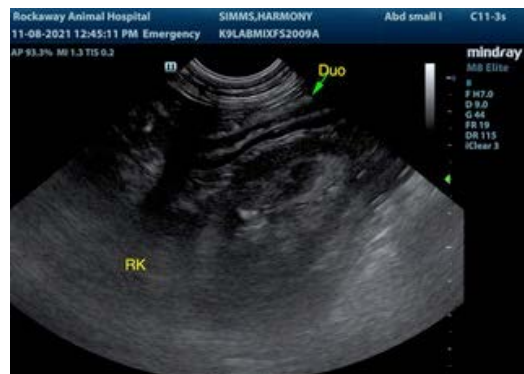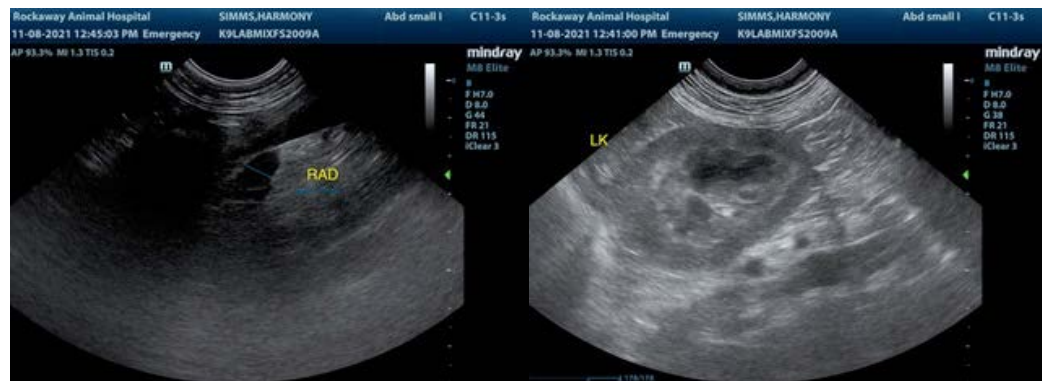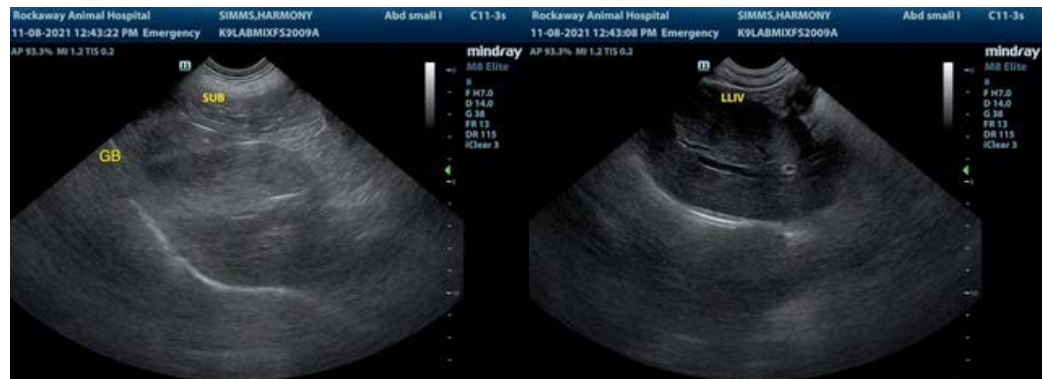
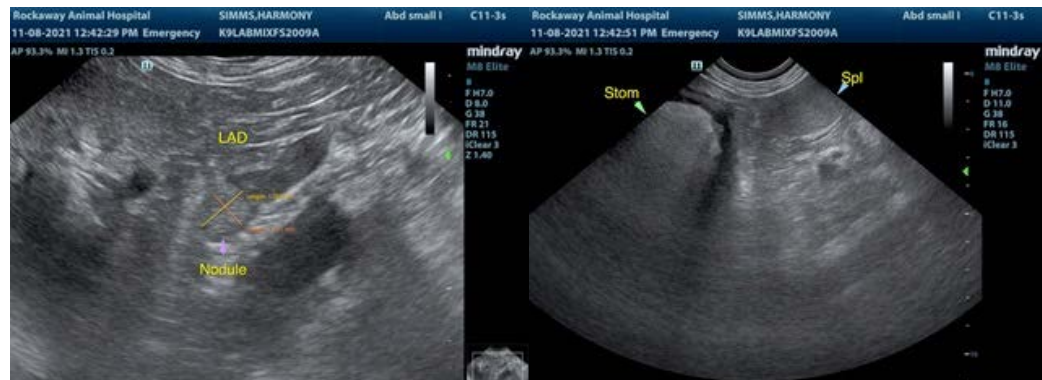Dr. Maniar

INVOICE

26929

DATE

11/8/21





PATIENT

Harmony Simms

The information and recommendations provided are based on the images presented by the referring veterinarian. No evaluation can be communicated regarding pathology that was not visible in the image/video clips provided.

SPECIES

Canine

Thank you for this referral. If the clinical or image interpretation does not parallel your findings or if I can be of any further assistance please contact me.

BREED

Lab X

R. McKenzie Daniel, DVM, DABVP (Canine / Feline Practice)
info@SonoPath.com

SEX

Spayed Female

AGE

12 Years

WEIGHT

79.5 Pounds

INTERPRETED BY

R. McKenzie Daniel,
DVM, DABVP
(Canine and Feline)

**IMAGING
PERFORMED BY**

Jenn

HOSPITAL NAME

Rockaway AH

REFERRING VET

Dr. Maniar

INVOICE

26929

DATE

11/8/21