

**PATIENT**

Tessa Spiron

SPECIES

Canine

BREED

PitBull Terrier

SEX

FS

AGE

14yr

WEIGHT

25.3kg

INTERPRETED BYR. McKenzie Daniel,
DVM, DABVP
(Canine and Feline)**IMAGING
PERFORMED BY**

Renee Trionfetti, VMD

HOSPITAL NAMECypress Veterinary
Clinic**REFERRING VET**

Laura Johnson, VMD

**INVOICE
22874****DATE**
11/07/2025**PRESENTING CLINICAL SIGNS**

AUS to further evaluate hyperglobulinemia, hypoalbuminemia, proteinuria (UPC 2.9). Has hx of proteinuria. PMH: Hypercalcemia, hyperparathyroidism last year. Was taken to a specialist who injected tumor with ethanol. Normal calcium levels at currently.

Abnormal PE/Chem/CBC/UA Results: - Chem: TP 9.3 H, Alb 2.4 L, Glob 6.9 H, A: 0.3, creat kinase 249H; SDMA 14- high-normal. Cr 1.0-n, BUN 19-n. Normal LES. Ca 10.2-n, Phos 2.7-n, Chol 201-n - T4 1.6 - n - CBC: Hct 47.9%-n, Mild changes - WBC 5.0 L, Lymphs 0.955 L, Mono 0.145 L, Eos 0.11 L, Plts 185-n - UA 1.040, pH 7.5, 4+ protein, trace ketones w/ neg glucose, 1+ bili, 1+ struvites - UPC 2.9 - proteinuric

ULTRASONOGRAPHIC EXAMINATION OF THE ABDOMEN WITH LIMITED CARDIAC**Urinary System**

The urinary bladder, trigone, cystourethral junction, and visible pelvic urethra to a depth of 3 cm exhibited normal thickness and tone. Anechoic urine was present in the lumen with no evidence of urine/lumen sediment, mineral, or calculi. The ureteral papillae were normal. The ureters were not visible which is normal. No evidence of inflammatory or neoplastic changes was noted.

Normal size and margination were present in the kidneys. A normal 1:3 cortex / medulla ratio was maintained. The medulla and cortices were uniform in texture with some increased echogenicity and mild loss of corticomedullary symmetry and definition expected for the age of the patient. No evidence of pelvic dilation was present. Small medial left kidney cortical cysts were present. The left kidney measured 6.3 cm in length. The right kidney measured 6.7 cm in length.

The area of the aortic trifurcation was free of pathology.

Adrenal Glands

The left adrenal gland was uniform in size and contour with a uniformly hypoechoic parenchyma. The left adrenal gland measured 0.71 cm width at the caudal pole. The right adrenal gland was uniform in size and contour with a uniformly hypoechoic parenchyma. The right adrenal gland measured 0.54 cm width at the caudal pole.

Spleen

The spleen exhibited subjective mild enlargement with maintained symmetrical capsule contour and overall homogenous parenchyma. A solitary mildly expansive non-homogenous hypoechoic mid-splenic nodule was present without associated capsule distortion measuring 2.7 cm in diameter.

Liver/Gallbladder

The liver was subjectively normal in size, structure, and contour. The liver parenchyma was uniform and hypoechoic to the spleen with a mild coarse echotexture. Normal vascular volume. The hepatic and portal vasculature were normal in appearance without signs of congestion. The gallbladder was non-distended in size with thin walls and primarily anechoic luminal content. The cystic and common bile ducts were normal.

Gastrointestinal

The stomach presented intact wall layering with a normal wall layer ratio. The lumen of the stomach was empty with no signs of ileus, obstruction or foreign material.



PATIENT

Tessa Spiron

The small intestine presented intact wall layering with 1:3 muscularis/mucosa ratio. The lumen of the small intestine was empty with no signs of mechanical/metabolic ileus, obstruction or foreign material.

Normal visible colon wall layers were present with apparent formed feces in lumen.

SPECIES

Canine

Pancreas

The parenchyma of the left limb, body and right limb of the pancreas presented isoechoic to the adjacent omental fat. A normal curvilinear capsule contour of the pancreas was present. The visible pancreatic duct was normal. No signs of active inflammation or neoplastic disease was evident.

BREED

PitBull Terrier

Free Abdomen/Cardiac

No omental masses, overt lymphadenopathy or peritoneal effusion was present.

SEX

FS

Rapid view of the heart revealed no evidence of pericardial masses or effusion in the visible window. Subjective normal overall cardiac structure and function. No evidence of arrhythmia.

ULTRASONOGRAPHIC FINDINGS

AGE

14yr

Primary

- Mild splenomegaly with mildly expansive splenic nodule- hyperplasia, hematopoiesis, inflammation, emerging primary or metastatic neoplasia possible
- Non-specific mild chronic renal changes
- Normal bilateral adrenal glands
- Subjective normal cardiac structure / function

WEIGHT

25.3kg

INTERPRETATION OF THE FINDINGS & FURTHER RECOMMENDATIONS

Assuming normal clotting status and using a 25g needle, a splenic parenchyma and nodule FNA for screening cytology is warranted for further assessment. Protein losing nephropathy therapy warranted if persistent UPC without evidence of inflammatory sediment.

INTERPRETED BY

R. McKenzie Daniel,
DVM, DABVP
(Canine and Feline)

IMAGING PERFORMED BY

Renee Trionfetti, VMD

HOSPITAL NAME

Cypress Veterinary
Clinic

REFERRING VET

Laura Johnson, VMD

INVOICE

22874

DATE

11/07/2025



PATIENT

Tessa Spiron

SPECIES

Canine

BREED

PitBull Terrier

SEX

FS

AGE

14yr

WEIGHT

25.3kg

INTERPRETED BY

R. McKenzie Daniel,
DVM, DABVP
(Canine and Feline)

IMAGING PERFORMED BY

Renee Trionfetti, VMD

HOSPITAL NAME

Cypress Veterinary
Clinic

REFERRING VET

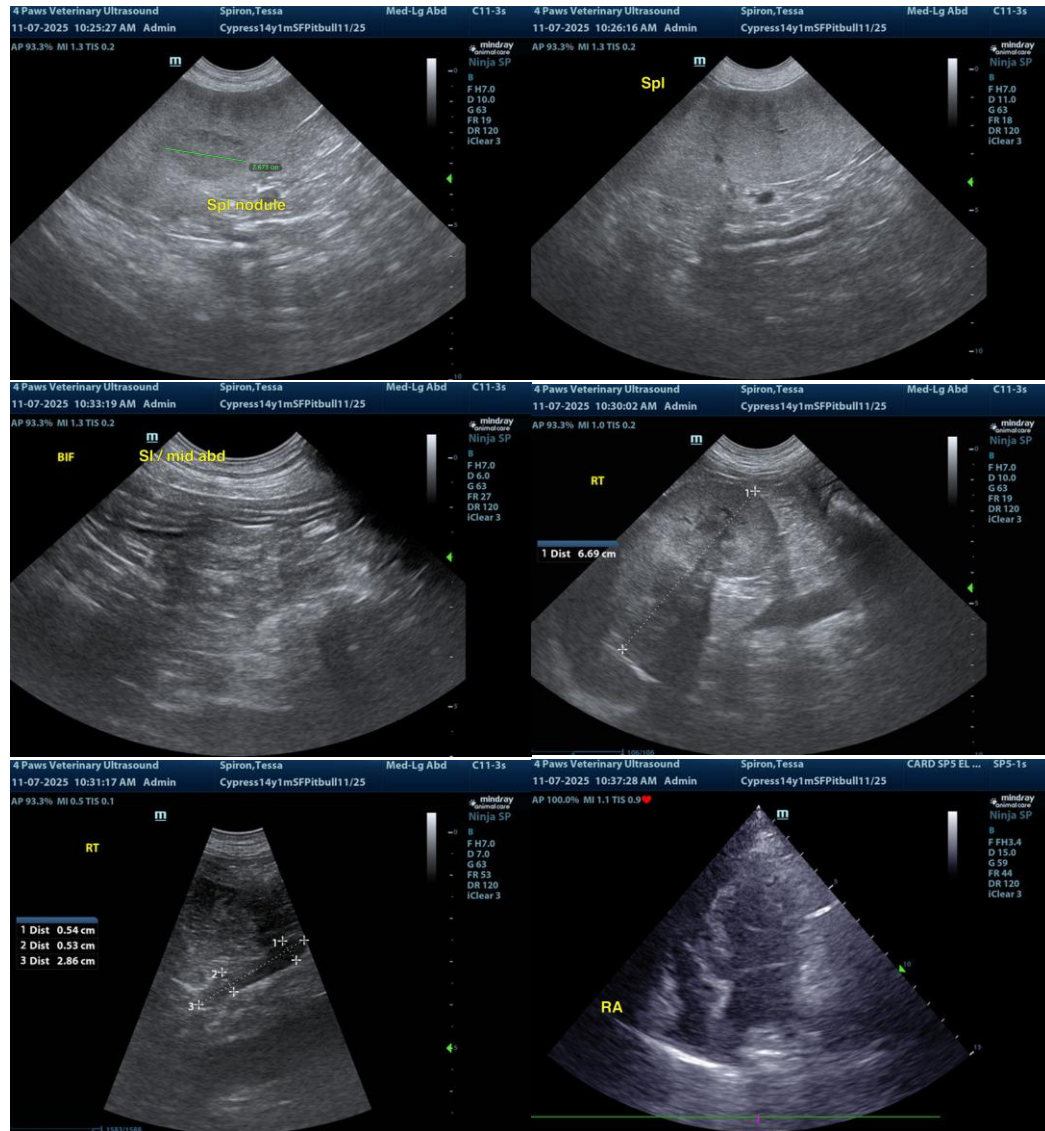
Laura Johnson, VMD

INVOICE

22874

DATE

11/07/2025





PATIENT

Tessa Spiron

SPECIES

Canine

BREED

PitBull Terrier

SEX

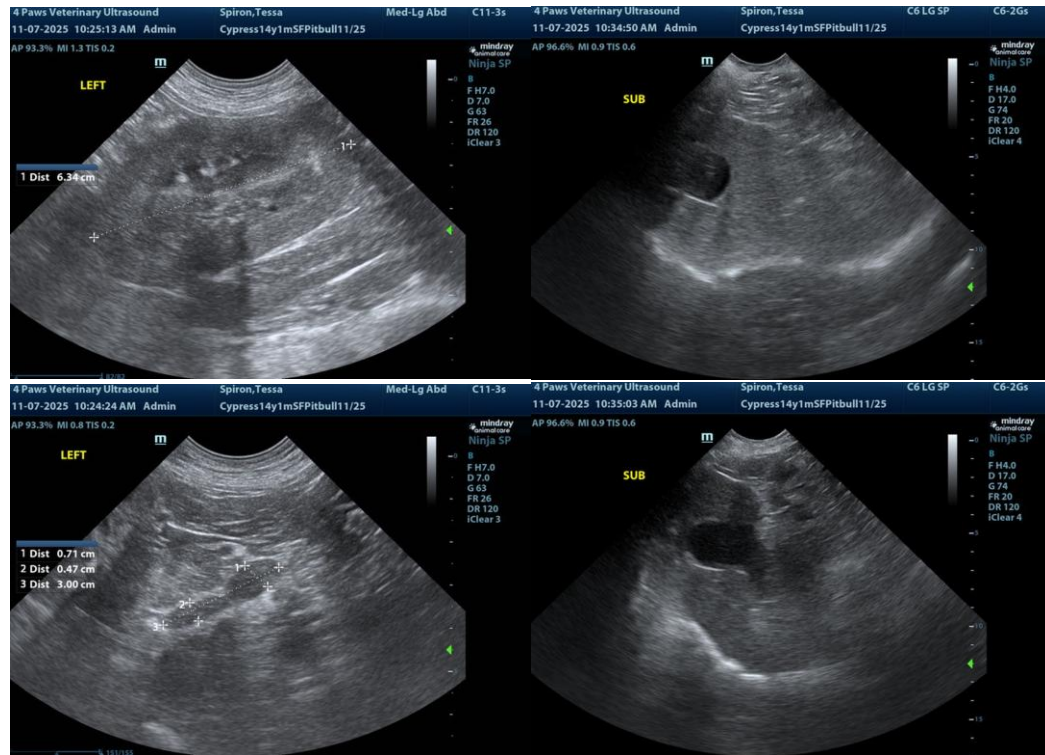
FS

AGE

14yr

WEIGHT

25.3kg



INTERPRETED BY

R. McKenzie Daniel,
DVM, DABVP
(Canine and Feline)

IMAGING PERFORMED BY

Renee Trionfetti, VMD

HOSPITAL NAME

Cypress Veterinary
Clinic

REFERRING VET

Laura Johnson, VMD

INVOICE

22874

DATE

11/07/2025

The information and recommendations provided are based on the images presented by the referring veterinarian/sonographer. No evaluation can be communicated regarding pathology that was not visible in the image/video clips provided.

Thank you for this referral. If the clinical or image interpretation does not parallel your findings or if I can be of any further assistance, please contact me.

R. McKenzie Daniel, DVM, DABVP (Canine/Feline Practice)
info@sonopath.com