



PATIENT

Henly Roosevelt

SPECIES

Canine

BREED

Labrador Retriever

SEX

Neutered Male

AGE

10 Years 4 Months

WEIGHT

47 kg

INTERPRETED BY

R. McKenzie Daniel,
DVM, DABVP

IMAGING PERFORMED BY

Renee Trionfetti VMD

HOSPITAL NAME

Brandywine Valley
Veterinary Hospital

REFERRING VET

Dr. Karen Clark-Rubin
DVM

INVOICE

12153

DATE

11/07/25

PRESENTING CLINICAL SIGNS

AUS to further evaluate decreased appetite, weight loss (~8 lbs in 3 mos), and mild non-regenerative anemia.

Abnormal PE/Chem/CBC/UA Results: CBC: Hct 39.0%, Hgb 13.3 L, normocytic, normochromic, non-regenerative. Plts 380-n - Chem: Alb 2.7- low norm, normal LES, normal BUN, Cr, SDMA, remainder NSF. - T4: 1.5-n - 4Dx: Neg x 4

ULTRASONOGRAPHIC EXAMINATION OF THE ABDOMEN

Urinary System

The urinary bladder, trigone, cystourethral junction, and visible pelvic urethra exhibited normal thickness and tone. Anechoic urine was present in the lumen with no uroliths or sediment. The ureteral papillae were normal. The ureters were not visible which is normal. No evidence of inflammatory or neoplastic change were noted.

The area of the aortic trifurcation was free of pathology.

Normal size and margination was present in the kidneys. A normal 1:3 cortex / medulla ratio was maintained. The medulla and cortices were uniform in texture with some increased echogenicity and mild loss of corticomedullary symmetry and definition expected for the age of the patient. No evidence of pelvic dilation was present. The left kidney measured 8.4 cm in length. The right kidney measured 8.5 cm in length.

Adrenal Glands

The left adrenal gland was uniform in size and contour with a uniformly hypoechoic parenchyma. The left adrenal gland measured 0.83 cm width at the caudal pole.

The right adrenal gland was indistinctly visualized yet overtly normal in size, position and shape. The right adrenal gland subjectively measured 0.72 cm width at the caudal pole.

Spleen

The spleen exhibited a finely textured and homogenous parenchyma which was hyperechoic to the liver and renal cortical parenchyma. The capsule was smooth and regular without apparent expansion. The splenic vasculature at the hilus was normal in volume with no evidence of congestion or thrombosis. Acute to chronic inflammatory, neoplastic, or benign parenchyma changes were not noted.

Liver

The liver was subjectively normal in size, structure, and contour. The liver parenchyma was uniform and hypoechoic to the spleen with a mild coarse echotexture. The hepatic and portal vasculature were normal in appearance without signs of congestion.

The gallbladder was non distended in size with mild nonorganized biliary sludge. The cystic duct and common bile ducts were normal without evidence of dilation.

Gastrointestinal



PATIENT

Henly Roosevelt

SPECIES

Canine

BREED

Labrador Retriever

SEX

Neutered Male

AGE

10 Years 4 Months

WEIGHT

47 kg

INTERPRETED BY

R. McKenzie Daniel,
DVM, DABVP

IMAGING PERFORMED BY

Renee Trionfetti VMD

HOSPITAL NAME

Brandywine Valley
Veterinary Hospital

REFERRING VET

Dr. Karen Clark-Rubin
DVM

INVOICE

12153

DATE

11/07/25

The stomach presented intact wall layering with a normal wall layer ratio. The lumen of the stomach was empty with no signs of ileus, obstruction or foreign material.

The small intestine presented intact wall layering with 1:3 muscularis/mucosa ratio. The lumen of the small intestine was empty with no signs of ileus, obstruction or foreign material.

Normal visible colon wall layers were present with apparent formed feces in lumen.

Pancreas

The area of the pancreas was sonographically normal.

Free Abdomen

No overt lymphadenopathy or peritoneal effusion was present.

ULTRASONOGRAPHIC FINDINGS

- Overall, sonographically normal abdomen.
- Mild nonorganized gallbladder debris (non-mucocele).
- Mild age-related renal changes.

INTERPRETATION OF THE FINDINGS & FURTHER RECOMMENDATIONS

No evidence of visceral pathology as a definitive cause of the patient's clinical signs, anemia and weight loss. No evidence of neoplastic criteria. A GI panel to include PLI/TLI/Cobalamin/Folate as well as three view chest radiographs and neurological / musculoskeletal examination are recommended to assess for or rule out occult disease which may cause weight loss. CBC pathology review and although considered less likely given overtly normal bilateral adrenal glands, screening cortisol level to rule out occult Addison's disease may be considered.



PATIENT

Henly Roosevelt

SPECIES

Canine

BREED

Labrador Retriever

SEX

Neutered Male

AGE

10 Years 4 Months

WEIGHT

47 kg

INTERPRETED BY

R. McKenzie Daniel,
DVM, DABVP

IMAGING PERFORMED BY

Renee Trionfetti VMD

HOSPITAL NAME

Brandywine Valley
Veterinary Hospital

REFERRING VET

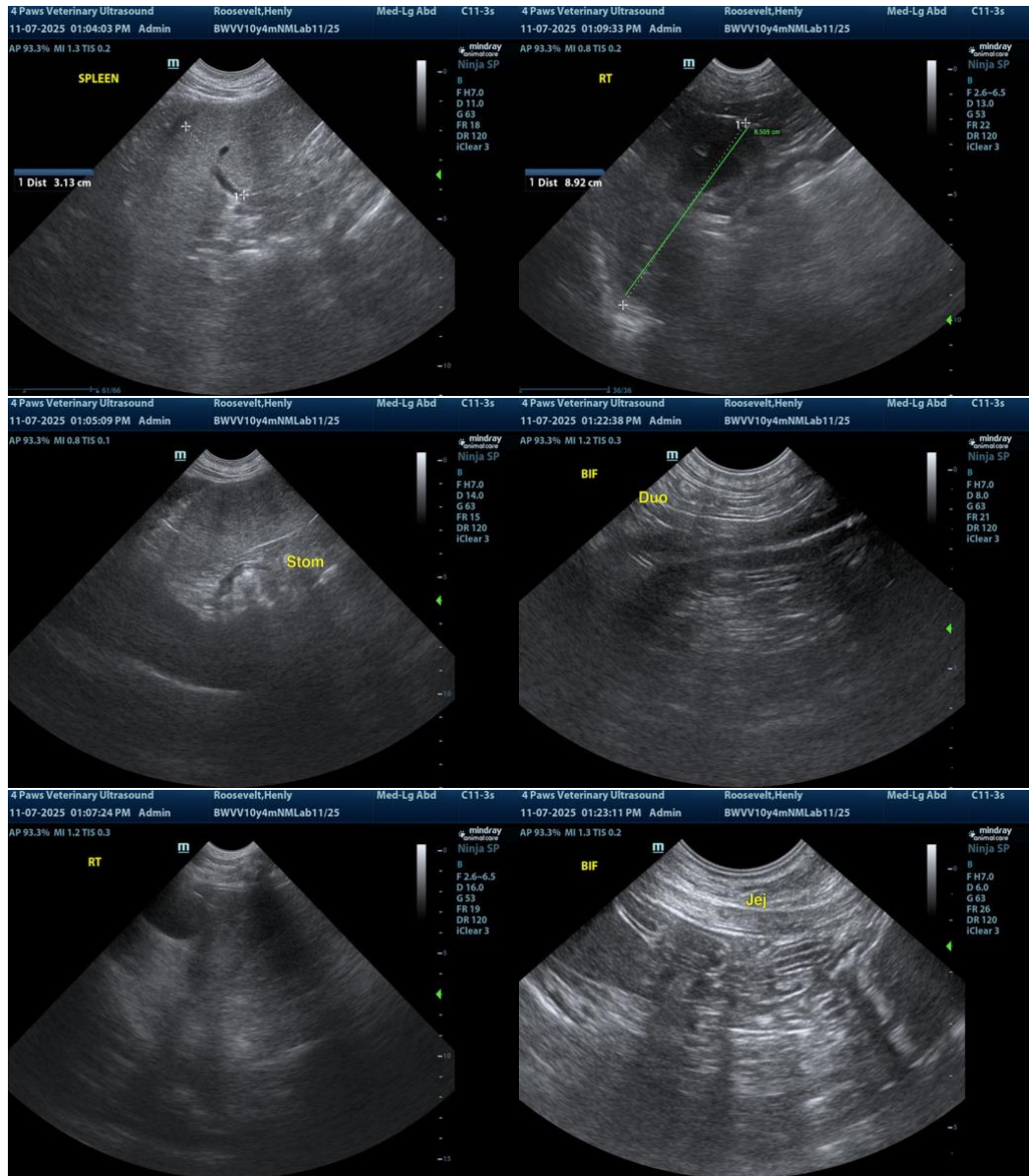
Dr. Karen Clark-Rubin
DVM

INVOICE

12153

DATE

11/07/25





PATIENT

Henly Roosevelt

SPECIES

Canine

BREED

Labrador Retriever

SEX

Neutered Male

AGE

10 Years 4 Months

WEIGHT

47 kg

INTERPRETED BY

R. McKenzie Daniel,
DVM, DABVP

IMAGING PERFORMED BY

Renee Trionfetti VMD

HOSPITAL NAME

Brandywine Valley
Veterinary Hospital

REFERRING VET

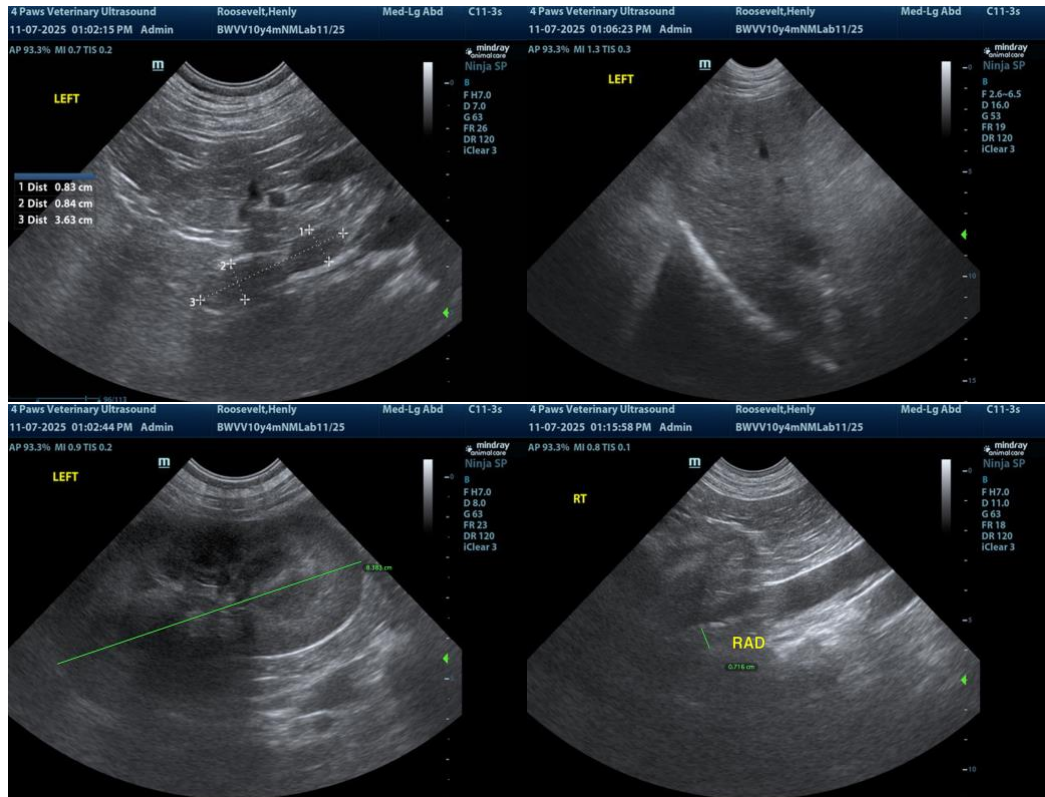
Dr. Karen Clark-Rubin
DVM

INVOICE

12153

DATE

11/07/25



The information and recommendations provided are based on the images presented by the referring veterinarian/sonographer. No evaluation can be communicated regarding pathology that was not visible in the image/video clips provided.

Thank you for this referral. If the clinical or image interpretation does not parallel your findings or if I can be of any further assistance, please contact me.

R. McKenzie Daniel, DVM, DABVP (Canine / Feline Practice)

info@SonoPath.com