



PATIENT

Bane Alrubay

PRESENTING CLINICAL SIGNS

consumed pillow stuffing possible marijuana consumption

SPECIES

Canine

ULTRASONOGRAPHIC EXAMINATION OF THE ABDOMEN

Urinary System

The urinary bladder, trigone, cystourethral junction, and visible pelvic urethra to a depth of – cm exhibited normal thickness and tone. Anechoic urine was present in the lumen with no uroliths or sediment. The ureteral papillae were normal. The ureters were not visible which is normal. No evidence of inflammatory or neoplastic changes were noted.

BREED

Jack Russell

Normal size and margination were present in the kidneys. A normal 1:3 cortex / medulla ratio and normal corticomedullary definition were maintained. The echogenicity of the cortex was similar to or slightly less than normal liver parenchyma while the medulla echogenicity was hypoechoic to the cortex with no evidence of pelvic dilation. The left kidney measured 4.0 cm. The right kidney measured 4.3 cm.

SEX

Canine

Adrenal Glands

The adrenal glands were uniform in size and contour with a uniformly hypoechoic parenchyma. The left adrenal gland measured 1.8 cm long x 0.32 cm at the caudal pole. The right adrenal gland measured 1.7 cm long x 0.49 cm at the caudal pole.

AGE

7 Months

Spleen

The spleen exhibited a finely textured and homogenous parenchyma which was hyperechoic to the liver and renal cortical parenchyma. The capsule was smooth and regular without apparent expansion. The splenic vasculature at the hilus was normal in volume with no evidence of congestion or thrombosis. Acute to chronic inflammatory, neoplastic, or benign parenchyma changes were not noted.

WEIGHT

15 Pounds

INTERPRETED BY

R. McKenzie Daniel,
DVM, DABVP
(Canine and Feline)

Liver

The liver was subjectively normal in size, structure, and contour. The liver parenchyma was uniform and hypoechoic to the spleen with a mild coarse echotexture. The hepatic and portal vasculature were normal in appearance without signs of congestion. The gallbladder was non-distended in size with thin walls and primarily anechoic luminal content. The cystic and common bile ducts were normal.

IMAGING PERFORMED BY

Jenn

Gastrointestinal

HOSPITAL NAME

Rockaway AH

The stomach presented intact wall layering with a normal wall layer ratio. The lumen of the stomach was empty with no signs of ileus, obstruction or foreign material.

The small intestine presented intact wall layering with 1:3 muscularis/mucosa ratio. The lumen of the small intestine was empty with no signs of ileus, obstruction or foreign material.

REFERRING VET

Dr. Maniar

Normal visible colon wall layers were present with apparent formed feces in lumen.

Pancreas

INVOICE

42585

The parenchyma of the left limb, body and right limb of the pancreas presented isoechoic to the adjacent omental fat. A normal curvilinear capsule contour of the pancreas was present. The visible pancreatic duct was normal. No signs of active inflammation or neoplastic disease was evident.

DATE

11/7/22

Free Abdomen

No evidence of significant lymphadenopathy. No peritoneal free fluid.



PATIENT

Bane Alrubay

ULTRASONOGRAPHIC FINDINGS

- Sonographically unremarkable abdomen

SPECIES

Canine

INTERPRETATION OF THE FINDINGS & FURTHER RECOMMENDATIONS

No evidence of gastrointestinal mechanical obstruction or gastrointestinal foreign material. No indication for surgical intervention. Supportive care should be beneficial.

BREED

Jack Russell

SEX

Canine

AGE

7 Months

WEIGHT

15 Pounds

INTERPRETED BY

R. McKenzie Daniel,
DVM, DABVP
(Canine and Feline)

IMAGING PERFORMED BY

Jenn

HOSPITAL NAME

Rockaway AH

REFERRING VET

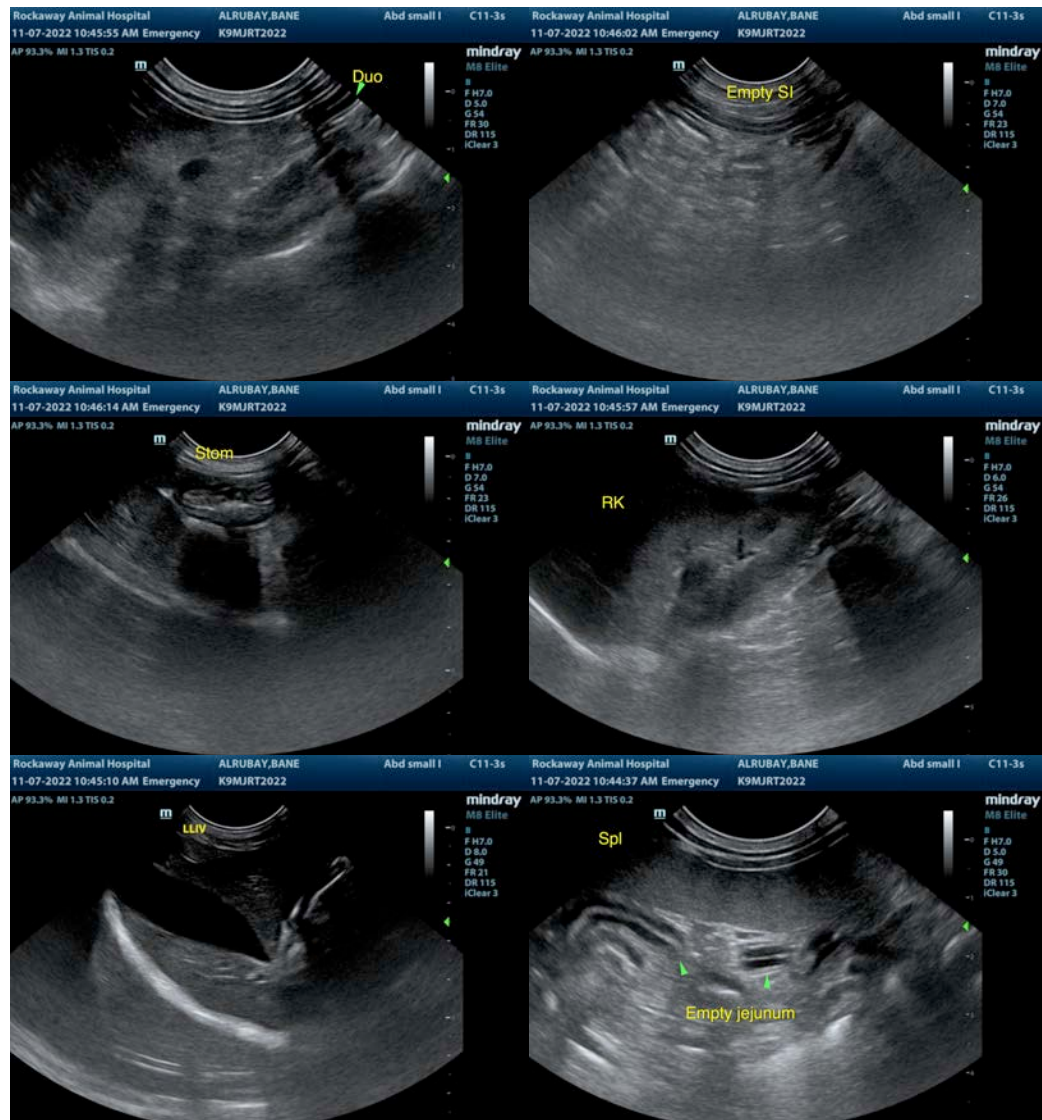
Dr. Maniar

INVOICE

42585

DATE

11/7/22





PATIENT

Bane Alrubay

SPECIES

Canine

BREED

Jack Russell

SEX

Canine

AGE

7 Months

WEIGHT

15 Pounds

INTERPRETED BY

R. McKenzie Daniel,
DVM, DABVP
(Canine and Feline)

IMAGING PERFORMED BY

Jenn

HOSPITAL NAME

Rockaway AH

REFERRING VET

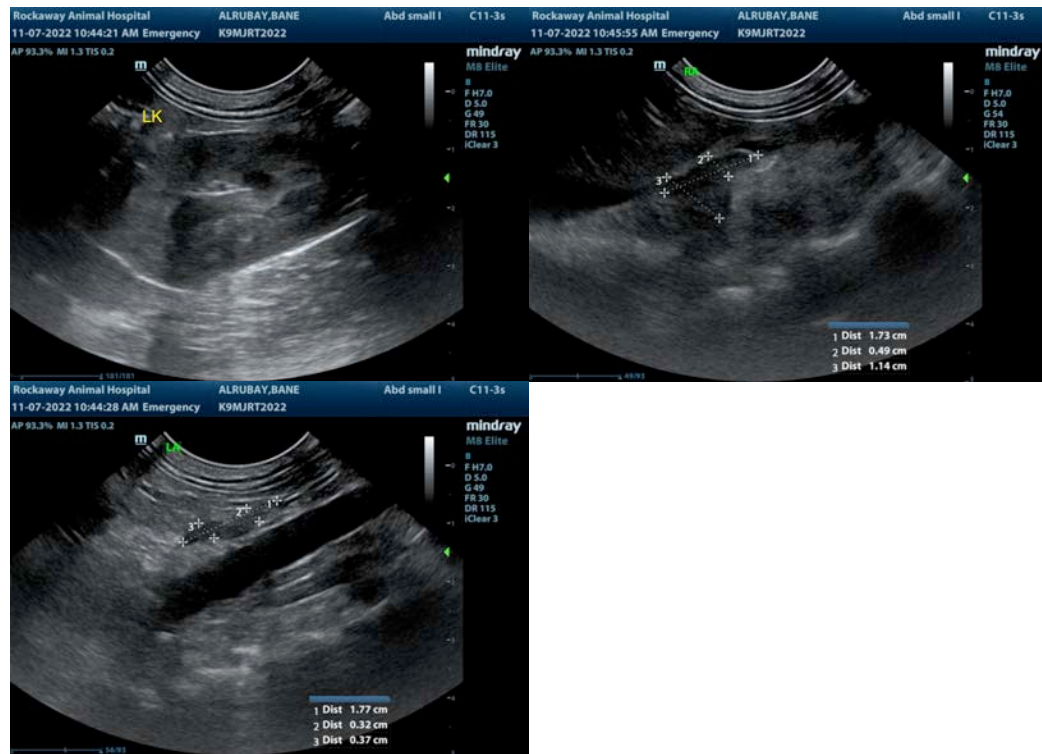
Dr. Maniar

INVOICE

42585

DATE

11/7/22



The information and recommendations provided are based on the images presented by the referring veterinarian/sonographer. No evaluation can be communicated regarding pathology that was not visible in the image/video clips provided.

Thank you for this referral. If the clinical or image interpretation does not parallel your findings or if I can be of any further assistance please contact me.

R. McKenzie Daniel, DVM, DABVP (Canine / Feline Practice)

info@SonoPath.com