



PATIENT

Mumford Roberts

SPECIES

Feline

BREED

DSH

SEX

Male Neutered

AGE

11 yrs

WEIGHT

15.3 lbs

INTERPRETED BY

R. McKenzie Daniel,
DVM, DABVP
(Canine and Feline)

IMAGING PERFORMED BY

Dr. Meghan Myers

HOSPITAL NAME

Hershire AH

REFERRING VET

Companion AH

INVOICE

12780

DATE

11/6/25

PRESENTING CLINICAL SIGNS

History: chronic loss stool for last month -no blood or mucus. 10/23: was also vomiting which resolved

10/29: decrease in appetite treatments tried: fortiflora, psyllium powder, metronidazole - no response in process of switching to hydrolyzed diet

Abnormal PE/Chem/CBC/UA Results: cbc/chem/lytes wnl fecal: nps abdominal rads unremarkable

ULTRASONOGRAPHIC EXAMINATION OF THE ABDOMEN

Urinary System

The urinary bladder, trigone, cystourethral junction, and visible pelvic urethra to a depth of 2.0 cm exhibited normal thickness and tone. Anechoic urine was present in the lumen with no uroliths or sediment. The ureteral papillae were normal. The ureters were not visible which is normal. No evidence of inflammatory or neoplastic changes were noted.

The area of the aortic trifurcation was free of pathology.

Normal size and margination was present in the kidneys. A normal 1:3 cortex / medulla ratio and normal corticomedullary definition were maintained. The echogenicity of the cortex was similar to or slightly less than normal liver parenchyma while the medulla echogenicity was hypoechoic to the cortex with no evidence of pelvic dilation. The left kidney measured 3.6 cm in length. The right kidney measured 3.8 cm in length.

Adrenal Glands

The left adrenal gland was uniform in size and contour with a uniformly hypoechoic parenchyma. The left adrenal gland measured 0.40 cm The right adrenal gland was uniform in size and contour with a uniformly hypoechoic parenchyma. The right adrenal gland measured 0.37 cm.

Spleen

The spleen exhibited a finely textured and homogenous parenchyma which was hyperechoic to the liver and renal cortical parenchyma. The capsule was smooth and regular without apparent expansion. The splenic vasculature at the hilus was normal in volume with no evidence of congestion or thrombosis. Acute to chronic inflammatory, neoplastic, or benign parenchyma changes were not noted.

Liver

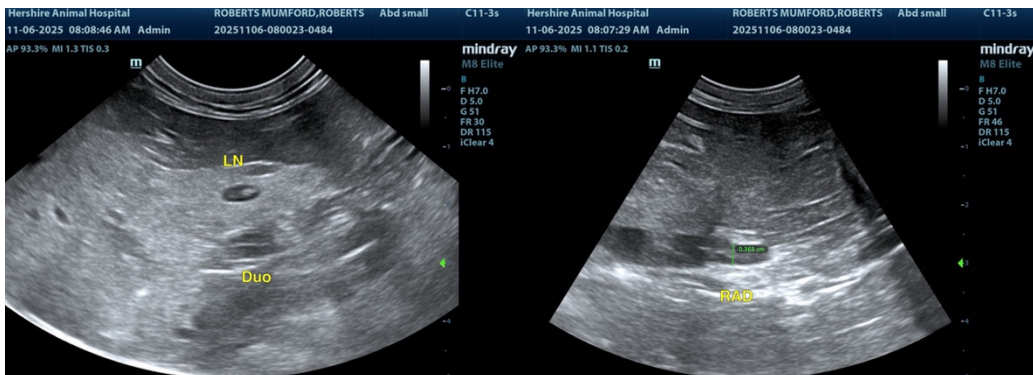
The liver was subjectively normal in size, structure, and contour. The liver parenchyma was uniform and hypoechoic to the spleen with a mild coarse echotexture. The hepatic and portal vasculature were normal in appearance without signs of congestion. The gallbladder was non-distended in size with thin walls and primarily anechoic luminal content. The cystic and common bile ducts were normal.

Gastrointestinal

The stomach presented intact wall layering with a normal wall layer ratio. The lumen of the stomach was empty with no signs of ileus, obstruction or foreign material.



PATIENT	The intestinal walls demonstrated intact mildly thickened wall layers with mild altered wall layer ratio owing to mildly thickened muscularis layer. Small intestine wall measured 0.29 cm, and ileocolic wall measured 0.38 cm.
Mumford Roberts	
SPECIES	The colon was mildly distended in size with normal visible colon wall layers present and apparent soft feces in lumen.
Feline	
BREED	Pancreas
DSH	The parenchyma of the left limb, body and right limb of the pancreas presented isoechoic to the adjacent omental fat. A normal curvilinear capsule contour of the pancreas was present. The visible pancreatic duct was normal. No signs of active inflammation or neoplastic disease was evident.
SEX	Free Abdomen
Male Neutered	Solitary, small, mildly enlarged cranial mesenteric lymph node was present with mild surrounding perilymphatic hyperechoic omentum. The lymph node measured 0.5 cm in diameter. No evidence of peritoneal effusion was noted.
AGE	ULTRASONOGRAPHIC FINDINGS
11 yrs	<ul style="list-style-type: none"> • Mild IBD intestinal pattern • Mildly distended colon with soft fecal matter • Normal area of pancreas • Solitary, mild mesenteric lymphadenopathy with mild perilymphatic hyperechoic omentum
WEIGHT	
15.3 lbs	
INTERPRETED BY	INTERPRETATION OF THE FINDINGS & FURTHER RECOMMENDATIONS
R. McKenzie Daniel, DVM, DABVP (Canine and Feline)	The small intestine exhibited mild mural changes most suggestive of inflammatory criteria with emerging to occult round cell intestinal neoplasia, i.e. lymphoma considered less likely. A GI panel to include PLI/TLI/Cobalamin/Folate and concurrent diarrhea PCR panel is suggested. Monitoring with current hydrolyzed diet transition with consideration for concurrent Cobalamin supplementation pending assessment of Cobalamin level, high colony county probiotic such as Provable, empirical deworming if clinically indicated despite negative fecal testing and as needed gastro protectants may prove beneficial. Definitive diagnosis may require intestinal biopsies for histopathology.
IMAGING PERFORMED BY	
Dr. Meghan Myers	
HOSPITAL NAME	
Hershire AH	
REFERRING VET	
Companion AH	
INVOICE	
12780	
DATE	
11/6/25	





PATIENT

Mumford Roberts

SPECIES

Feline

BREED

DSH

SEX

Male Neutered

AGE

11 yrs

WEIGHT

15.3 lbs

INTERPRETED BY

R. McKenzie Daniel,
DVM, DABVP
(Canine and Feline)

IMAGING PERFORMED BY

Dr. Meghan Myers

HOSPITAL NAME

Hershire AH

REFERRING VET

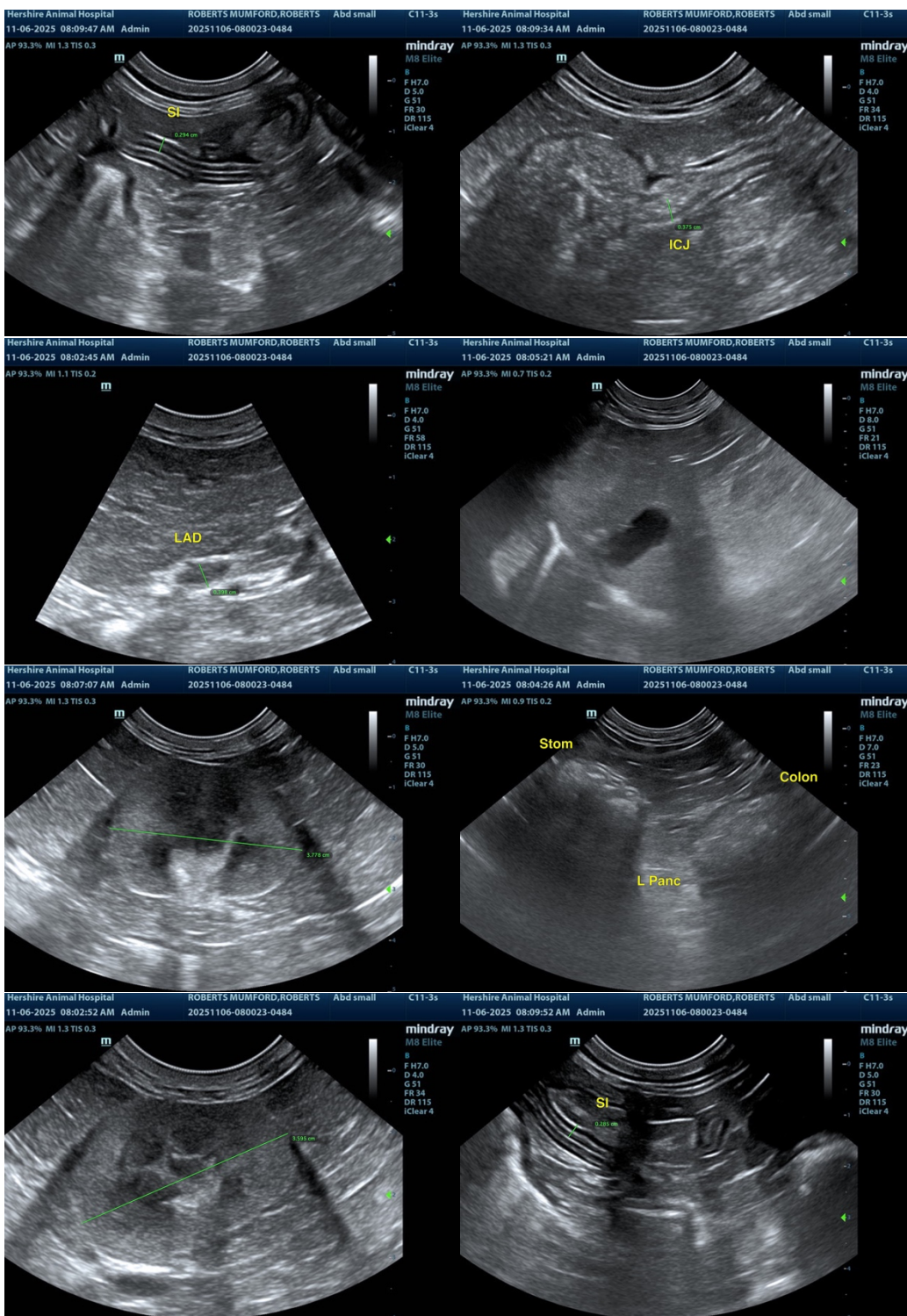
Companion AH

INVOICE

12780

DATE

11/6/25





PATIENT

Mumford Roberts

SPECIES

Feline

BREED

DSH

SEX

Male Neutered

AGE

11 yrs

WEIGHT

15.3 lbs

INTERPRETED BY

R. McKenzie Daniel,
DVM, DABVP
(Canine and Feline)

IMAGING PERFORMED BY

Dr. Meghan Myers

HOSPITAL NAME

Hershire AH

REFERRING VET

Companion AH

INVOICE

12780

DATE

11/6/25

The information and recommendations provided are based on the images presented by the referring veterinarian/sonographer. No evaluation can be communicated regarding pathology that was not visible in the image/video clips provided.

Thank you for this referral. If the clinical or image interpretation does not parallel your findings or if I can be of any further assistance, please contact me.

R. McKenzie Daniel, DVM, DABVP (Canine / Feline Practice)

info@sonopath.com