

PATIENT

Meeko Lautz

SPECIES

Canine

BREED

Shih Tzu Mix

SEX

Neutered Male

AGE

10 years

WEIGHT

15.4

INTERPRETED BY

R. McKenzie Daniel,
DVM, DABVP
(Canine and Feline)

IMAGING PERFORMED BY

Marco Lichfield

HOSPITAL NAME

Sova AH

REFERRING VET

Dr. Ammeraal

INVOICE

10311

DATE

11/5/25

PRESENTING CLINICAL SIGNS

Owner mentioned strong smell from urine, R/O stones

Abnormal PE/Chem/CBC/UA Results: UA showed BLOOD 2+, protein TRACE, RBC 4-10

LIMITED ULTRASONOGRAPHIC EXAMINATION OF URINARY TRACT

Urinary System

The urinary bladder exhibited normal size and tone with normal walls. The trigone and cystourethral junction were free of pathology. The urethra exhibited normal structure and tone to a depth of 2.0 cm. Anechoic urine was present in the lumen with no evidence of urine sediment, mineral, or calculi. The ureteral papillae were normal. The ureters were not visible which is normal. No evidence of inflammatory, neoplastic changes, or tumors was noted.

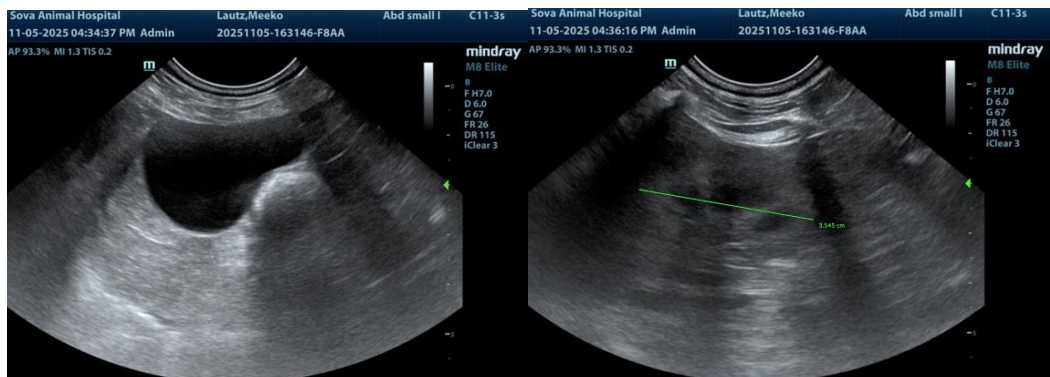
Normal size and margination were present in the kidneys. A normal 1:3 cortex / medulla ratio and normal corticomedullary definition were maintained. The echogenicity of the cortex was similar to or slightly less than normal liver parenchyma while the medulla echogenicity was hypoechoic to the cortex with no evidence of pelvic dilation. The left kidney measured 4.0 cm in length. The right kidney measured 3.5 cm in length. Mild underestimation of right kidney size is possible. No evidence of pyelectasia was noted in either kidney.

ULTRASONOGRAPHIC FINDINGS

- Normal bilateral kidneys and urinary bladder

INTERPRETATION OF THE FINDINGS & FURTHER RECOMMENDATIONS

There is no evidence of upper or lower urinary tract pathology. Correlation with urine C/S, if evidence of inflammatory sediment or UPC if non-inflammatory proteinuria is present, is suggested.





PATIENT

Meeko Lautz

SPECIES

Canine

BREED

Shih Tzu Mix

SEX

Neutered Male

AGE

10 years

WEIGHT

15.4

INTERPRETED BY

R. McKenzie Daniel,
DVM, DABVP
(Canine and Feline)

IMAGING PERFORMED BY

Marco Lichfield

HOSPITAL NAME

Sova AH

REFERRING VET

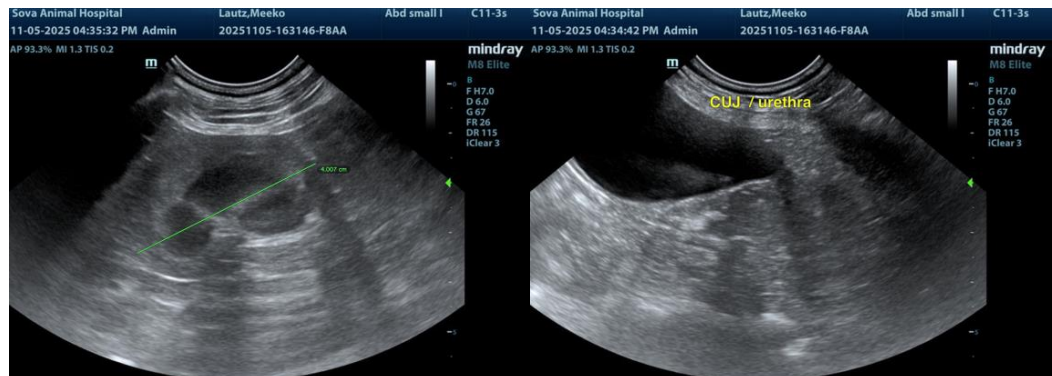
Dr. Ammeraal

INVOICE

10311

DATE

11/5/25



The information and recommendations provided are based on the images presented by the referring veterinarian/sonographer. No evaluation can be communicated regarding pathology that was not visible in the image/video clips provided.

Thank you for this referral. If the clinical or image interpretation does not parallel your findings or if I can be of any further assistance, please contact me.

R. McKenzie Daniel, DVM, DABVP (Canine/Feline Practice)
info@sonopath.com