



PATIENT

George Purdum

SPECIES

Feline

BREED

Domestic Shorthair

SEX

Male (Neutered)

AGE

15 years

WEIGHT

16 lbs.

INTERPRETED BY

R. McKenzie Daniel,
 DVM, DABVP
 (Canine and Feline)

IMAGING PERFORMED BY

Meghan Morse, LVT,
 CVT

HOSPITAL NAME

Rondout Valley
 Veterinary Associates

REFERRING VET

Dr. Hartelius

INVOICE

10300

DATE

11/5/25

PRESENTING CLINICAL SIGNS

Newly acquired cardiac murmur 3/6 right 2/6 left systolic murmur

Current meds: Gabapentin
 Abnormal PE/Chem/CBC/UA Results: None

ULTRASONOGRAPHIC EXAMINATION OF THE HEART

FELINE CARDIAC PARAMETERS	BODY WEIGHT (kg)	HR (BPM)	IVSd (cm)	LVIDd (cm)	LVWd (cm)	FS (%)	EF (%)
NORMAL PARAMETER	-----	150-240	0.3-0.6	1.0-2.1	0.25-0.6	35-67	80-100
PATIENT		NM	0.48	1.6	0.41	55	88
FELINE CARDIAC PARAMETERS	LA/AO (M-mode)	LA/AO HEART BASE (Sisson)	LAD LA MAX 4 Chamber	LVOT VEL. (m/s)	RVOT VEL. (m/s)	IVRT (m/)	
NORMAL PARAMETER	<1.5	1.6	0.7-1.7	<1.6	<1.3	40-60	
PATIENT		1.3	1.3	1.0	0.9		
Adapted from June Boon, Veterinary Echocardiography, 1998 Sisson D et al. JVIM 1991; 5: 232, Jacobs et al. Am J Vet Res 1985; 46:1705							

Cardiac Presentation

The echocardiogram in this patient demonstrated normal **left atrial** size based on 2 separate LA measurements. The cranial and caudal **mitral** valve leaflets presented normal linear structure and kinetics. The **left ventricle** presented normal thicknesses with linear contour and was not dilated nor restricted. The **myocardium** presented normal echogenicity without subjective evidence of significant fibrotic or ischemic disease. **Contractility** of the ventricular walls was adequate and in normal range for this patient evidenced by the fractional shortening measurement and subjective evaluation of the different regions and angles of the myocardium. The **left ventricular outflow** tract demonstrated normal laminar flow and subjective structural integrity. Normal measured LVOT velocity was noted. The **right atrium** and auricle revealed normal size, structure and content. No evidence of masses was noted or chamber overload. **Tricuspid** valvular assessment demonstrated adequate linear morphology and kinetics. The **right ventricle** was of normal size (1/3 diameter of LV), chordae structure, myocardial echogenicity and thickness. **Pulmonic** tract assessment revealed normal valve structure, laminar flow, and diameter (approx. 1:1 pa/ao ratio). Normal measured RVOT velocity was noted. No visible **pericardial** or free pleura fluid was noted or extra cardiac pathology in the visible planes. The cranial **mediastinum** and **pericardial** regions were free of masses in the visible window.

ULTRASONOGRAPHIC FINDINGS

- Normal cardiac structure / function



PATIENT

George Purdum

SPECIES

Feline

BREED

Domestic Shorthair

SEX

Male (Neutered)

AGE

15 years

WEIGHT

16 lbs.

INTERPRETED BY

R. McKenzie Daniel,
 DVM, DABVP
 (Canine and Feline)

IMAGING PERFORMED BY
 Meghan Morse, LVT,
 CVT

HOSPITAL NAME

Rondout Valley
 Veterinary Associates

REFERRING VET

Dr. Hartelius

INVOICE

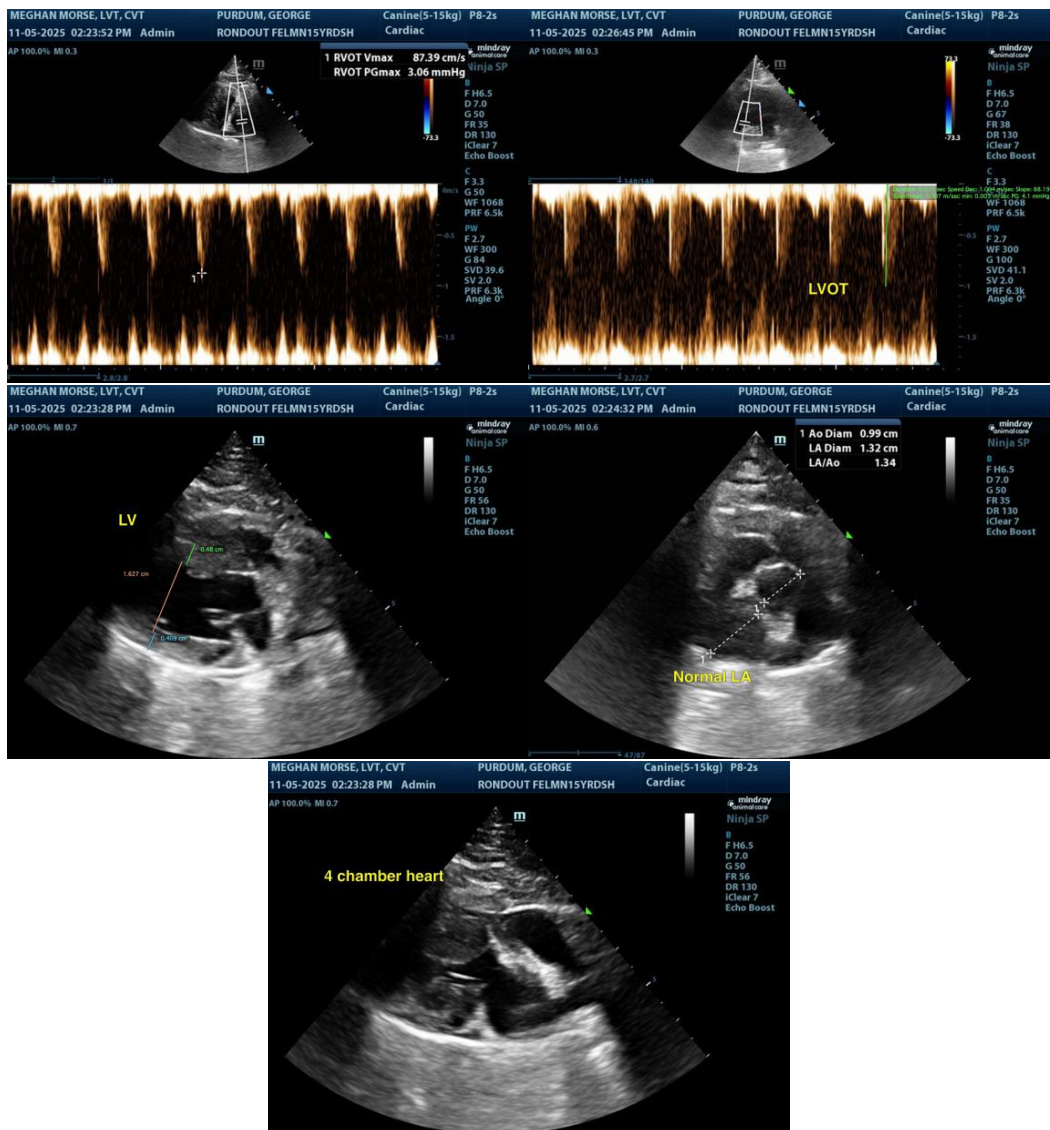
10300

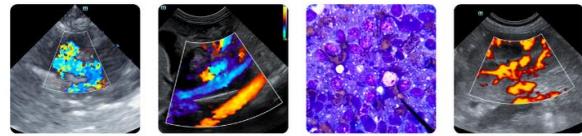
DATE

11/5/25

INTERPRETATION OF THE FINDINGS & FURTHER RECOMMENDATIONS

There were no clinical issues such as left or right heart chamber enlargement, LV systolic dysfunction, HCM criteria, or other structural cardiomyopathy. An obvious cause of the murmur was not identified. A benign flow murmur is suspected, assuming no volume changes or anemia. A small non-visualized flow abnormality is not excluded, yet regardless, the hemodynamic effects of the murmur are low. There is no indication for cardiac medications. Conservative monitoring of the murmur going forward is advised with a recheck echocardiogram suggested in 6 months, sooner if clinical signs arise or if murmur intensity increases.





PATIENT

George Purdum

SPECIES

Feline

BREED

Domestic Shorthair

SEX

Male (Neutered)

AGE

15 years

WEIGHT

16 lbs.

INTERPRETED BY

R. McKenzie Daniel,
DVM, DABVP
(Canine and Feline)

**IMAGING
PERFORMED BY**

Meghan Morse, LVT,
CVT

HOSPITAL NAME

Rondout Valley
Veterinary Associates

REFERRING VET

Dr. Hartelius

INVOICE

10300

DATE

11/5/25

The information and recommendations provided are based on the images presented by the referring veterinarian/sonographer. No evaluation can be communicated regarding pathology that was not visible in the image/video clips provided.

Thank you for this referral. If the clinical or image interpretation does not parallel your findings or if I can be of any further assistance, please contact me.

R. McKenzie Daniel, DVM, DABVP (Canine / Feline Practice)
info@sonopath.com