

PATIENT

Arya Hawkes

SPECIES

Canine

BREED

Bulldog

SEX

FS

AGE

5 years, 4 months

WEIGHT

16.7 kg

INTERPRETED BY

R. McKenzie Daniel,
DVM, DABVP
(Canine and Feline)

IMAGING PERFORMED BY

Dr. Caroline Tan

HOSPITAL NAME

Petzoic Vet Hospital

REFERRING VET

Dr. Janine Vander
Pol

INVOICE

10308

DATE

11/5/25

PRESENTING CLINICAL SIGNS

Dermal MCT growth to be Sx removed. P is doing well. V once this week but now eating and drinking well. Mildly elevated ALT. Chest rads NSF. Unremarkable peripheral LNs

Abnormal PE/Chem/CBC/UA Results: BAR. Mildly elevated ALT. Chest rads NSF

ULTRASONOGRAPHIC EXAMINATION OF THE ABDOMEN

Urinary System

The urinary bladder, trigone, cystourethral junction, and visible pelvic urethra to a depth of 3.0 cm exhibited normal thickness and tone. Anechoic urine was present in the lumen with no evidence of urine or lumen sediment, mineral, or calculi. The ureteral papillae were normal. The ureters were not visible which is normal. No evidence of inflammatory or neoplastic changes was noted.

Medial iliac lymph nodes were present. The lymph nodes were essentially isoechoic to adjacent omentum without evidence of peripheral inflammation and maintaining a normal width: length ratio (<0.5). An example lymph node measured 2.0 cm x 0.66 cm.

Normal size and margination were present in the kidneys. A normal 1:3 cortex / medulla ratio and normal corticomedullary definition were maintained. The echogenicity of the cortex was similar to or slightly less than normal liver parenchyma while the medulla echogenicity was hypoechoic to the cortex with mild left kidney pyelectasia. The left kidney measured 6.0 cm in length. The right kidney measured 6.0 cm in length.

Adrenal Glands

The left adrenal gland was uniform in size and contour with a uniformly hypoechoic parenchyma. The left adrenal gland measured 0.64 cm width at the caudal pole. The right adrenal gland was uniform in size and contour with a uniformly hypoechoic parenchyma. The right adrenal gland measured 0.44 cm width at the caudal pole.

Spleen

The spleen exhibited a finely textured and homogenous parenchyma which was hyperechoic to the liver and renal cortical parenchyma. The capsule was smooth and regular without apparent expansion. The splenic vasculature at the hilus was normal in volume with no evidence of congestion or thrombosis. Acute to chronic inflammatory, neoplastic, or benign parenchyma changes were not noted.

Liver/ Gallbladder

The liver was subjectively normal in size, structure, and contour. The liver parenchyma was uniform and hypoechoic to the spleen with a mild coarse echotexture. The hepatic and portal vasculature were normal in appearance without signs of congestion. The gallbladder was non-distended in size containing primarily anechoic content with moderate, nondependent to dependent, mildly congealed yet nonorganized gallbladder debris. The cystic and common bile ducts were normal.



PATIENT

Arya Hawkes

SPECIES

Canine

BREED

Bulldog

SEX

FS

AGE

5 years, 4 months

WEIGHT

16.7 kg

INTERPRETED BY

R. McKenzie Daniel,
DVM, DABVP
(Canine and Feline)

IMAGING PERFORMED BY

Dr. Caroline Tan

HOSPITAL NAME

Petzoic Vet Hospital

REFERRING VET

Dr. Janine Vander
Pol

INVOICE

10308

DATE

11/5/25

Gastrointestinal

The stomach presented intact wall layering with a normal wall layer ratio. The lumen of the stomach was empty without evidence of retained ingesta, fluid, or foreign material.

The small intestine presented intact wall layering with 1:3 muscularis/mucosa ratio. The lumen of the small intestine was empty with no signs of ileus, obstruction, or foreign material.

Normal visible colon wall layers were present with apparent formed feces in lumen.

Pancreas

The parenchyma of the left limb, body, and right limb of the pancreas presented isoechoic to the adjacent omental fat. A normal curvilinear capsule contour of the pancreas was present. The visible pancreatic duct was normal. No signs of active inflammation or neoplastic disease were evident.

Free Abdomen

No overt lymphadenopathy or peritoneal effusion was present.

ULTRASONOGRAPHIC FINDINGS

- Sonographically normal spleen
- Mild left kidney pyelectasia
- Sonographically unremarkable normal volume liver - consistent with low-grade benign hepatopathy
- Nonorganized gallbladder debris (non mucocele)
- Mild medial iliac lymphadenopathy

INTERPRETATION OF THE FINDINGS & FURTHER RECOMMENDATIONS

There is no overt evidence of intrabdominal primary or metastatic neoplastic criteria. The medial iliac lymphadenopathy is suggestive of incidental or mild hyperplastic criteria. Sonographic monitoring of the medial iliac lymph nodes for evidence of progression with initial recheck in 4 weeks is recommended.

Assuming normal clotting status and using a 25-gauge needle, screening splenic FNA cytology could be considered to ensure no evidence of non-sonographically evident metastasis. Correlation with the nonspecific mild left kidney pyelectasia with urinary workup is recommended.



PATIENT

Arya Hawkes

SPECIES

Canine

BREED

Bulldog

SEX

FS

AGE

5 years, 4 months

WEIGHT

16.7 kg

INTERPRETED BY

R. McKenzie Daniel,
DVM, DABVP
(Canine and Feline)

IMAGING PERFORMED BY

Dr. Caroline Tan

HOSPITAL NAME

Petzoic Vet Hospital

REFERRING VET

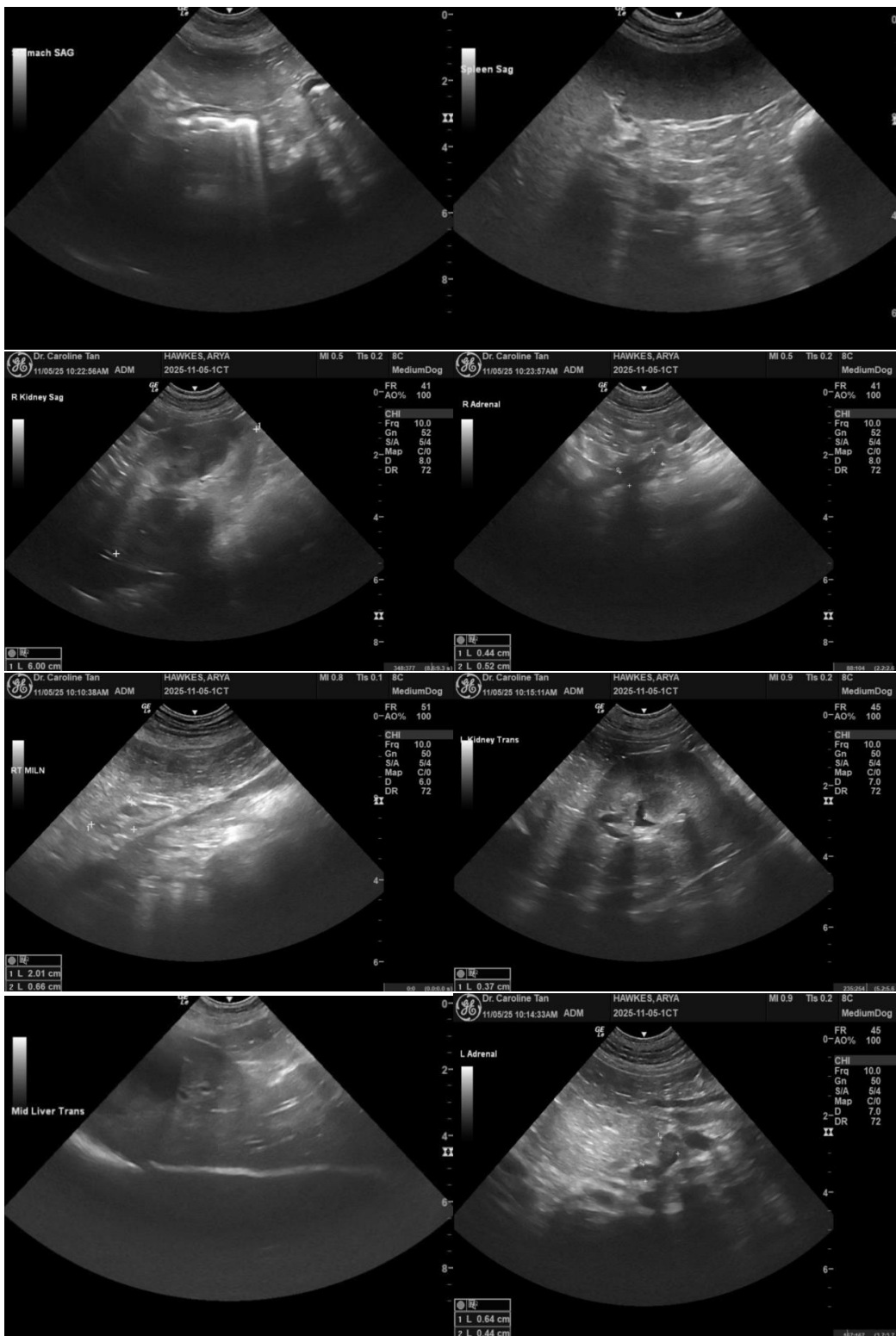
Dr. Janine Vander
Pol

INVOICE

10308

DATE

11/5/25





PATIENT

Arya Hawkes

SPECIES

Canine

BREED

Bulldog

SEX

FS

AGE

5 years, 4 months

WEIGHT

16.7 kg

INTERPRETED BY

R. McKenzie Daniel,
DVM, DABVP
(Canine and Feline)

IMAGING PERFORMED BY

Dr. Caroline Tan

HOSPITAL NAME

Petzoic Vet Hospital

REFERRING VET

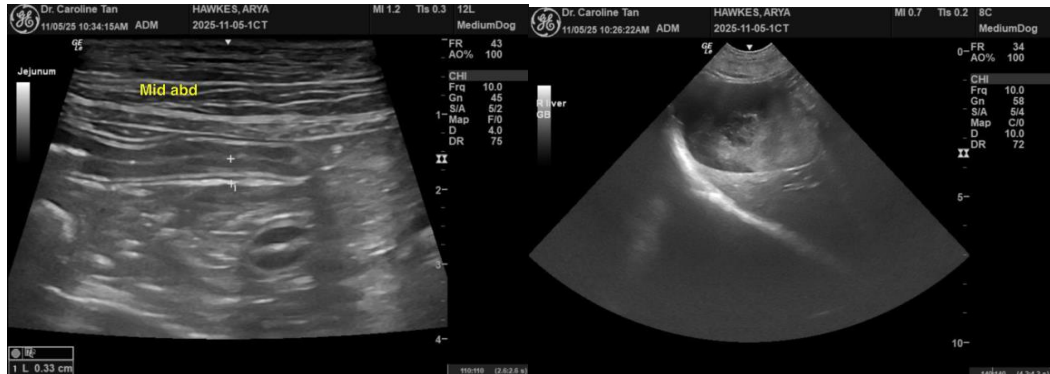
Dr. Janine Vander
Pol

INVOICE

10308

DATE

11/5/25



The information and recommendations provided are based on the images presented by the referring veterinarian/sonographer. No evaluation can be communicated regarding pathology that was not visible in the image/video clips provided.

Thank you for this referral. If the clinical or image interpretation does not parallel your findings or if I can be of any further assistance, please contact me.

R. McKenzie Daniel, DVM, DABVP (Canine/Feline Practice)
info@sonopath.com