



**PATIENT**

Charlie Beaz

**SPECIES**

Canine

**BREED**

Poodle

**SEX**

MN

**AGE**

1

**WEIGHT**

14

**INTERPRETED BY**

R. McKenzie Daniel,  
DVM, DABVP  
(Canine and Feline)

**IMAGING PERFORMED BY**

Jenn

**HOSPITAL NAME**

Rockaway AH

**REFERRING VET**

Dr. Maniar

**INVOICE**

15409

**DATE**

11/5/22

**PRESENTING CLINICAL SIGNS**

re check prev u/s on 11/5 showed focal ileus or a small pyloric outflow tract obstruction Patient is doing well

**ULTRASONOGRAPHIC EXAMINATION OF THE ABDOMEN**

**Urinary System**

The urinary bladder, trigone, and cystourethral junction exhibited normal thickness and tone. Anechoic urine was present in the lumen with no uroliths or sediment. The ureteral papillae were normal. The ureters were not visible which is normal. No evidence of inflammatory or neoplastic changes was noted.

The area of the aortic trifurcation was free of pathology.

Normal size and margination were present in the kidneys. A normal 1:3 cortex / medulla ratio and normal corticomedullary definition were maintained. The echogenicity of the cortex was similar to or slightly less than normal liver parenchyma while the medulla echogenicity was hypoechoic to the cortex with no evidence of pelvic dilation. The left kidney measured 4.0 cm in length. The right kidney measured 3.8 cm in length.

**Adrenal Glands**

The left adrenal gland was uniform in size and contour with a uniformly hypoechoic parenchyma. The left adrenal gland measured 1.5 cm length x 0.46 cm width at the caudal pole. The right adrenal gland was uniform in size and contour with a uniformly hypoechoic parenchyma. The right adrenal gland measured 1.4 cm length x 0.54 cm width at the caudal pole.

**Spleen**

The spleen exhibited a finely textured and homogenous parenchyma which was hyperechoic to the liver and renal cortical parenchyma. The capsule was smooth and regular without apparent expansion. The splenic vasculature at the hilus was normal in volume with no evidence of congestion or thrombosis. Acute to chronic inflammatory, neoplastic, or benign parenchyma changes were not noted.

**Liver/ Gallbladder**

The liver was subjectively normal in size, structure, and contour. The liver parenchyma was uniform and hypoechoic to the spleen with a mild coarse echotexture. The hepatic and portal vasculature were normal in appearance without signs of congestion. The gallbladder was non-distended in size with thin walls and primarily anechoic luminal content. The cystic and common bile ducts were normal.

**Gastrointestinal**

The stomach presented intact yet mildly prominent wall layering. The stomach was primarily empty with luminal gas and minor retained mildly echogenic fluid. No evidence of gastric foreign body or mechanical pyloric outflow obstruction was noted. The pylorus wall width measured 0.45 cm. The gastric body wall width measured 0.65 cm.

The small intestine presented intact wall layering with 1:3 muscularis/mucosa ratio. The lumen of the small intestine was empty with no signs of ileus, obstruction, or foreign material.



**PATIENT**

Normal visible colon wall layers were present with apparent formed feces in lumen.

Charlie Beaz

**Pancreas**

**SPECIES**

The parenchyma of the left limb, body, and right limb of the pancreas presented isoechoic to the adjacent omental fat. A normal curvilinear capsule contour of the pancreas was present. The visible pancreatic duct was normal. No signs of active inflammation or neoplastic disease were evident.

Canine

**BREED**

**Free Abdomen**

Poodle

No overt lymphadenopathy or peritoneal effusion was present.

**SEX**

**ULTRASONOGRAPHIC FINDINGS**

MN

- Intact yet mildly prominent gastric walls with minor retained echogenic fluid and luminal gas
- Sonographically unremarkable small bowel

**AGE**

**INTERPRETATION OF THE FINDINGS & FURTHER RECOMMENDATIONS**

1

**WEIGHT**

The sonographic appearance of the stomach is suggestive of mild inflammatory gastropathy / gastritis. No evidence of gastric foreign was noted. Sonographically, the appearance of the stomach is suggestive of gastritis with potential for mild gastric hypomotility, yet without evidence of gastric foreign material or mechanical pyloric outflow obstruction. Conservative therapy for gastritis or depending on the patient's current clinical signs should prove effective.

14

**INTERPRETED BY**

R. McKenzie Daniel,  
DVM, DABVP  
(Canine and Feline)

**IMAGING PERFORMED BY**

Jenn

**HOSPITAL NAME**

Rockaway AH

**REFERRING VET**

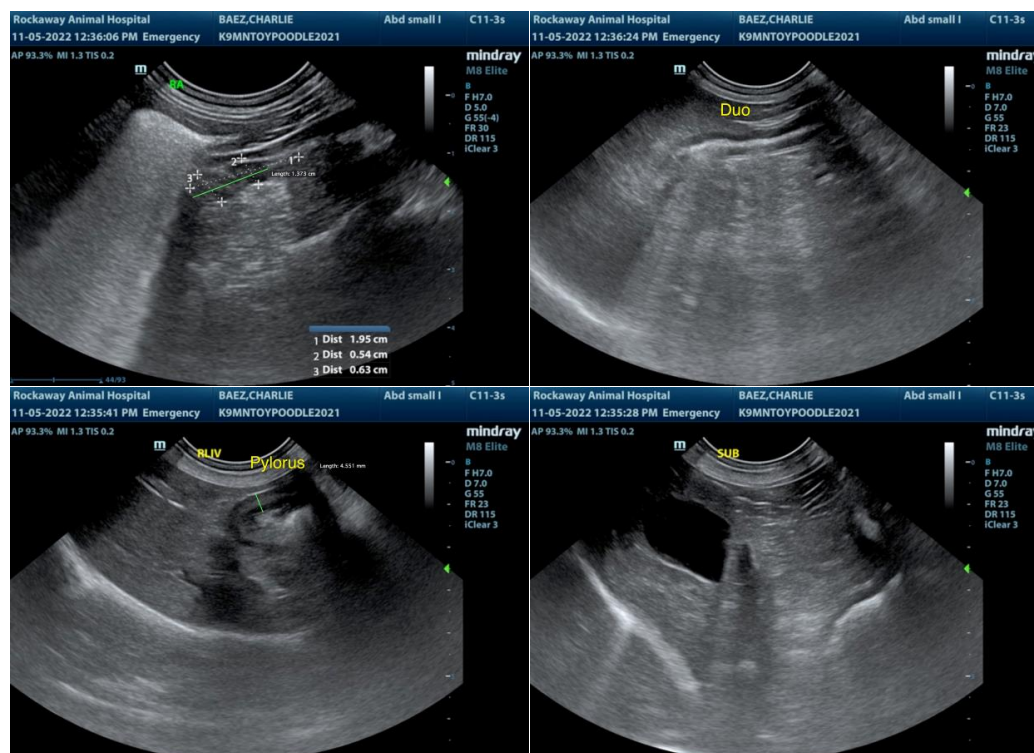
Dr. Maniar

**INVOICE**

15409

**DATE**

11/5/22





**PATIENT**

Charlie Beaz

**SPECIES**

Canine

**BREED**

Poodle

**SEX**

MN

**AGE**

1

**WEIGHT**

14

**INTERPRETED BY**

R. McKenzie Daniel,  
DVM, DABVP  
(Canine and Feline)

**IMAGING PERFORMED BY**

Jenn

**HOSPITAL NAME**

Rockaway AH

**REFERRING VET**

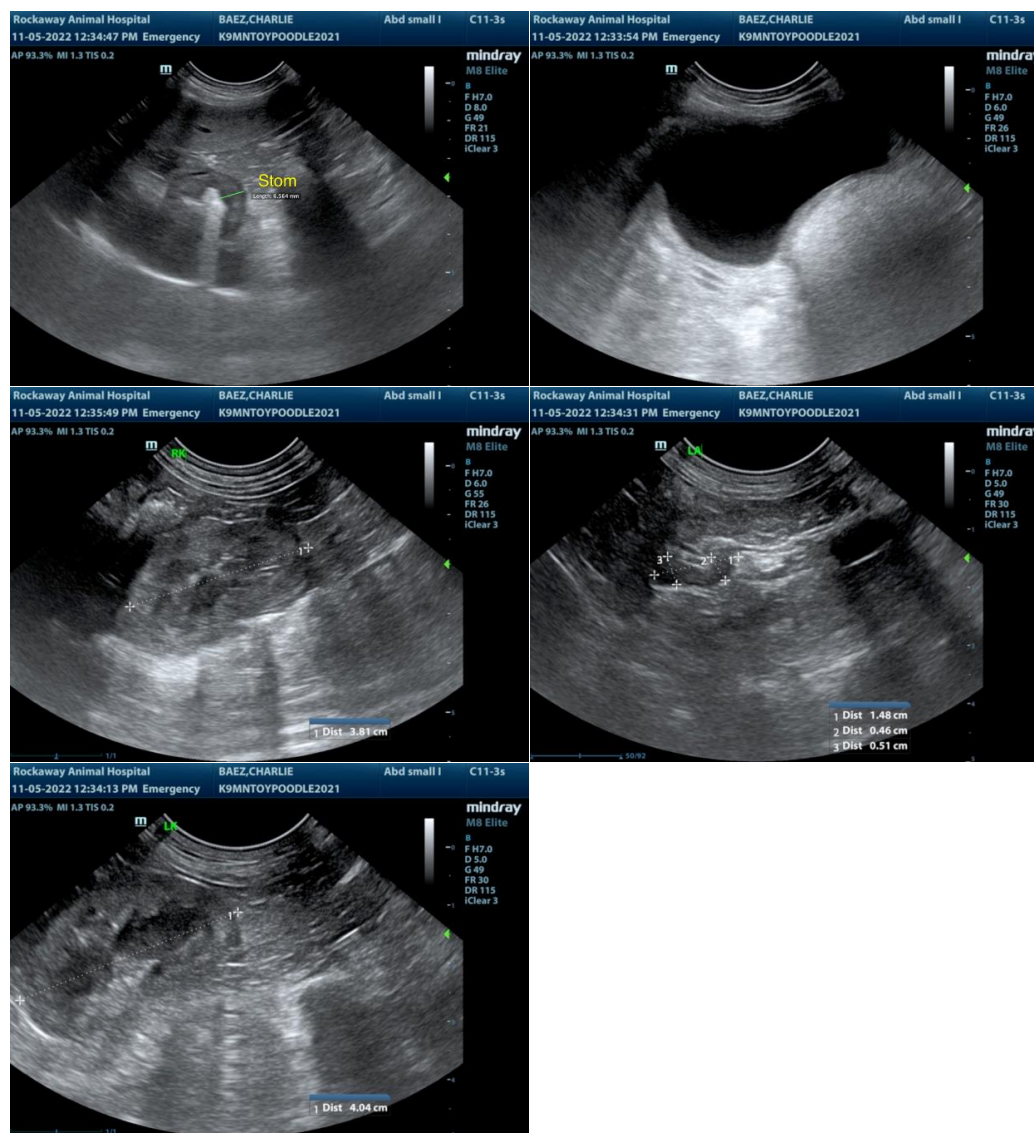
Dr. Maniar

**INVOICE**

15409

**DATE**

11/5/22



The information and recommendations provided are based on the images presented by the referring veterinarian/sonographer. No evaluation can be communicated regarding pathology that was not visible in the image/video clips provided.

Thank you for this referral. If the clinical or image interpretation does not parallel your findings or if I can be of any further assistance please contact me.

R. McKenzie Daniel, DVM, DABVP (Canine / Feline Practice)  
info@SonoPath.com