



PATIENT

Finley Straub

SPECIES

Canine

BREED

Border Collie

SEX

MN

AGE

5 years

WEIGHT

48 lbs.

INTERPRETED BY

R. McKenzie Daniel,
DVM, DABVP
(Canine and Feline)

**IMAGING
PERFORMED BY**

Jenna Walsh, CVT

HOSPITAL NAME

Edgewood AC

REFERRING VET

Dr. Kimball

INVOICE

12539

DATE

11/5/21

PRESENTING CLINICAL SIGNS

Episode of gastroenteritis mid September and elevation of ALT (156) was found during visit to emergency clinic. He started Denamarin at that time and recheck of liver chemistries late October showed no change. Finley is acting completely normal at this time Current Medications Denamarin
Abnormal PE/Chem/CBC/UA Results: ALT- 156 mid September and late October

ULTRASONOGRAPHIC EXAMINATION OF THE ABDOMEN

Urinary System

The urinary bladder, trigone, cystourethral junction, and visible pelvic urethra to a depth of 5.0 cm exhibited normal thickness and tone. Anechoic urine was present in the lumen with no uroliths or sediment. The ureteral papillae were normal. The ureters were not visible which is normal. No evidence of inflammatory or neoplastic changes was noted.

The residual prostate was symmetrically normal in size with uniform parenchyma and slight coarse echotexture measuring 1.5 cm in diameter.

The area of the aortic trifurcation was free of pathology.

Normal size and margination were present in the kidneys. A normal 1:3 cortex / medulla ratio and normal corticomedullary definition were maintained. The echogenicity of the cortex was similar to or slightly less than normal liver parenchyma while the medulla echogenicity was hypoechoic to the cortex with no evidence of pelvic dilation. The left kidney measured 6.0 cm in length. The right kidney measured 6.4 cm in length.

Adrenal Glands

The left adrenal gland was uniform in size and contour with a uniformly hypoechoic parenchyma. The left adrenal gland measured 2.2 cm length x 0.64 cm width at the caudal pole. The right adrenal gland was uniform in size and contour with a uniformly hypoechoic parenchyma. The right adrenal gland measured 2.5 cm length x 0.63 cm width at the caudal pole.

Spleen

The spleen exhibited a finely textured and homogenous parenchyma which was hyperechoic to the liver and renal cortical parenchyma. The capsule was smooth and regular without apparent expansion. The splenic vasculature at the hilus was normal in volume with no evidence of congestion or thrombosis. Acute to chronic inflammatory, neoplastic, or benign parenchyma changes were not noted.

Liver/ Gallbladder

The liver was subjectively normal in size, structure, and contour. The liver parenchyma was uniform and hypoechoic to the spleen with a mild coarse echotexture. The hepatic and portal vasculature were normal in appearance without signs of congestion. The gallbladder was non-distended in size with mild, echogenic, congealed yet subjectively mobile gallbladder debris. The gallbladder was otherwise



PATIENT

normal, without evidence of gallbladder or peripheral inflammation. The cystic and common bile ducts were normal.

Finley Straub

SPECIES

Canine

BREED

Border Collie

SEX

MN

AGE

5 years

WEIGHT

48 lbs.

Gastrointestinal

The stomach presented intact wall layering with a normal wall layer ratio. The lumen of the stomach was empty with no signs of ileus, obstruction, or foreign material. The gastric body wall width measured 0.45 cm.

The small intestine presented intact wall layering with 1:3 muscularis/mucosa ratio. The lumen of the small intestine was empty with no signs of ileus, obstruction, or foreign material. The jejunum wall width measured 0.35 cm.

Normal visible colon wall layers were present with apparent formed feces in lumen.

Pancreas

The parenchyma of the left limb, body, and right limb of the pancreas presented isoechoic to the adjacent omental fat. A normal curvilinear capsule contour of the pancreas was present. The visible pancreatic duct was normal. No signs of active inflammation or neoplastic disease were evident.

Free Abdomen

No overt lymphadenopathy or peritoneal effusion was present.

INTERPRETED BY

R. McKenzie Daniel,
DVM, DABVP
(Canine and Feline)

ULTRASONOGRAPHIC FINDINGS

Primary Findings

- Low-grade hepatopathy - subjectively benign
- Mild congealed gallbladder debris
- Sonographically unremarkable gastrointestinal tract and pancreas

IMAGING PERFORMED BY

Jenna Walsh, CVT

INTERPRETATION OF THE FINDINGS & FURTHER RECOMMENDATIONS

HOSPITAL NAME

Edgewood AC

Overall, the liver was nonspecific yet without evidence of structural pathology and consistent with benign low-grade hepatopathy. Potential considerations may include reactive hepatopathy, low-grade hepatic parenchymal or hepatobiliary process, given the presence of mild gallbladder debris, or other hepatopathies. Given the low-grade ALT elevation, continued monitoring at this time with the addition of Ursodiol to current Denamarin would be appropriate. Hepatic sampling would be required for further clarification.

REFERRING VET

Dr. Kimball

INVOICE

12539

DATE

11/5/21



PATIENT

Finley Straub

SPECIES

Canine

BREED

Border Collie

SEX

MN

AGE

5 years

WEIGHT

48 lbs.

INTERPRETED BY

R. McKenzie Daniel,
DVM, DABVP
(Canine and Feline)

IMAGING PERFORMED BY

Jenna Walsh, CVT

HOSPITAL NAME

Edgewood AC

REFERRING VET

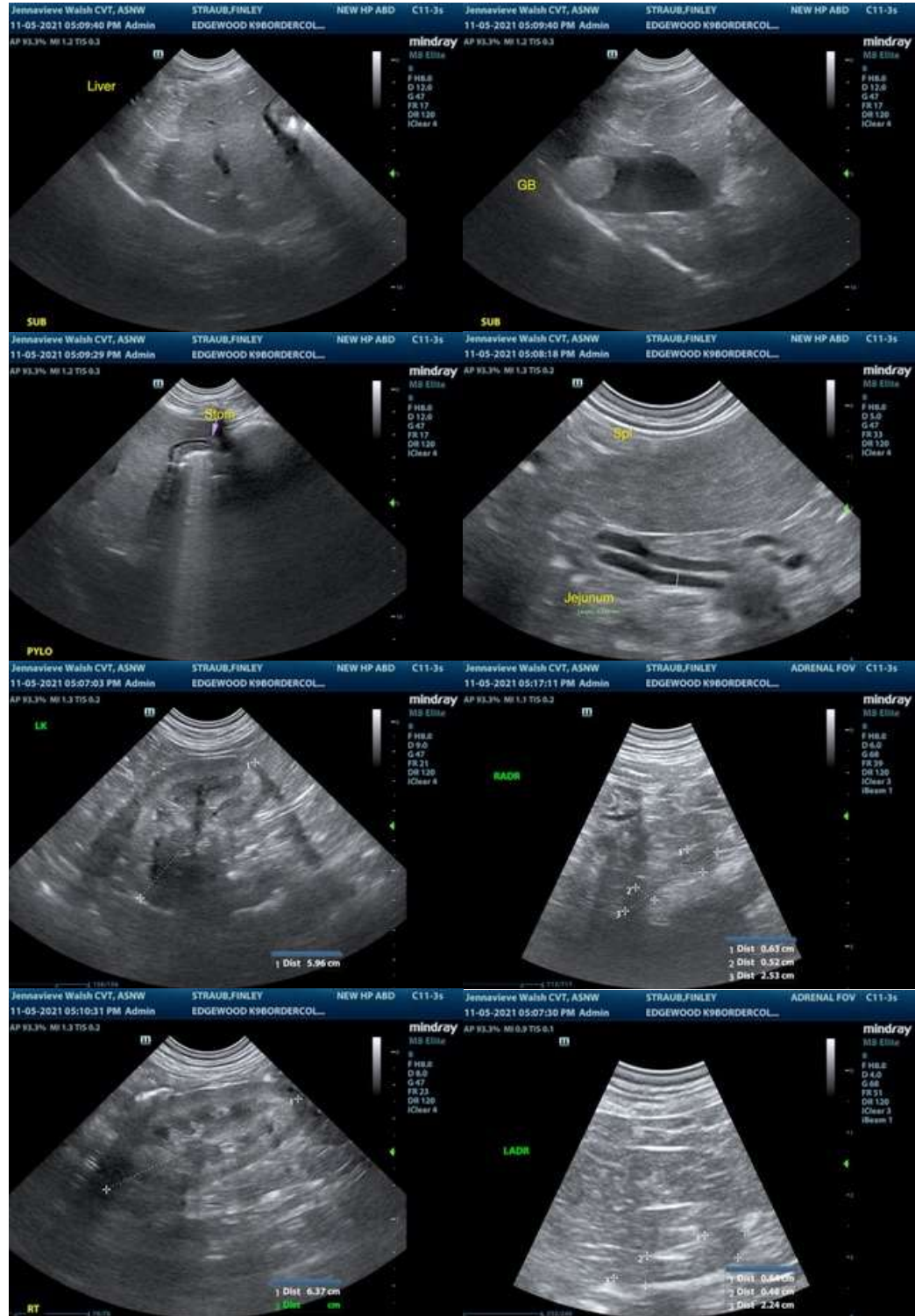
Dr. Kimball

INVOICE

12539

DATE

11/5/21





PATIENT

Finley Straub

The information and recommendations provided are based on the images presented by the referring veterinarian. No evaluation can be communicated regarding pathology that was not visible in the image/video clips provided.

SPECIES

Canine

Thank you for this referral. If the clinical or image interpretation does not parallel your findings or if I can be of any further assistance please contact me.

BREED

Border Collie

R. McKenzie Daniel, DVM, DABVP (Canine / Feline Practice)
info@SonoPath.com

SEX

MN

AGE

5 years

WEIGHT

48 lbs.

INTERPRETED BY

R. McKenzie Daniel,
DVM, DABVP
(Canine and Feline)

IMAGING PERFORMED BY

Jenna Walsh, CVT

HOSPITAL NAME

Edgewood AC

REFERRING VET

Dr. Kimball

INVOICE

12539

DATE

11/5/21