



PATIENT	PRESENTING CLINICAL SIGNS
Max Neiman	Presented for ultrasound due to elevation in liver enzymes over past year - Decrease in activity gradually over past few months, some tremors noted when on walks - On Carprofen PRN and Glucosamine supplement - No V/D/C/S, E/D normal
SPECIES	
Canine	Abnormal PE/Chem/CBC/UA Results: 4/11/25 - TP - 8.2, Albumin - 4.8, AST - 144, ALKP - 482, ALT - 333, Phosphorus - 6.7, Ca - 11.9 10/9/25 - Tp - 7.6, ALT - 198, ALKP - 518, Ca- 11.8
BREED	ULTRASONOGRAPHIC EXAMINATION OF THE ABDOMEN
Mini Schnauzer	Urinary System
SEX	The urinary bladder, trigone, cystourethral junction, and visible pelvic urethra to a depth of 4.0 cm exhibited normal thickness and tone. Anechoic urine was present in the lumen with no uroliths or sediment. The ureteral papillae were normal. The ureters were not visible which is normal. No evidence of inflammatory or neoplastic change were noted.
Neutered Male	
AGE	No overt pathology in the area of the residual prostate.
11 Years	The area of the aortic trifurcation was free of pathology.
WEIGHT	Normal size and margination was present in the kidneys. A normal 1:3 cortex / medulla ratio was maintained. The medulla and cortices were uniform in texture with some increased echogenicity and mild loss of corticomedullary symmetry and definition expected for the age of the patient. A small medial cortical cyst was visualized in the left kidney. The left kidney measured 5.3 cm in length. The right kidney measured 5.1 cm in length.
16.2 pounds	
INTERPRETED BY	Adrenal Glands
R. McKenzie Daniel, DVM, DABVP	The adrenal glands were indistinctly visualized yet borderline prominent in subjective size exhibiting primarily symmetrical contour and mild nonhomogenous nonmineralized parenchyma. The left adrenal gland measured 0.67 cm width at the caudal pole. The right adrenal gland measured 0.65 cm width at the caudal pole.
IMAGING PERFORMED BY	Spleen
Christina CVT	The spleen exhibited a finely textured and homogenous parenchyma which was hyperechoic to the liver and renal cortical parenchyma. The capsule was smooth and regular without apparent expansion. The splenic vasculature at the hilus was normal in volume with no evidence of congestion or thrombosis. Acute to chronic inflammatory, neoplastic, or benign parenchyma changes were not noted.
HOSPITAL NAME	Liver
Animal Health Veterinary Clinic	The liver revealed generalized hepatomegaly. The liver parenchyma was mildly nonuniform and hypoechoic to the spleen with a moderate coarse echotexture and subjective mild parenchymal remodeling. Indistinct portal vascular borders without signs of congestion.
REFERRING VET	The gallbladder was non distended in size with mild nonorganized primarily cranial lumen biliary sludge. The common bile duct was not visualized.
Dr. Collazos	Gastrointestinal
INVOICE	
12047	
DATE	
11/04/25	



PATIENT

Max Neiman

The stomach presented intact wall layering with a normal wall layer ratio. The lumen of the stomach was empty with no signs of ileus, obstruction or foreign material.

SPECIES

Canine

The small intestine presented intact wall layering with 1:3 muscularis/mucosa ratio. The lumen of the small intestine was empty with no signs of ileus, obstruction or foreign material.

BREED

Mini Schnauzer

Normal visible colon wall layers were present with apparent formed feces in lumen.

Pancreas

The pancreas was normal in size and contour with isoechoic mildly heterogeneous parenchyma compared to adjacent omentum. No signs of active inflammation or neoplasia.

SEX

Neutered Male

Free Abdomen

No overt lymphadenopathy or peritoneal effusion was present.

AGE

11 Years

ULTRASONOGRAPHIC FINDINGS

- Nonspecific yet subjective benign hepatopathy.
- Mild nonorganized gallbladder debris (non-mucocele).
- Age-related renal changes.
- Subjective borderline bilateral adrenomegaly- benign.

WEIGHT

16.2 pounds

INTERPRETATION OF THE FINDINGS & FURTHER RECOMMENDATIONS

The appearance of the liver was nonspecific but most consistent with benign hepatopathy. Considerations for the liver may include benign vacuolar hepatopathy, inflammatory/infectious/immune mediated disease, hyperplasia, hematopoiesis, toxic hepatopathy (i.e. copper), other with neoplasia thought less likely. Ultrasound guided FNA of the liver using a 25-gauge needle and assuming normal coagulation parameters would be warranted for screening cytology. Hepatosupportive medications such as Denamarin or Vitamin E as well as Ursodiol due to its antioxidant and immunomodulatory effects within the liver would be warranted, although these medications may not result in decreased hepatic enzyme levels. Leptospirosis titers / PCR may be considered if clinically indicated. Core or surgical biopsy likely required for definitive diagnosis. Adrenal screening could be considered if nonreported or future clinical signs are suggestive of Cushing's syndrome.

INTERPRETED BY

R. McKenzie Daniel, DVM, DABVP

IMAGING PERFORMED BY

Christina CVT

HOSPITAL NAME

Animal Health Veterinary Clinic

REFERRING VET

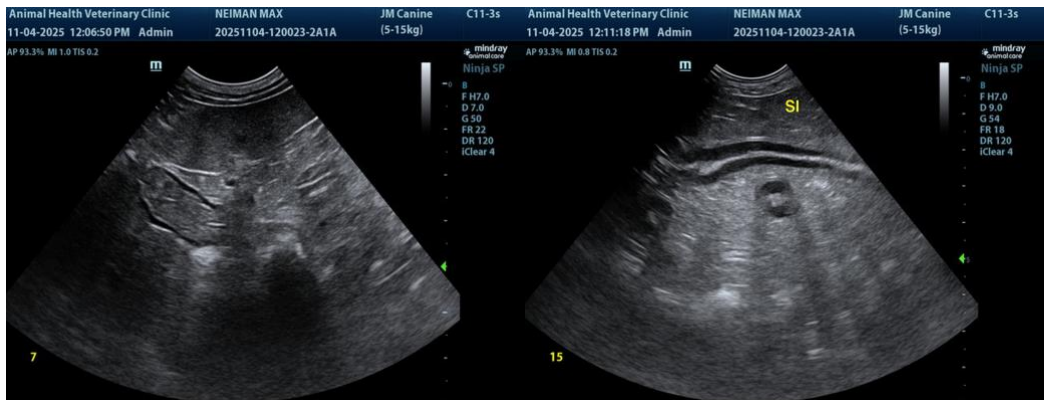
Dr. Collazos

INVOICE

12047

DATE

11/04/25





PATIENT

Max Neiman

SPECIES

Canine

BREED

Mini Schnauzer

SEX

Neutered Male

AGE

11 Years

WEIGHT

16.2 pounds

INTERPRETED BY

R. McKenzie Daniel,
DVM, DABVP

IMAGING PERFORMED BY

Christina CVT

HOSPITAL NAME

Animal Health
Veterinary Clinic

REFERRING VET

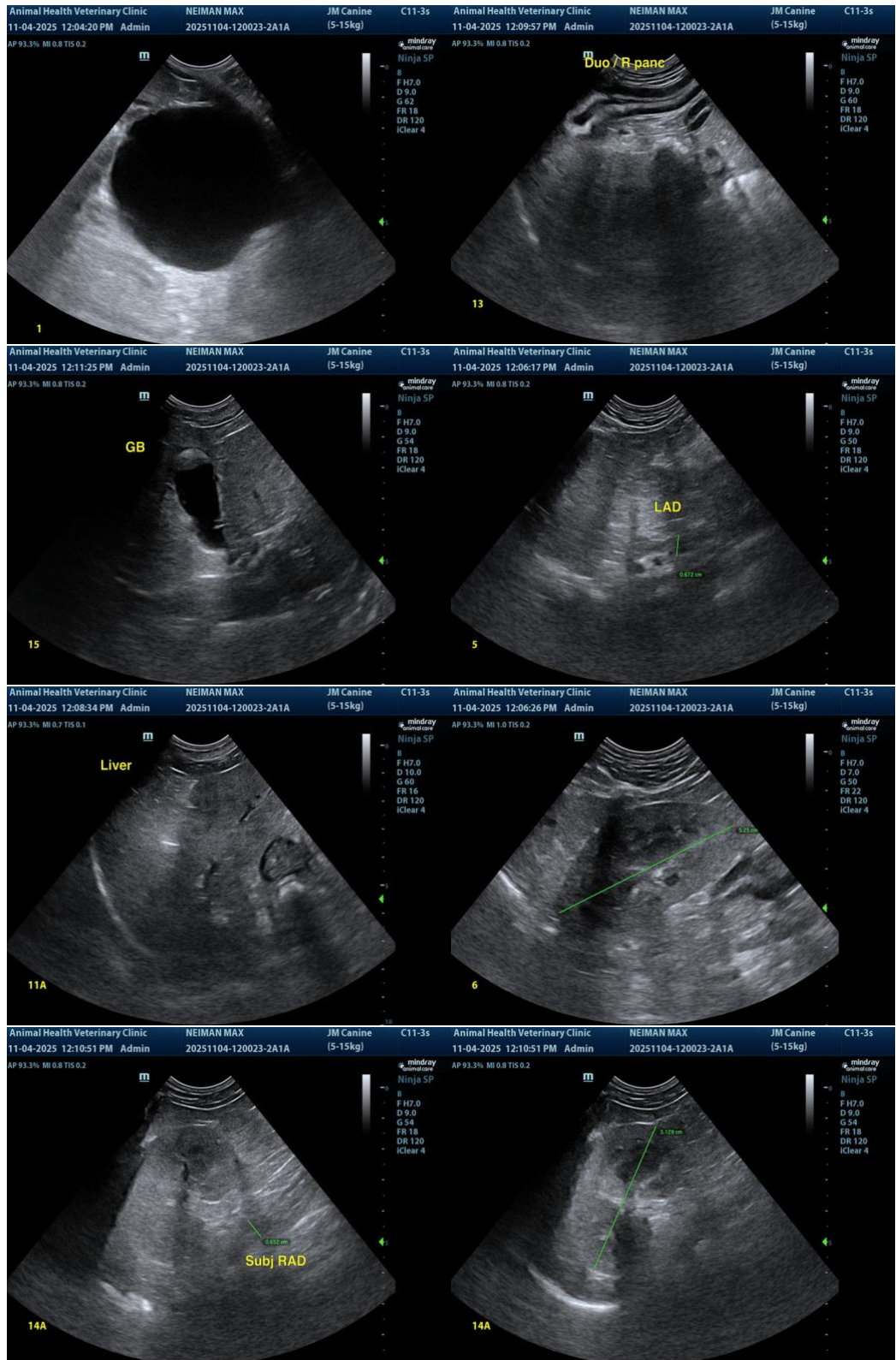
Dr. Collazos

INVOICE

12047

DATE

11/04/25





PATIENT

Max Neiman

SPECIES

Canine

BREED

Mini Schnauzer

SEX

Neutered Male

AGE

11 Years

WEIGHT

16.2 pounds

INTERPRETED BY

R. McKenzie Daniel,
DVM, DABVP

IMAGING PERFORMED BY

Christina CVT

HOSPITAL NAME

Animal Health
Veterinary Clinic

REFERRING VET

Dr. Collazos

INVOICE

12047

DATE

11/04/25

The information and recommendations provided are based on the images presented by the referring veterinarian/sonographer. No evaluation can be communicated regarding pathology that was not visible in the image/video clips provided.

Thank you for this referral. If the clinical or image interpretation does not parallel your findings or if I can be of any further assistance, please contact me.

R. McKenzie Daniel, DVM, DABVP (Canine / Feline Practice)

info@SonoPath.com