

**PATIENT**

Peanut Arnold

SPECIES

Canine

BREED

Chihuahua

SEX

SF

AGE

9 years

WEIGHT

8 lbs.

INTERPRETED BY

R. McKenzie Daniel,
DVM, DABVP
(Canine and Feline)

IMAGING PERFORMED BY

Sarah Pender, CVT

HOSPITAL NAME

SVS Imaging QC

REFERRING VET

Dr. Kim Springman

INVOICE

15403

DATE

11/4/22

PRESENTING CLINICAL SIGNS

Pendulous abdomen
Abnormal PE/Chem/CBC/UA Results: Bw wnl

ULTRASONOGRAPHIC EXAMINATION OF THE ABDOMEN**Urinary System**

The urinary bladder, trigone, cystourethral junction, and visible pelvic urethra to a depth of 2.0 cm exhibited normal thickness and tone. Anechoic urine was present in the lumen with no uroliths or sediment. The ureteral papillae were normal. The ureters were not visible which is normal. No evidence of inflammatory or neoplastic changes was noted.

No evidence of pathology was noted in the area of the uterine remnant.

The area of the aortic trifurcation was free of pathology.

Normal size and margination were present in the kidneys. A normal 1:3 cortex / medulla ratio and normal corticomedullary definition were maintained. The echogenicity of the cortex was similar to or slightly less than normal liver parenchyma while the medulla echogenicity was hypoechoic to the cortex with no evidence of pelvic dilation. The left kidney measured 3.5 cm in length. The right kidney measured 3.9 cm in length.

Adrenal Glands

The left adrenal gland was uniform in size and contour with a uniformly hypoechoic parenchyma. The left adrenal gland measured 1.4 cm length x 0.53 cm width at the caudal pole. The right adrenal gland was uniform in size and contour with a uniformly hypoechoic parenchyma. The right adrenal gland measured 1.5 cm length x 0.43 cm width at the caudal pole.

Spleen

The spleen exhibited subjective borderline to mild enlargement with a finely textured and homogenous parenchyma which was hyperechoic to the liver and renal cortical parenchyma. The capsule was smooth and regular without apparent expansion. The splenic vasculature at the hilus was normal in volume with no evidence of congestion or thrombosis. Acute to chronic inflammatory, neoplastic, or benign parenchyma changes were not noted. Normal splenic vascularity was present. No masses or nodules were noted.

Liver/ Gallbladder

The liver was subjectively normal in size, structure, and contour. The liver parenchyma was uniform and hypoechoic to the spleen with a mild coarse echotexture. The hepatic and portal vasculature were normal in appearance without signs of congestion. The gallbladder was non-distended in size with thin walls and primarily anechoic luminal content. The cystic and common bile ducts were normal.

Gastrointestinal

The stomach presented intact wall layering with a normal wall layer ratio. Mild to moderate retained anechoic fluid was present without evidence of retained gastric ingesta, or mechanical pyloric outflow obstruction.

**PATIENT**

Peanut Arnold

The small intestine presented intact wall layering with 1:3 muscularis/mucosa ratio. The lumen of the small intestine was empty with no signs of ileus, obstruction, or foreign material.

Normal visible colon wall layers were present with apparent formed feces in lumen.

SPECIES

Canine

Pancreas

The parenchyma of the left limb, body, and right limb of the pancreas presented isoechoic to the adjacent omental fat. A normal curvilinear capsule contour of the pancreas was present. The visible pancreatic duct was normal. No signs of active inflammation or neoplastic disease were evident.

BREED

Chihuahua

Free Abdomen

No omental masses, lymphadenopathy, or peritoneal free fluid were noted.

SEX

SF

ULTRASONOGRAPHIC FINDINGS

- Subjective borderline to mild splenomegaly - benign
- Possible mild gastric hypomotility

AGE

9 years

INTERPRETATION OF THE FINDINGS & FURTHER RECOMMENDATIONS

Overall, no evidence of significant visceral pathology, including no evidence of intraabdominal neoplastic criteria, lymphadenopathy, or peritoneal free fluid.

WEIGHT

8 lbs.

The potential borderline to mild splenomegaly is nonspecific with potential for patient variant or splenomegaly secondary to sedation if applicable. Potential for incidental minor splenic hyperplasia, hematopoiesis, or incidental splenitis is possible. Screening FNA splenic cytology could be considered if persistent splenomegaly or if evidence of weight loss.

INTERPRETED BY

R. McKenzie Daniel,
DVM, DABVP
(Canine and Feline)

Gastroprotectant protocol is suggested if clinical signs suggestive of gastritis are present. Three-view chest radiographs if not done, may be considered to assess for or rule out occult thoracic pathology and assess cardiopulmonary status.

IMAGING PERFORMED BY

Sarah Pender, CVT

HOSPITAL NAME

SVS Imaging QC

REFERRING VET

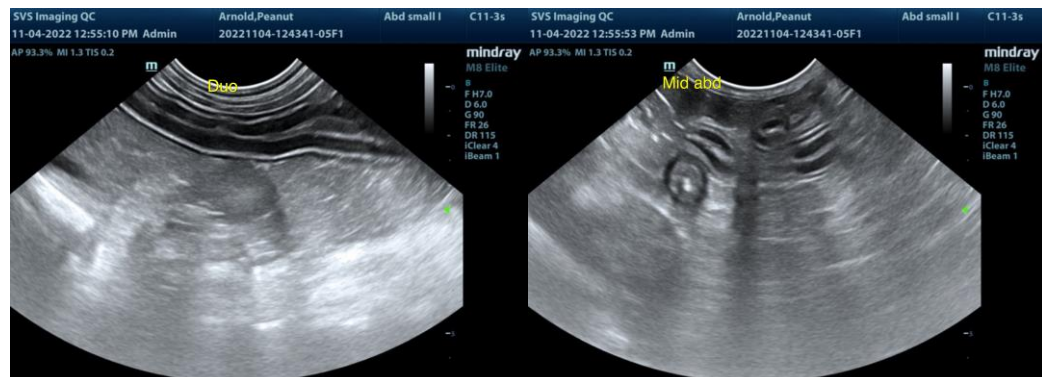
Dr. Kim Springman

INVOICE

15403

DATE

11/4/22





PATIENT

Peanut Arnold

SPECIES

Canine

BREED

Chihuahua

SEX

SF

AGE

9 years

WEIGHT

8 lbs.

INTERPRETED BY

R. McKenzie Daniel,
DVM, DABVP
(Canine and Feline)

IMAGING PERFORMED BY

Sarah Pender, CVT

HOSPITAL NAME

SVS Imaging QC

REFERRING VET

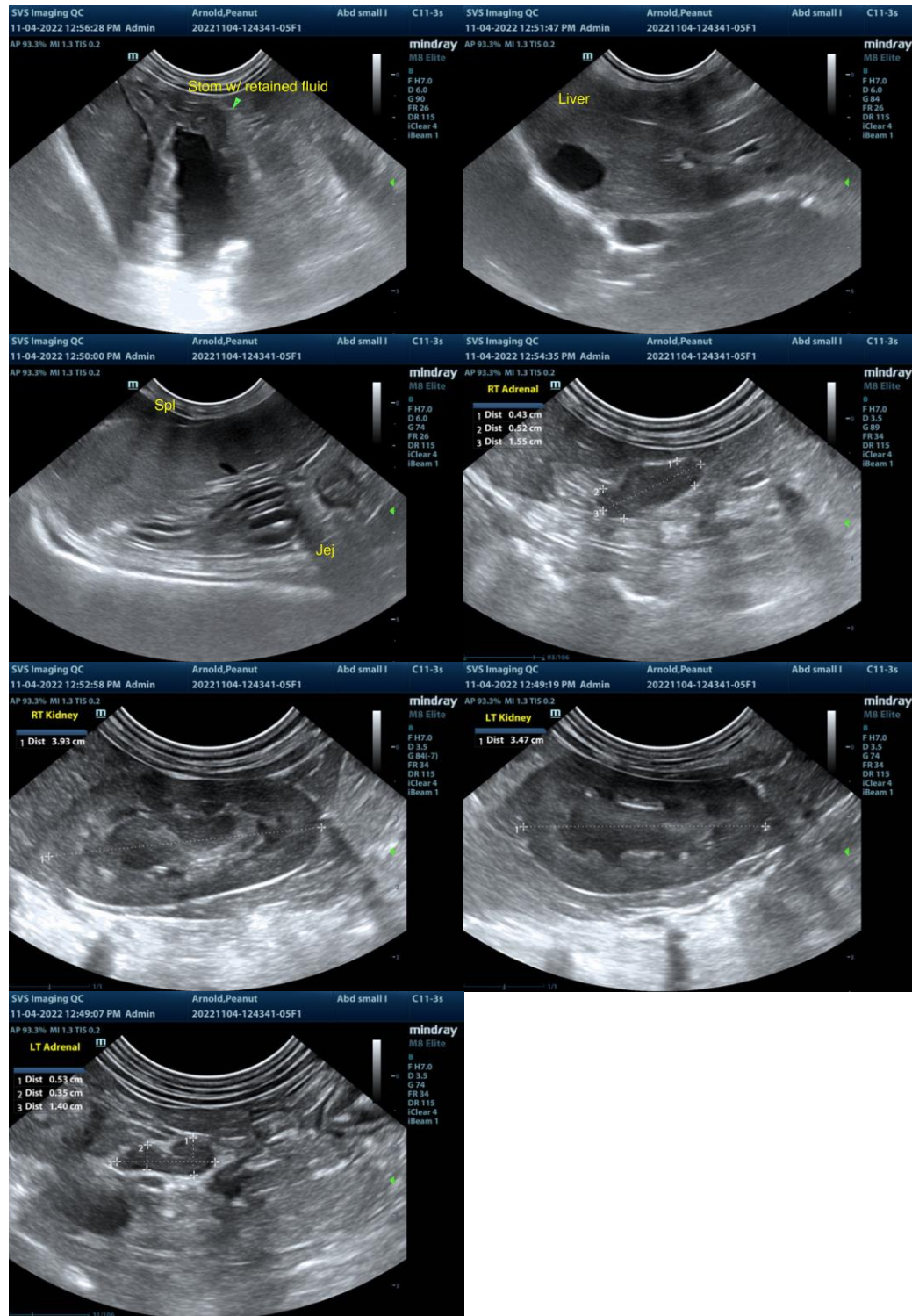
Dr. Kim Springman

INVOICE

15403

DATE

11/4/22



The information and recommendations provided are based on the images presented by the referring veterinarian/sonographer. No evaluation can be communicated regarding pathology that was not visible in the image/video clips provided.

IMAGING PERFORMED BY

svsmobileimaging.com 309-737-3070



Clinical Sonography & Telecytology

EDUCATIONAL TELECONSULTATION SERVICES™

1-800-838-4268 info@sonopath.com SonoPath.com

PATIENT

Peanut Arnold

Thank you for this referral. If the clinical or image interpretation does not parallel your findings or if I can be of any further assistance please contact me.

SPECIES

Canine

R. McKenzie Daniel, DVM, DABVP (Canine / Feline Practice)
info@SonoPath.com

BREED

Chihuahua

SEX

SF

AGE

9 years

WEIGHT

8 lbs.

INTERPRETED BY

R. McKenzie Daniel,
DVM, DABVP
(Canine and Feline)

**IMAGING
PERFORMED BY**

Sarah Pender, CVT

HOSPITAL NAME

SVS Imaging QC

REFERRING VET

Dr. Kim Springman

INVOICE

15403

DATE

11/4/22