



**PATIENT PRESENTING CLINICAL SIGNS**

Maggie Bruno Suspected vasovagal syncope, ventricular arrhythmia.  
 Unremarkable CBC, Chemistry panel- ALP 250, BUN 42, Creatinine 1.5, Na/K ratio 37

**SPECIES ULTRASONOGRAPHIC EXAMINATION OF THE ABDOMEN**

Canine **Urinary System**

**BREED** The urinary bladder, trigone, cystourethral junction, and visible pelvic urethra to a depth of 2.0 cm exhibited normal thickness and tone. Anechoic urine was present in the lumen with no uroliths or sediment. The ureteral papillae were normal. The ureters were not visible which is normal. No evidence of inflammatory or neoplastic changes was noted.

American Eskimo

**SEX** The area of the aortic trifurcation was free of pathology.

FS Normal size and margination were present in the left kidney. A normal 1:3 cortex / medulla ratio was maintained. The medulla and cortices were uniform in texture with some increased echogenicity and mild loss of corticomedullary symmetry and definition expected for the age of the patient. No evidence of pelvic dilation was present. The left kidney measured 4.2 cm in length.

**AGE** 2007

**WEIGHT** 16.8 Mild subnormal right kidney compared to the left was noted with asymmetrical margination. A normal 1:3 cortex / medulla ratio was maintained. The medulla and cortices were uniform in texture with some increased echogenicity and moderate loss of corticomedullary symmetry and definition expected for the age of the patient. Likely right kidney cortical infarcts were noted. Right kidney pinpoint medullary mineral was noted. No evidence of pelvic dilation was present. The right kidney measured 3.8 cm in length.

**INTERPRETED BY**

R. McKenzie Daniel,  
 DVM, DABVP  
 (Canine and Feline)

**Adrenal Glands**

The left adrenal gland was uniform in size and contour with a uniformly hypoechoic parenchyma. The left adrenal gland measured 1.9 cm length x 0.60 cm width at the caudal pole. The right adrenal gland was not definitively visualized.

**IMAGING PERFORMED BY**  
 Rebekah Jakum, CVT  
 ARDMS/RVT

**Spleen**

The spleen exhibited primarily finely textured parenchyma which was hyperechoic to the liver and renal cortical parenchyma. Mild generalized parenchyma heterogeneity was present without evidence of nodular changes. The capsule was smooth and regular without apparent expansion. The splenic vasculature at the hilus was normal in volume with no evidence of congestion or thrombosis. The parenchymal heterogeneity is likely consistent with benign changes such as extramedullary hematopoiesis or age-related remodeling with minor potential for inflammatory or neoplastic disease.

**HOSPITAL NAME**

Littlestown VH

**REFERRING VET**

Dr. Jennings

**Liver/ Gallbladder**

**INVOICE** 15392 The liver was mildly enlarged in size with normal structure and contour. The liver parenchyma was mildly nonuniform and hypoechoic to the spleen with a moderate coarse echotexture and subjective mild to benign parenchymal remodeling. The hepatic and portal vasculature were normal in appearance without signs of congestion.

**DATE**  
 11/4/22



**PATIENT**

Maggie Bruno

The gallbladder was non-distended in size with moderate nondependent to dependent, variably echogenic, nonorganized, gallbladder debris. A small aspect of the gallbladder debris appeared to have adhered to the inner luminal wall. No evidence of peripheral gallbladder inflammatory criteria was noted. The cystic and common bile ducts were normal.

**SPECIES**

Canine

**Gastrointestinal**

The stomach presented intact wall layering with a normal wall layer ratio. The lumen of the stomach was empty with no signs of ileus, obstruction, or foreign material.

**BREED**

American Eskimo

The small intestine presented intact wall layering with 1:3 muscularis/mucosa ratio. The lumen of the small intestine was empty with no signs of ileus, obstruction, or foreign material.

**SEX**

FS

Normal visible colon wall layers were present with apparent formed feces in lumen.

**Pancreas**

**AGE**

2007

The pancreas was normal in size and contour with isoechoic to heterogeneous parenchyma compared to adjacent omentum, likely consistent with age-related pancreatic changes. No signs of active inflammation or neoplasia.

**Free Abdomen**

**WEIGHT**

16.8

No overt lymphadenopathy or peritoneal effusion was present.

**ULTRASONOGRAPHIC FINDINGS**

- Mild hepatic parenchymal remodeling, subjective benign vacuolar hepatopathy pattern
- Moderate gallbladder debris - possible very early gallbladder mucocele
- Bilateral chronic renal changes more prominent in the right kidney with evidence of cortical infarcts

**INTERPRETED BY**

R. McKenzie Daniel,  
DVM, DABVP  
(Canine and Feline)

**INTERPRETATION OF THE FINDINGS & FURTHER RECOMMENDATIONS**

Largely geriatric abdomen without evidence of significant visceral pathology.

Further renal staging to include urine C/S and protein: creatinine ratio on sterile urine sample may be considered. Hepatosupportive medications including Denamarin and Ursodiol may be considered if evidence of increasing liver enzymes or cholestasis.

**IMAGING PERFORMED BY**

Rebekah Jakum, CVT  
ARDMS/RVT

**HOSPITAL NAME**

Littlestown VH

**REFERRING VET**

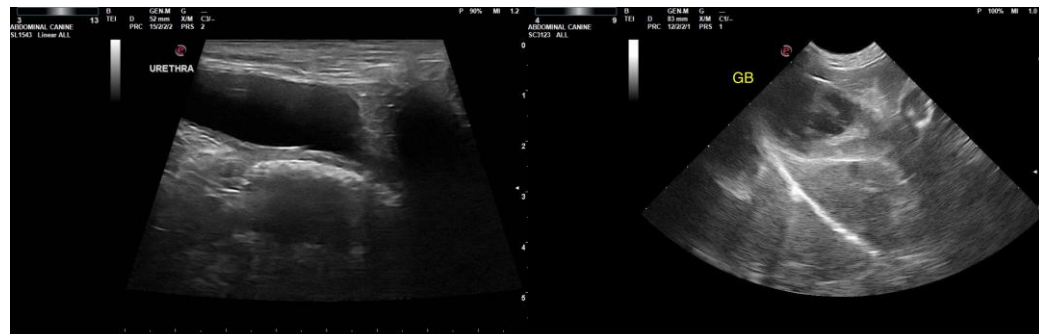Dr. Jennings

**INVOICE**

15392

**DATE**

11/4/22





**PATIENT**

Maggie Bruno

**SPECIES**

Canine

**BREED**

American Eskimo

**SEX**

FS

**AGE**

2007

**WEIGHT**

16.8

**INTERPRETED BY**

R. McKenzie Daniel,  
DVM, DABVP  
(Canine and Feline)

**IMAGING  
PERFORMED BY**

Rebekah Jakum, CVT  
ARDMS/RVT

**HOSPITAL NAME**

Littlestown VH

**REFERRING VET**

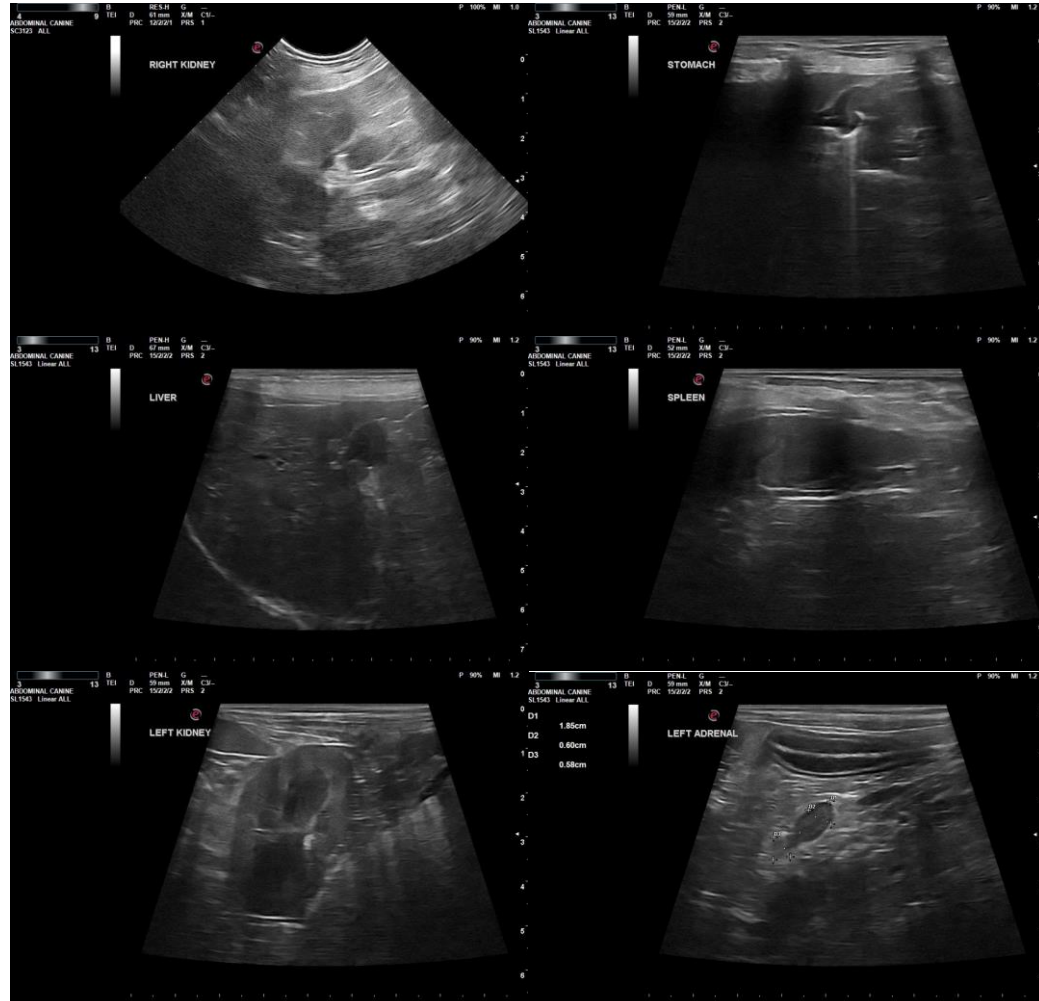
Dr. Jennings

**INVOICE**

15392

**DATE**

11/4/22



The information and recommendations provided are based on the images presented by the referring veterinarian/sonographer. No evaluation can be communicated regarding pathology that was not visible in the image/video clips provided.

Thank you for this referral. If the clinical or image interpretation does not parallel your findings or if I can be of any further assistance, please contact me.

**R. McKenzie Daniel, DVM, DABVP (Canine/Feline Practice)**  
[mac.daniel@sonopath.com](mailto:mac.daniel@sonopath.com)