



PATIENT

Leroy Crater

SPECIES

Canine

BREED

Coonhound Mix

SEX

MN

AGE

3 yrs

WEIGHT

64.2 lbs.

INTERPRETED BY

R. McKenzie Daniel,
DVM, DABVP
(Canine and Feline)

IMAGING PERFORMED BY

Shari Reffi, CVT

HOSPITAL NAME

Byram AH

REFERRING VET

Dr. Carlos Abdul-Chani

INVOICE

15380

DATE

11/4/22

PRESENTING CLINICAL SIGNS

Mildly elevated pro BNP, no clinical signs.
Abnormal PE/Chem/CBC/UA Results: proBNP 1067

ULTRASONOGRAPHIC EXAMINATION OF THE HEART

CANINE	MR	TR	LA/AO	LA/AO	FS	EF	EPSS
CARDIAC PARAMETERS	VMAX (m/s)	VMAX (m/s)	(Boon method)	(Heart Base; Swe)	(%)	(%)	(cm)
NORMAL PARAMETER	4.5-5.5	<2.7	1.3	<1.3	28-40	40-100	<0.6
PATIENT				1.3	44	76	0.3
CANINE	HR	AV	PV	BODY WEIGHT	LA	LVIDd	LVIDs
CARDIAC PARAMETERS	(BPM)	VMAX (m/s)	MAX (m/s)	(kg)	2D short axis Base view (cm)	Avg; 2D and m-mode short axis (cm)	Avg; 2D and m-mode short axis (cm)
NORMAL PARAMETER	50-100	0.7-1.7	0.7-1.6				
PATIENT	129	1.4	1.2		3.7	3.4	

Cardiac Presentation

The echocardiogram in this patient demonstrated normal **left atrial** size based on 3 separate methods of LA evaluation. The cranial and caudal **mitral** valve leaflets presented normal linear structure, extension in systole, and union in diastole with normal kinesis. The **left ventricle** presented thicknesses with linear contour and was not dilated nor restricted. The **myocardium** presented normal echogenicity without subjective evidence of significant fibrotic or ischemic disease. **Contractility** of the ventricular walls was adequate and in normal range for this patient evidenced by the fractional shortening measurement and subjective evaluation of the different regions of the myocardium. The **left ventricular outflow** tract demonstrated normal laminar flow and subjective structural integrity. Normal LVOT velocity was present. The **right atrium** and auricle revealed normal size, structure and content. No evidence of masses was noted. **Tricuspid** valvular assessment demonstrated adequate linear morphology and kinesis. The **right ventricle** was of normal size (1/3 diameter of LV), chordae structure, myocardial echogenicity and thickness. **Pulmonary outflow** tract assessment revealed normal valve structure, laminar flow, and diameter (approx. 1:1 pa/ao ratio). No visible **pericardial** or free pleura fluid was noted. Normal RVOT velocity was present. The cranial **mediastinum and pericardial and extra-cardiac regions** were free of masses in the visible window.

ULTRASONOGRAPHIC FINDINGS

- Normal echocardiogram



PATIENT

Leroy Crater

SPECIES

Canine

BREED

Coonhound Mix

SEX

MN

AGE

3 yrs

WEIGHT

64.2 lbs.

INTERPRETED BY

R. McKenzie Daniel,
DVM, DABVP
(Canine and Feline)

IMAGING PERFORMED BY

Shari Reffi, CVT

HOSPITAL NAME

Byram AH

REFERRING VET

Dr. Carlos Abdul-
Chani

INVOICE

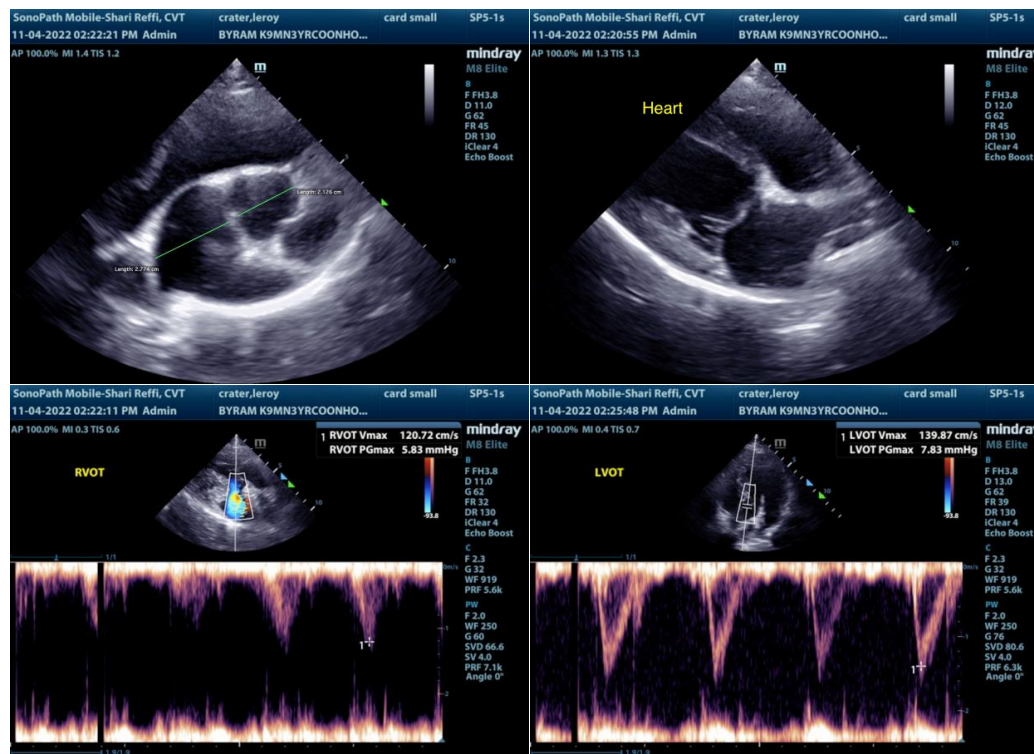
15380

DATE

11/4/22

INTERPRETATION OF THE FINDINGS & FURTHER RECOMMENDATIONS

No evidence of structural or functional cardiomyopathy was present.



The information and recommendations provided are based on the images presented by the referring veterinarian/sonographer. No evaluation can be communicated regarding pathology that was not visible in the image/video clips provided.

Thank you for this referral. If the clinical or image interpretation does not parallel your findings or if I can be of any further assistance please contact me.

R. McKenzie Daniel, DVM, DABVP (Canine / Feline Practice)
info@SonoPath.com