



PATIENT PRESENTING CLINICAL SIGNS

Tucker Woodcock

History: suspected mass in chest and abd currently on meloxyn

SPECIES

Canine

Abnormal PE/Chem/CBC/UA Results: please see attached BW and rads

ULTRASONOGRAPHIC EXAMINATION OF THE HEART & ABDOMEN

BREED

Eng Bulldog

SEX

Neutered Male

AGE

10 Years

WEIGHT

25 kg

CANINE CARDIAC PARAMETERS	MR VMAX (m/s)	TR VMAX (m/s)	LA/AO (Boon method)	LA/AO (Heart Base; Swe)	FS (%)	EF (%)	EPSS (cm)
NORMAL PARAMETER	4.5-5.5	<2.7	1.3	<1.6	28-40	40-100	<0.6
PATIENT	--	--	--	1.95	27.7	57.7	0.56
CANINE CARDIAC PARAMETERS	HR (BPM)	AV VMAX (m/s)	PV MAX (m/s)	BODY WEIGHT (kg)	LA 2D short axis Base view (cm)	LVIDd Avg; 2D and m-mode short axis (cm)	LVIDs Avg; 2D and m-mode short axis (cm)
NORMAL PARAMETER	50-100	0.7-1.7	0.7-1.6	BELOW	BELOW	BELOW	BELOW
PATIENT	160	NM	NM	--	5.0	4.9	--

INTERPRETED BY

R. McKenzie Daniel, DVM,
DABVP (Canine and
Feline)

IMAGING PERFORMED BY

Kelly Reschny

HOSPITAL NAME

Wellington AH

REFERRING VET

Dr. Dennis

INVOICE

12734

DATE

11/30/21

Cardiac Presentation

The echocardiogram in this patient demonstrated moderately enlarged **left atrial** size based on 2 different methods of LA evaluation. The cranial and caudal **mitral** valve leaflets presented mild vegetative thickening with mild insufficiency noted on color doppler assessment. The **left ventricle** presented thicknesses with linear contour with mild increased left ventricle volume. The **myocardium** presented normal echogenicity without subjective evidence of significant fibrotic or ischemic disease. **Contractility** of the ventricular walls was subnormal as evidence by the fractional shortening measurement and subjective evaluation in different regions of the myocardium. The **left ventricular outflow** tract demonstrated normal laminar flow and subjective structural integrity. The **right atrium** and auricle revealed increased size comparable to the left atrium. Soft tissue structure noted potentially within the right atrium lumen and adjacent to the tricuspid valve was present. The overall **tricuspid** valve appeared to be sonographically unremarkable with normal kinesis. The **right ventricle** exhibited increased volume compared to the left ventricle with normal myocardial echogenicity and thickness. **Pulmonary outflow** tract assessment revealed normal valve structure, laminar flow, and diameter (approx.1:1 pa/ao ratio). Large expansive primarily homogeneous mass which appeared to be associated with the heart base extending cranially into the area of the cranial mediastinum and thorax, measuring approximately 8.5 cm in diameter was present. Potential for mild pericardial and free pleural fluid noted.

Urinary System

The urinary bladder, trigone, cystourethral junction, and visible pelvic urethra to a depth of 3.0 cm exhibited normal thickness and tone. Anechoic urine was present in the lumen with no uroliths or



PATIENT

Tucker Woodcock

sediment. The ureteral papillae were normal. The ureters were not visible which is normal. No evidence of inflammatory or neoplastic changes were noted.

No overt pathology in the area of the residual prostate.

SPECIES

Canine

Aortic trifurcation was normal.

Normal size and margination were present in the kidneys. A normal 1:3 cortex / medulla ratio was maintained. The medulla and cortices were uniform in texture with some increased echogenicity and mild to moderate loss of corticomedullary symmetry and definition expected for the age of the patient. No evidence of pelvic dilation was present. The left kidney measured 5.9 cm in length. The right kidney measured 6.1 cm in length.

BREED

Eng Bulldog

Adrenal Glands

SEX

Neutered Male

The left adrenal gland was uniform in size and contour with a uniformly hypoechoic parenchyma. The left adrenal gland measured 2.4 cm in length x 0.82 cm width at the caudal pole.

The right adrenal gland was indistinctly visualized without overt pathology, subjectively measuring 0.91 cm at the caudal pole.

AGE

10 Years

Spleen

The spleen exhibited primarily finely textured parenchyma which was hyperechoic to the liver and renal cortical parenchyma. Mild generalized parenchyma heterogeneity was present without evidence of nodular changes. The capsule was smooth and regular without apparent expansion. The splenic vasculature at the hilus was normal in volume with no evidence of congestion or thrombosis. The parenchymal heterogeneity is likely consistent with benign changes such as extramedullary hematopoiesis or age-related remodeling with minor potential for inflammatory or neoplastic disease.

WEIGHT

25 kg

INTERPRETED BY

R. McKenzie Daniel, DVM,
DABVP (Canine and
Feline)

Liver

The liver exhibited marked generalized enlargement, symmetrical to swollen contour and generalized non-uniformly echogenic parenchyma. A focal non-homogeneous intraparenchymal nodule was noted in the mid to right liver, measuring 1.9 cm in diameter. The hepatic and portal vasculature were normal in appearance without signs of congestion.

**IMAGING
PERFORMED BY**

Kelly Reschny

The gallbladder was normal, although displaced caudally owing to hepatomegaly.

HOSPITAL NAME

Wellington AH

Gastrointestinal

The stomach presented intact wall layering with a normal wall layer ratio. The lumen of the stomach was empty with no signs of ileus, obstruction or foreign material.

REFERRING VET

Dr. Dennis

The small intestine presented intact wall layering with 1:3 muscularis/mucosa ratio. The lumen of the small intestine was empty with no signs of ileus, obstruction or foreign material.

Normal visible colon wall layers were present with apparent formed feces in lumen.

INVOICE

12734

Pancreas

The parenchyma of the left limb, body and right limb of the pancreas presented isoechoic to the adjacent omental fat. A normal curvilinear capsule contour of the pancreas was present. The visible pancreatic duct was normal. No signs of active inflammation or neoplastic disease was evident.

DATE

11/30/21



PATIENT *Free Abdomen*

Tucker Woodcock No overt lymphadenopathy or peritoneal effusion.

SPECIES **ULTRASONOGRAPHIC FINDINGS**

Canine

- Large expansive heart base to cranial mediastinal mass
- Increased left ventricle volume with subnormal systolic function

BREED

Eng Bulldog

- Enlarged LA
- Enlarged RA/RV

SEX

Neutered Male

- Severe hepatomegaly exhibiting generalized non-uniformly echogenic to focally nodular parenchyma
- Mild chronic renal changes

AGE

10 Years

INTERPRETATION OF THE FINDINGS & FURTHER RECOMMENDATIONS

The study confirms the presence of a large expansive mass in the area of the heart base and cranial mediastinum with potential expansion into the cranial thorax. Definitive origin of the mass was unable to be determined given its size and location. Regardless, the mass is consistent with neoplastic criteria. Concurrent cardiomyopathy was present. Potential thrombus formation within the right heart structures or potential extension of the mass into the area of the right heart may be possible. The hepatomegaly and hepatoparenchymal changes may represent a separate pathology or entity such as metabolic reactive, vacuolar or inflammatory hepatopathy with parenchymal remodeling, focal area of hematopoiesis, nodular to regenerative hyperplasia, lipogranuloma, early fibrosis or other hepatopathy. However, the possibility of primary versus metastatic hepatic neoplasia cannot be excluded. Further assessment would include sampling of the heart base to cranial mediastinal mass as well as the liver for further clarification. However, given the size and extensiveness of the heart base to cranial mediastinal mass, therapeutic options are likely limited. AN unfavorable prognosis is unfortunately indicated.

WEIGHT

25 kg

INTERPRETED BY

R. McKenzie Daniel, DVM,
DABVP (Canine and
Feline)

**IMAGING
PERFORMED BY**

Kelly Reschny

HOSPITAL NAME

Wellington AH

REFERRING VET

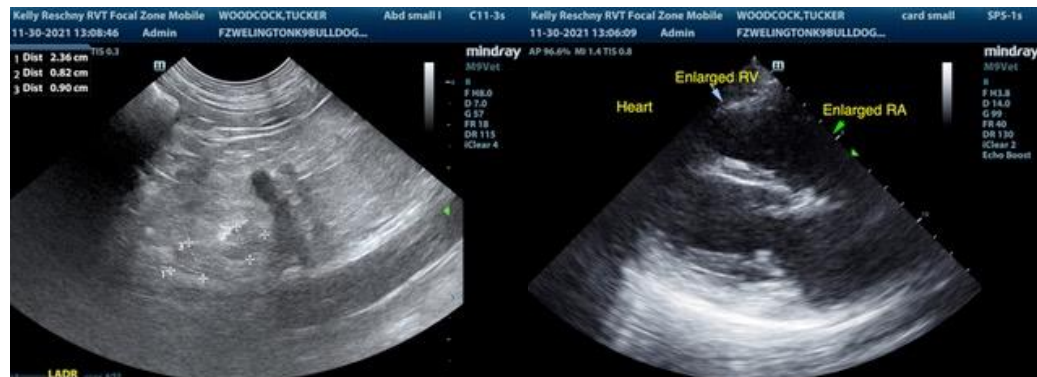Dr. Dennis

INVOICE

12734

DATE

11/30/21





PATIENT

Tucker Woodcock

SPECIES

Canine

BREED

Eng Bulldog

SEX

Neutered Male

AGE

10 Years

WEIGHT

25 kg

INTERPRETED BY

R. McKenzie Daniel, DVM,
DABVP (Canine and
Feline)

**IMAGING
PERFORMED BY**

Kelly Reschny

HOSPITAL NAME

Wellington AH

REFERRING VET

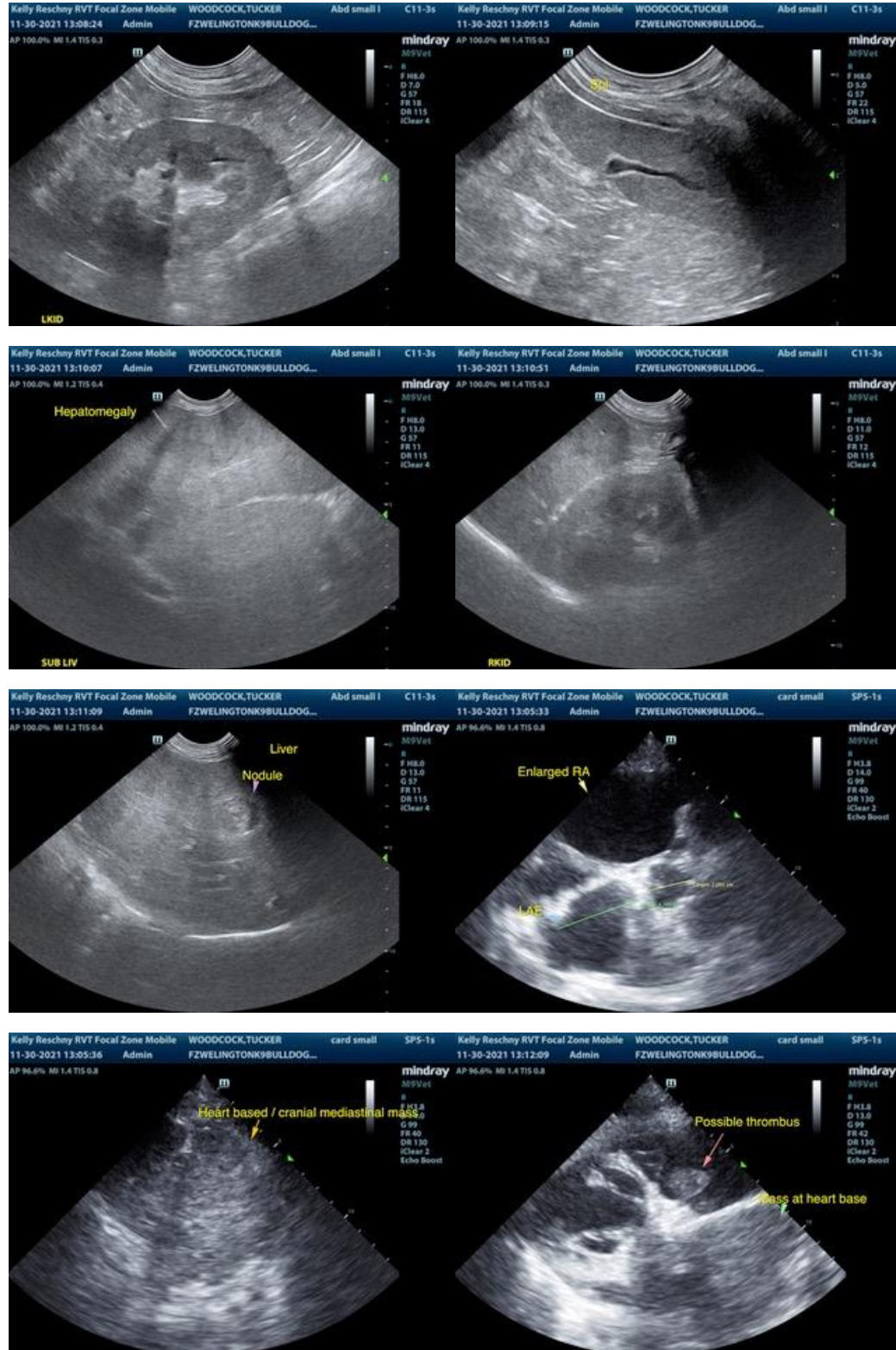
Dr. Dennis

INVOICE

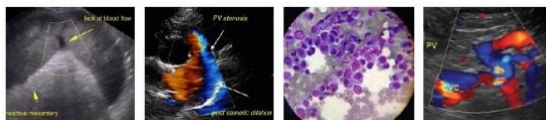
12734

DATE

11/30/21



The information and recommendations provided are based on the images presented by the referring veterinarian. No evaluation can be communicated regarding pathology that was not visible in the image/video clips provided.



PATIENT

Tucker Woodcock

Thank you for this referral. If the clinical or image interpretation does not parallel your findings or if I can be of any further assistance please contact me.

SPECIES

Canine

R. McKenzie Daniel, DVM, DABVP (Canine / Feline Practice)
info@SonoPath.com

BREED

Eng Bulldog

SEX

Neutered Male

AGE

10 Years

WEIGHT

25 kg

INTERPRETED BY

R. McKenzie Daniel, DVM,
DABVP (Canine and
Feline)

IMAGING PERFORMED BY

Kelly Reschny

HOSPITAL NAME

Wellington AH

REFERRING VET

Dr. Dennis

INVOICE

12734

DATE

11/30/21