

**PATIENT PRESENTING CLINICAL SIGNS**

Jenny VanHorton History: Moderate weight loss

**SPECIES** Medication: Hepatobenefits

Canine ALP 75, ALT 149, GGT 80, BUN 20, Creatinine 0.5, Albumin 3.7, Glucose 85, Precision PSL 167, Cholesterol 499, Triglycerides 475, Unremarkable CBC

**BREED ULTRASONOGRAPHIC EXAMINATION OF THE ABDOMEN**

**Beagle Urinary System**

**SEX** The urinary bladder, trigone, cystourethral junction, and visible pelvic urethra to a depth of 3.0 cm exhibited normal thickness and tone. Anechoic urine was present in the lumen with no uroliths or sediment. The ureteral papillae were normal. The ureters were not visible which is normal. No evidence of inflammatory or neoplastic changes was noted.

FS

**AGE** The area of the aortic trifurcation was free of pathology.

12 years Normal size and margination were present in the kidneys. A normal 1:3 cortex / medulla ratio was maintained. The medulla and cortices were uniform in texture with some increased echogenicity and mild loss of corticomedullary symmetry and definition expected for the age of the patient. No evidence of pelvic dilation was present. The left kidney measured 6.2 cm in length. The right kidney measured 5.9 cm in length.

**WEIGHT**

26 Pounds

**Adrenal Glands**

**INTERPRETED BY**

R. McKenzie Daniel, DVM, DABVP (Canine and Feline) The left adrenal gland was uniform in size and contour with a uniformly hypoechoic parenchyma. The left adrenal gland measured 0.93 cm width at the caudal pole and 0.81 cm width at the cranial pole. The right adrenal gland was uniform in size and contour with a uniformly hypoechoic parenchyma. The right adrenal gland measured 0.77 cm width at the caudal pole and 1.0 cm width at the cranial pole.

**IMAGING PERFORMED BY**

Rebekah Jakum, CVT ARDMS/RVT

**HOSPITAL NAME**

Pocono Peak VC

**REFERRING VET**

Dr. Thompson

**Spleen**

The spleen exhibited primarily finely textured parenchyma which was hyperechoic to the liver and renal cortical parenchyma. Mild generalized parenchyma heterogeneity was present without evidence of nodular changes. The capsule was smooth and regular without apparent expansion. The splenic vasculature at the hilus was normal in volume with no evidence of congestion or thrombosis. The parenchymal heterogeneity is likely consistent with benign changes such as extramedullary hematopoiesis or age-related remodeling with minor potential for inflammatory or neoplastic disease.

**Liver/ Gallbladder**

**INVOICE**

12682

**DATE**

11.30.2021

The liver exhibited generalized enlargement with normal structure and contour. Sectorial deep mid to ventral nonhomogeneous to subtly nodular parenchyma was present with a moderate coarse echotexture and subjective mild to benign parenchymal remodeling. This area of nonhomogeneous to indistinctly nodular parenchymal was not overtly consistent with intraparenchymal mass. This sectorial nonhomogeneous to indistinctly nodular parenchymal measured approximately 4.9 cm in diameter. The hepatic and portal vasculature were normal in appearance without signs of congestion. The gallbladder was non-distended in size with mild prominent to echogenic gallbladder walls. Mild



**PATIENT**

Jenny VanHorton

echogenic nonorganized luminal debris exhibiting hyperechoic foci, potentially indicative of pinpoint areas of mineralization primarily noted around the inner luminal surface, as well as mildly congealed in the gallbladder neck, was present. No evidence of peripheral gallbladder inflammation. The cystic and common bile ducts were normal.

**SPECIES**

Canine

***Gastrointestinal***

The stomach presented intact wall layering with a normal wall layer ratio. The lumen of the stomach was empty with no signs of ileus, obstruction, or foreign material. The gastric body wall width measured 0.40 cm.

**BREED**

Beagle

The small intestine presented intact wall layering with 1:3 muscularis/mucosa ratio. The lumen of the small intestine was empty with no signs of ileus, obstruction, or foreign material. The jejunum wall width measured 0.40 cm.

**SEX**

FS

Normal visible colon wall layers were present with apparent formed feces in lumen.

**AGE**

12 years

***Pancreas***

The pancreas was normal in size and contour with heterogeneous to echogenic parenchyma compared to adjacent omentum. No signs of active inflammation or neoplasia.

**WEIGHT**

26 Pounds

***Free Abdomen***

No overt lymphadenopathy or peritoneal effusion was present.

**ULTRASONOGRAPHIC FINDINGS**

**INTERPRETED BY**

R. McKenzie Daniel,  
 DVM, DABVP  
 (Canine and Feline)

***Primary Findings***

- Hepatomegaly with generalized parenchymal remodeling including sectorial deep mid ventral nonhomogeneous to indistinctly nodular parenchyma
- Mild potentially pinpoint mineralized gallbladder debris primarily along the inner luminal surface - potential for mild chronic cholecystitis
- Sonographically unremarkable gastrointestinal tract
- Heterogeneous to mildly echogenic pancreas - age-related variant with potential for low-grade or chronic pancreatitis

**IMAGING PERFORMED BY**

Rebekah Jakum, CVT  
 ARDMS/RVT

**HOSPITAL NAME**

Pocono Peak VC

***Secondary Findings***

- Mild chronic renal changes

**REFERRING VET**

Dr. Thompson

**INTERPRETATION OF THE FINDINGS & FURTHER RECOMMENDATIONS**

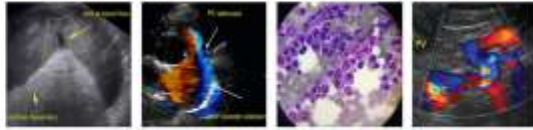
Overall, the liver was nonspecific with considerations including vacuolar or inflammatory hepatopathy or hepatobiliary process with generalized parenchymal remodeling, potential sectorial nodular to regenerative hyperplasia, or atypical lipogranuloma. The possibility of generalized or sectorial low-grade neoplasia such as carcinoma cannot be definitively excluded. Pending hepatic cytology, the addition of Ursodiol to current hepatic support, given the presence of gallbladder debris, +/- empirical antibiotic protocol initially for 2 weeks with a reassessment of liver enzymes could be considered. A hepatic core biopsy may be required for a definitive diagnosis.

**INVOICE**

12682

**DATE**

11.30.2021



**PATIENT**

Jenny VanHorton

A GI panel to include PLI/TLI/Cobalamin/Folate as well as three view chest radiographs and neurological / musculoskeletal examination are recommended to assess for or rule out occult disease which may cause weight loss.

**SPECIES**

Canine

**BREED**

Beagle

**SEX**

FS

**AGE**

12 years

**WEIGHT**

26 Pounds

**INTERPRETED BY**

R. McKenzie Daniel,  
DVM, DABVP  
(Canine and Feline)

**IMAGING PERFORMED BY**

Rebekah Jakum, CVT  
ARDMS/RVT

**HOSPITAL NAME**

Pocono Peak VC

**REFERRING VET**

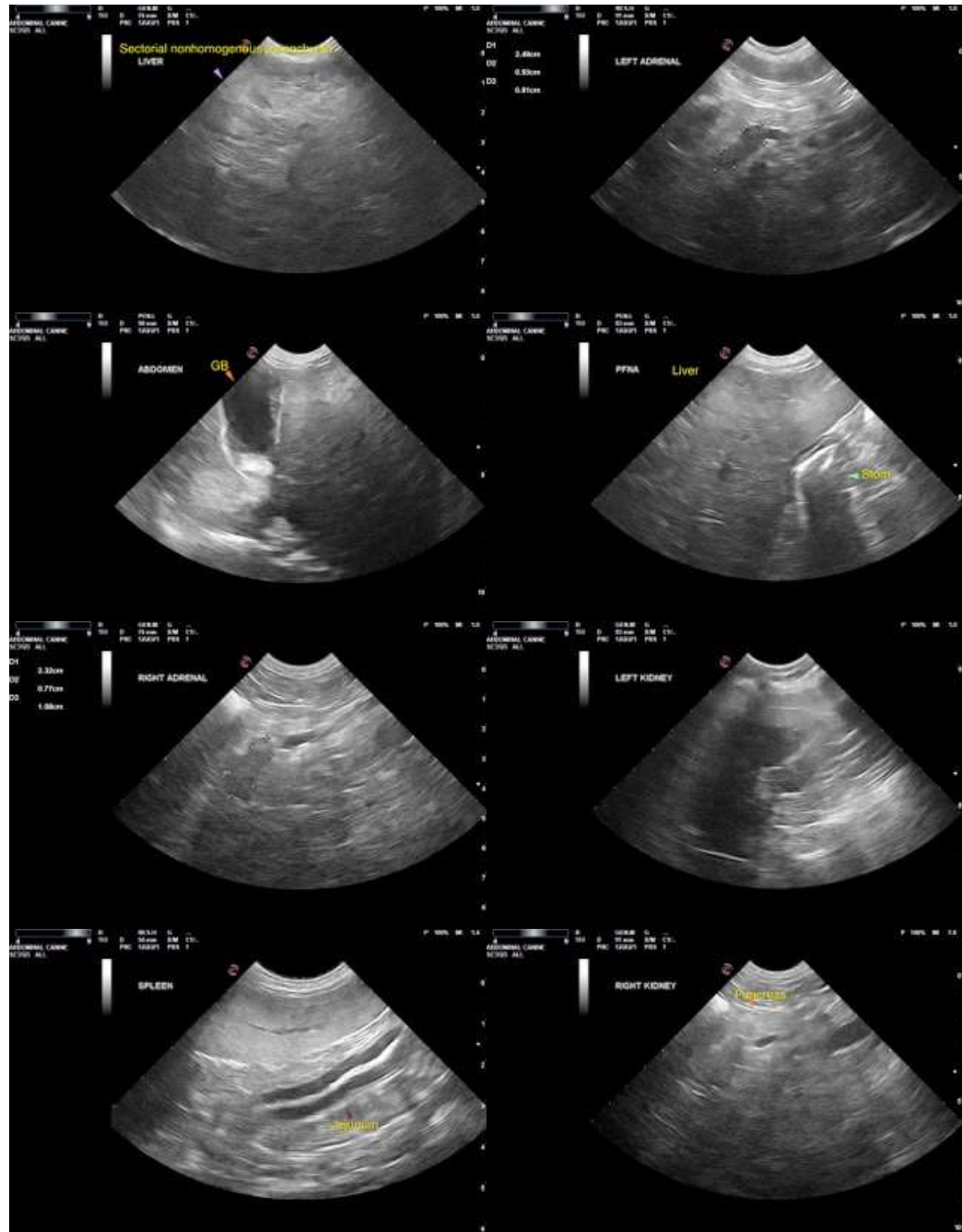
Dr. Thompson

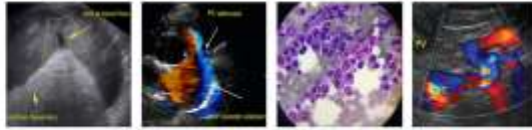
**INVOICE**

12682

**DATE**

11.30.2021





**PATIENT**

Jenny VanHorton

**The information and recommendations provided are based on the images presented by the referring veterinarian. No evaluation can be communicated regarding pathology that was not visible in the image/video clips provided.**

**SPECIES**

Canine

Thank you for this referral. If the clinical or image interpretation does not parallel your findings or if I can be of any further assistance please contact me.

**BREED**

Beagle

**R. McKenzie Daniel, DVM, DABVP (Canine/Feline Practice)**  
[mac.daniel@sonopath.com](mailto:mac.daniel@sonopath.com)

**SEX**

FS

**AGE**

12 years

**WEIGHT**

26 Pounds

**INTERPRETED BY**

R. McKenzie Daniel,  
DVM, DABVP  
(Canine and Feline)

**IMAGING  
PERFORMED BY**

Rebekah Jakum, CVT  
ARDMS/RVT

**HOSPITAL NAME**

Pocono Peak VC

**REFERRING VET**

Dr. Thompson

**INVOICE**

12682

**DATE**

11.30.2021