



PATIENT

Ricky Connor

SPECIES

Feline

BREED

DSH

SEX

Spayed Female

AGE

7

WEIGHT

10.3

INTERPRETED BY

R. McKenzie Daniel,
DVM, DABVP

IMAGING PERFORMED BY

Dr. Sharkaway

HOSPITAL NAME

Kew Gardens Animal
Hospital

REFERRING VET

Dr. Bassem

INVOICE

12060

DATE

11/03/25

PRESENTING CLINICAL SIGNS

Fell off from the 6 floor.

Abnormal PE/Chem/CBC/UA Results: Upper lip wound. Heart murmur 3 out of 6. Blood work-elevated ALT Radiograph-unremarkable

ULTRASONOGRAPHIC EXAMINATION OF THE HEART & ABDOMEN

FELINE CARDIAC PARAMETERS	BODY WEIGHT (kg)	HR (BPM)	IVSd (cm)	LVIDd (cm)	LVWd (cm)	FS (%)	EF (%)
NORMAL PARAMETER	-----	150-240	0.3-0.6	1.0-2.1	0.25-0.6	35-67	80-100
PATIENT	--	NM	0.4	1.2	0.4	45	77
FELINE CARDIAC PARAMETERS	LA/AO (M-mode)	LA/AO HEART BASE (Sisson)	LAD LA MAX 4 Chamber		LVOT VEL. (m/s)	RVOT VEL. (m/s)	IVRT (m/)
NORMAL PARAMETER	<1.5	1.6	0.7-1.7		<1.6	<1.3	40-60
PATIENT	--	1.2	1.2		NM	0.95	NM
Adapted from June Boon, Veterinary Echocardiography, 1998 Sisson D et al. JVIM 1991; 5: 232, Jacobs et al. Am J Vet Res 1985; 46:1705							

Cardiac Presentation

The echocardiogram in this patient demonstrated normal **left atrial** size based on 2 separate LA measurements. The cranial and caudal **mitral** valve leaflets presented normal linear structure and kinetics. The **left ventricle** presented normal thicknesses with linear contour and was not dilated nor restricted. The **myocardium** presented normal echogenicity without subjective evidence of significant fibrotic or ischemic disease. **Contractility** of the ventricular walls was adequate and in normal range for this patient evidenced by the fractional shortening measurement and subjective evaluation of the different regions and angles of the myocardium. The **left ventricular outflow** tract demonstrated normal laminar flow and subjective structural integrity. The **right atrium** and auricle revealed normal size, structure and content. No evidence of masses was noted or chamber overload. **Tricuspid** valvular assessment demonstrated adequate linear morphology and kinetics. The **right ventricle** was of normal size (1/3 diameter of LV), chordae structure, myocardial echogenicity and thickness. **Pulmonic** tract assessment revealed normal valve structure, laminar flow, and diameter (approx. 1:1 pa/ao ratio). No visible **pericardial** or free pleura fluid was noted or extra cardiac pathology in the visible planes. The cranial **mediastinum** and **pericardial regions** were free of masses in the visible window.

Urinary System

The urinary bladder, trigone, cystourethral junction, and visible pelvic urethra to a depth of 2.0 cm exhibited normal thickness and tone. Anechoic urine was present in the lumen with no uroliths or sediment. The ureteral papillae were normal. The ureters were not visible which is normal. No evidence of inflammatory or neoplastic change were noted.



PATIENT

Ricky Connor

SPECIES

Feline

BREED

DSH

SEX

Spayed Female

AGE

7

WEIGHT

10.3

INTERPRETED BY

R. McKenzie Daniel,
DVM, DABVP

IMAGING PERFORMED BY

Dr. Sharkaway

HOSPITAL NAME

Kew Gardens Animal
Hospital

REFERRING VET

Dr. Bassem

INVOICE

12060

DATE

11/03/25

Normal size and margination was present in the kidneys. A normal 1:3 cortex / medulla ratio and normal corticomedullary definition were maintained. The echogenicity of the cortex was similar to or slightly less than normal liver parenchyma while the medulla echogenicity was hypoechoic to the cortex with no evidence of pelvic dilation. The left kidney measured 3.4 cm in length. The right kidney measured 3.7 cm in length.

Adrenal Glands

The left and right adrenal glands were not definitively visualized with no obvious pathology.

Spleen

The spleen exhibited a finely textured and homogenous parenchyma which was hyperechoic to the liver and renal cortical parenchyma. The capsule was smooth and regular without apparent expansion. The splenic vasculature at the hilus was normal in volume with no evidence of congestion or thrombosis. Acute to chronic inflammatory, neoplastic, or benign parenchyma changes were not noted.

Liver

The liver was subjectively normal in size, structure, and contour. The liver parenchyma was uniform and hypoechoic to the spleen with a mild coarse echotexture. The hepatic and portal vasculature were subjective adequate in appearance without signs of congestion.

The gallbladder was non distended in size with minor biliary sludge. The common bile duct was not visualized.

Gastrointestinal

The stomach presented intact wall layering with a normal wall layer ratio. The lumen of the stomach was empty with no signs of ileus, obstruction or foreign material.

The small intestine presented intact wall layering with 1:3 muscularis/mucosa ratio. The lumen of the small intestine was empty with no signs of ileus, obstruction or foreign material.

Normal visible colon wall layers were present with apparent formed feces in lumen.

Pancreas

The parenchyma of the left limb, body and right limb of the pancreas presented isoechoic to the adjacent omental fat. A normal curvilinear capsule contour of the pancreas was present. The visible pancreatic duct was normal. No signs of active inflammation or neoplastic disease was evident.

Free Abdomen

No visualized significant omental lymphadenopathy or peritoneal effusion was present. No evidence of hemo-abdomen.

ULTRASONOGRAPHIC FINDINGS

- Normal echocardiogram.
- Subjective unremarkable normal volume liver.
- Minor gallbladder debris.
- Normal peritoneal cavity- no evidence of trauma/effusion.



PATIENT

Ricky Connor

SPECIES

Feline

BREED

DSH

SEX

Spayed Female

AGE

7

WEIGHT

10.3

INTERPRETED BY

R. McKenzie Daniel,
DVM, DABVP

IMAGING PERFORMED BY

Dr. Sharkaway

HOSPITAL NAME

Kew Gardens Animal
Hospital

REFERRING VET

Dr. Bassem

INVOICE

12060

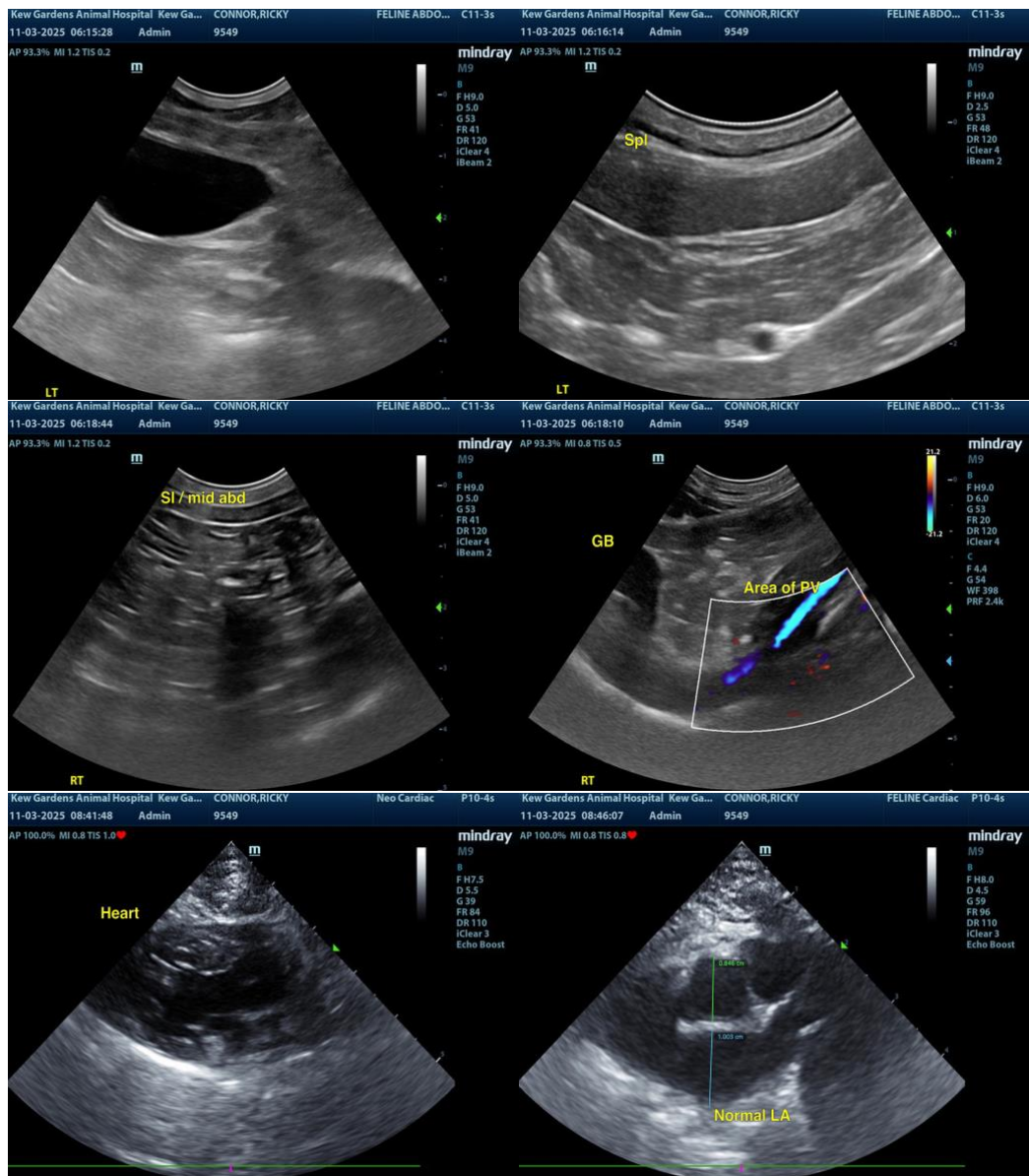
DATE

11/03/25

INTERPRETATION OF THE FINDINGS & FURTHER RECOMMENDATIONS

Assuming no volume changes or dehydration, a benign flow murmur is considered probable although a small nonvisualized flow abnormality cannot be excluded. Regardless, the hemodynamic effects of the murmur appear low. No indication for cardiac medications. Conservative monitoring of the murmur is advised with recheck echo suggested in 8-12 months or sooner if increase in murmur intensity.

No evidence of abdominal visceral pathology or overt intrahepatic or extrahepatic macroscopic shunt. Further assessment of the liver may include (assuming normal clotting status and using a 25-gauge needle) hepatic FNA cytology primarily to assess for evidence of inflammatory criteria in conjunction with mild gallbladder debris. Hepatosupportive medications may prove beneficial. No overt cardiac or abdominal anesthetic contraindications.





PATIENT

Ricky Connor

SPECIES

Feline

BREED

DSH

SEX

Spayed Female

AGE

7

WEIGHT

10.3

INTERPRETED BY

R. McKenzie Daniel,
DVM, DABVP

IMAGING PERFORMED BY

Dr. Sharkaway

HOSPITAL NAME

Kew Gardens Animal
Hospital

REFERRING VET

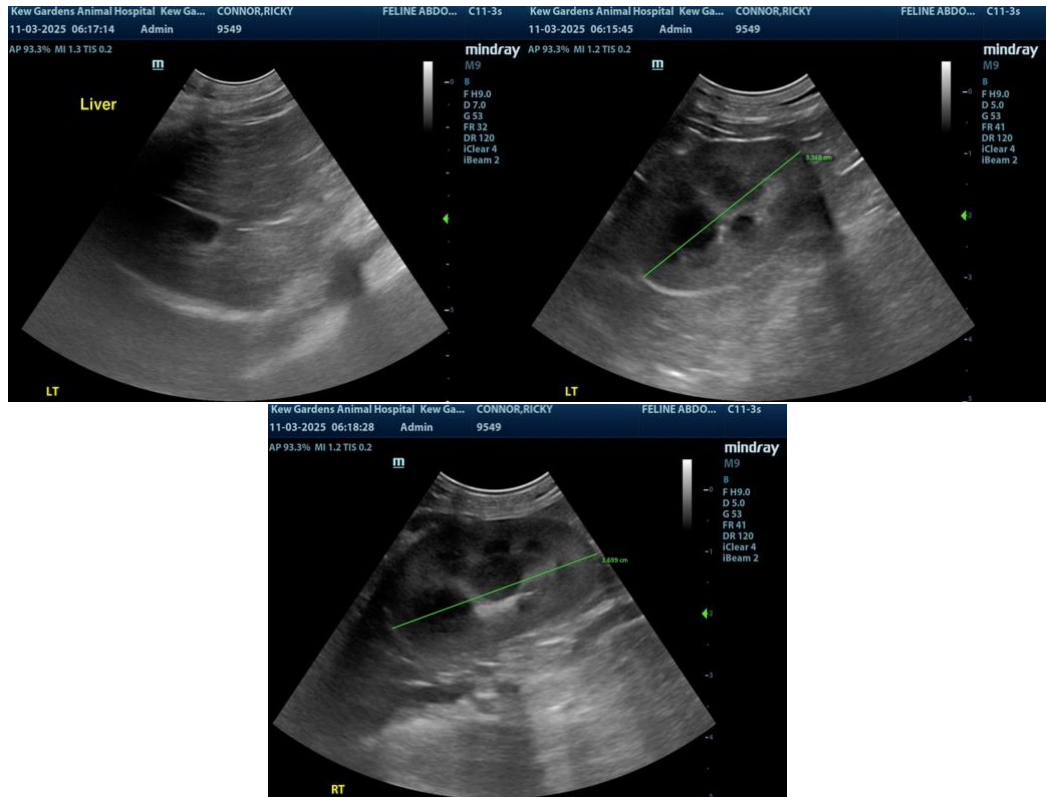
Dr. Bassem

INVOICE

12060

DATE

11/03/25



The information and recommendations provided are based on the images presented by the referring veterinarian/sonographer. No evaluation can be communicated regarding pathology that was not visible in the image/video clips provided.

Thank you for this referral. If the clinical or image interpretation does not parallel your findings or if I can be of any further assistance, please contact me.

R. McKenzie Daniel, DVM, DABVP (Canine / Feline Practice)

info@SonoPath.com