



PATIENT PRESENTING CLINICAL SIGNS

Ski Steen

SPECIES

Canine

BREED

Brittany Spaniel

SEX

Neutered Male

AGE

13 Years

WEIGHT

52.8 Pounds

History: referral today from alaska originally and returning tomorrow HX of LAR PAR, previous anal masses (HX unknown) REferring dvm did an x-ray found a mass in the abdomen, here to do an ultrasound, to take a closer mass vet in Hettinger thought it was cancerous and possibly liver origin, their primary vet in AK thought it was the spleen (splenic hematoma) based on abdominal rads Seen by Hettinger vet during travel to ND for hunting. Noted straining to defecate and more ribbon like stool o is wondering about the cancerous question - wanting to RO if benign vs more concerning. e/d- sort of, not eating as well as have been, has been hunting, o thinks mass is pushing on the stomach making p get full quicker or displacing intestines medications, taking prilosec for the stomach, and clavamox for enlarged prostate

Abnormal PE/Chem/CBC/UA Results:BAR Abdomen: Abnormal: Focal ~3" discrete round mass within SQ tissue L lateral abdomen. Can palpate firm rounded mid to cranial abdominal mass with sedation. Rectal: Abnormal rectal exam: Previous perianal mass removals. Prostatic enlargement

ULTRASONOGRAPHIC EXAMINATION OF THE ABDOMEN

Urinary System

The urinary bladder, trigone, cystourethral junction, and visible pelvic urethra exhibited normal thickness and tone. Mild asymmetrical luminal surface to micropolypoid changes were present likely associated with age related mural changes. Anechoic urine was present in the lumen with no calculi or sediment. The ureteral papillae were normal. The ureters were not visible which is normal. No evidence of inflammatory or neoplastic changes were noted.

The residual prostate was enlarged in size with primarily maintained symmetrical capsule contour. Generalized mildly hypoechoic nonhomogenous parenchyma was noted, exhibiting pinpoint hyperechoic parenchyma foci. The residual prostate measured approximately 5.0 cm x 4.2 cm.

INTERPRETED BY

R. McKenzie Daniel,
DVM, DABVP
(Canine and Feline)

Normal size and margination was present in the kidneys. A normal 1:3 cortex / medulla ratio was maintained. The medulla and cortices were uniform in texture with some increased echogenicity and moderate loss of corticomedullary symmetry and definition expected for the age of the patient. No evidence of pelvic dilation was present. The left kidney measured 6.0 cm in length. The right kidney measured 6.5 cm in length.

IMAGING PERFORMED BY

Dr. Jessie Evoniuk

Adrenal Glands

The bilateral adrenal glands were normal in size. Mild parenchyma heterogeneity and mild capsule asymmetry was present without suspicion for overt neoplasia. The left adrenal gland measured 0.82 cm width in the cranial pole and 0.89 cm width in the caudal pole. The right adrenal gland measured 0.9 cm width in the cranial pole and 0.71 cm width in the caudal pole. No evidence of adrenal tumors or neoplastic criteria.

HOSPITAL NAME

State Avenue VC

REFERRING VET

Dr. Jessie Evoniuk

Spleen

The spleen exhibited primarily finely textured parenchyma which was hyperechoic to the liver and renal cortical parenchyma. Mild generalized parenchyma heterogeneity was present without evidence of nodular changes. The capsule was smooth and regular without apparent expansion. The splenic vasculature at the hilus was normal in volume with no evidence of congestion or thrombosis. The parenchymal heterogeneity is likely consistent with benign changes such as extramedullary hematopoiesis or age-related remodeling with minor potential for inflammatory or neoplastic disease.

INVOICE

17938

DATE

11/3/22

Liver



PATIENT

Ski Steen

The liver was subjectively normal in size, structure, and contour. The liver parenchyma was mildly nonuniform and hypoechoic to the spleen with a moderate coarse echotexture and subjective mild to benign parenchymal remodeling. The hepatic and portal vasculature were normal in appearance without signs of congestion.

SPECIES

Canine

The gallbladder was non distended in size with echogenic, nonmineralized biliary sludge. The cystic duct and common bile ducts were normal without evidence of dilation.

Gastrointestinal

BREED

Brittany Spaniel

The stomach presented intact wall layering with a normal wall layer ratio. The lumen of the stomach contained mild nonshadowing ingesta/chyme.

The visualized segments of small intestine were sonographically unremarkable.

SEX

Neutered Male

Normal visible colon wall layers were present with apparent formed feces in lumen.

Pancreas

AGE

13 Years

The area of the left pancreas was indistinctly visualized owing to the presence of a cranial abdominal mass with increased regional peripancreatic artifact. No overt pathology in the area of the right pancreatic limb.

Free Abdomen

WEIGHT

52.8 Pounds

A moderately sized primarily spherical nonhomogenous subjectively encapsulated mass/lesion was present in the cranial abdomen, subjectively medial to the spleen and caudal to the left liver, potentially within the area of the left pancreatic limb. The mass lesion exhibited nonhomogenous to mixed echogenic parenchyma without overt evidence of significant vascularity on color doppler assessment. The mass lesion measured approximately 8.3 cm x 6.7 cm.

INTERPRETED BY

R. McKenzie Daniel,
DVM, DABVP
(Canine and Feline)

Regional hyperechoic mesentery was noted with concurrent free peritoneal fluid versus possible pockets of omental fluid, exhibiting possible mild fluid echogenic changes.

No overt lymphadenopathy.

IMAGING PERFORMED BY

Dr. Jessie Evoniuk

HOSPITAL NAME

State Avenue VC

ULTRASONOGRAPHIC FINDINGS

- Residual prostatomegaly with nonhomogenous to pinpoint hyperechoic parenchyma- primary concern for residual prostatic neoplastic criteria, i.e., prostatic or urothelial carcinoma or other. Potential for prostatitis is possible yet thought less likely.
- Unspecified cranial abdominal mass/lesion with regional steatitis/peritonitis- suspect omental abscess, necrosis, potential necrotic granuloma or similar unspecified neoplastic criteria is possible.
- Overtly normal spleen
- Minor hepatic parenchymal remodeling- benign
- Mild chronic renal changes

REFERRING VET

Dr. Jessie Evoniuk

INVOICE

17938

INTERPRETATION OF THE FINDINGS & FURTHER RECOMMENDATIONS

DATE

11/3/22

The unspecified cranial abdominal mass/lesion did not overtly appear to originate from or involve the spleen or caudal aspect of the liver. Potential for pancreatic omental or lymphatic origin could be



PATIENT

Ski Steen

SPECIES

Canine

BREED

Brittany Spaniel

SEX

Neutered Male

AGE

13 Years

WEIGHT

52.8 Pounds

INTERPRETED BY

R. McKenzie Daniel,
DVM, DABVP
(Canine and Feline)

IMAGING PERFORMED BY

Dr. Jessie Evoniuk

HOSPITAL NAME

State Avenue VC

REFERRING VET

Dr. Jessie Evoniuk

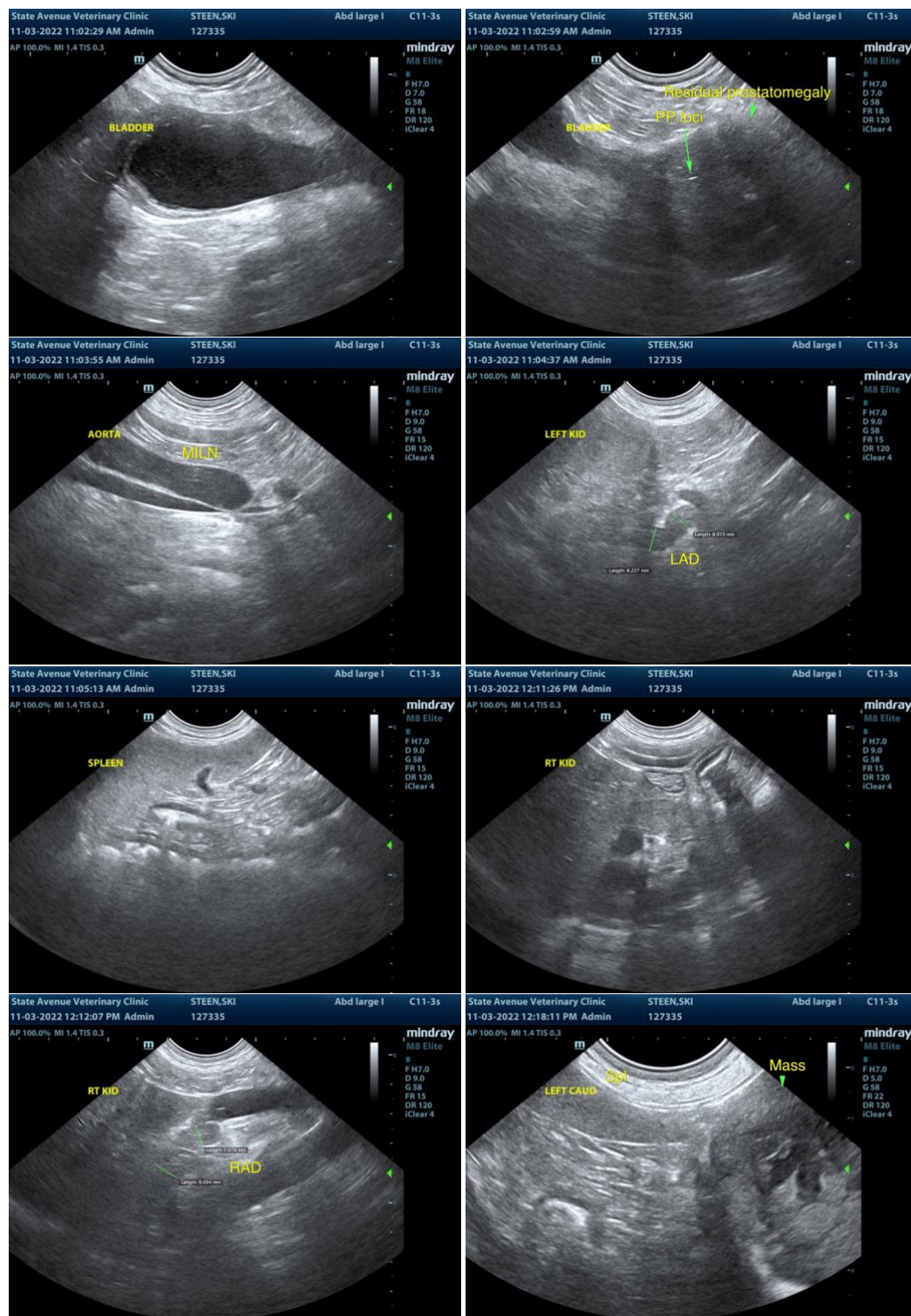
INVOICE

17938

DATE

11/3/22

possible. Screening FNA cytology of the unspecified mass for further assessment +/- culture and sensitivity if clinically indicated is recommended. Concurrent prostatic sampling, i.e., FNA cytology or prostatic wash is required for further clarification and prognosis. No overt evidence of regional periprostatic metastasis if neoplastic process is confirmed. Three view chest radiographs are recommended.





PATIENT

Ski Steen

SPECIES

Canine

BREED

Brittany Spaniel

SEX

Neutered Male

AGE

13 Years

WEIGHT

52.8 Pounds

INTERPRETED BY

R. McKenzie Daniel,
DVM, DABVP
(Canine and Feline)

IMAGING PERFORMED BY

Dr. Jessie Evoniuk

HOSPITAL NAME

State Avenue VC

REFERRING VET

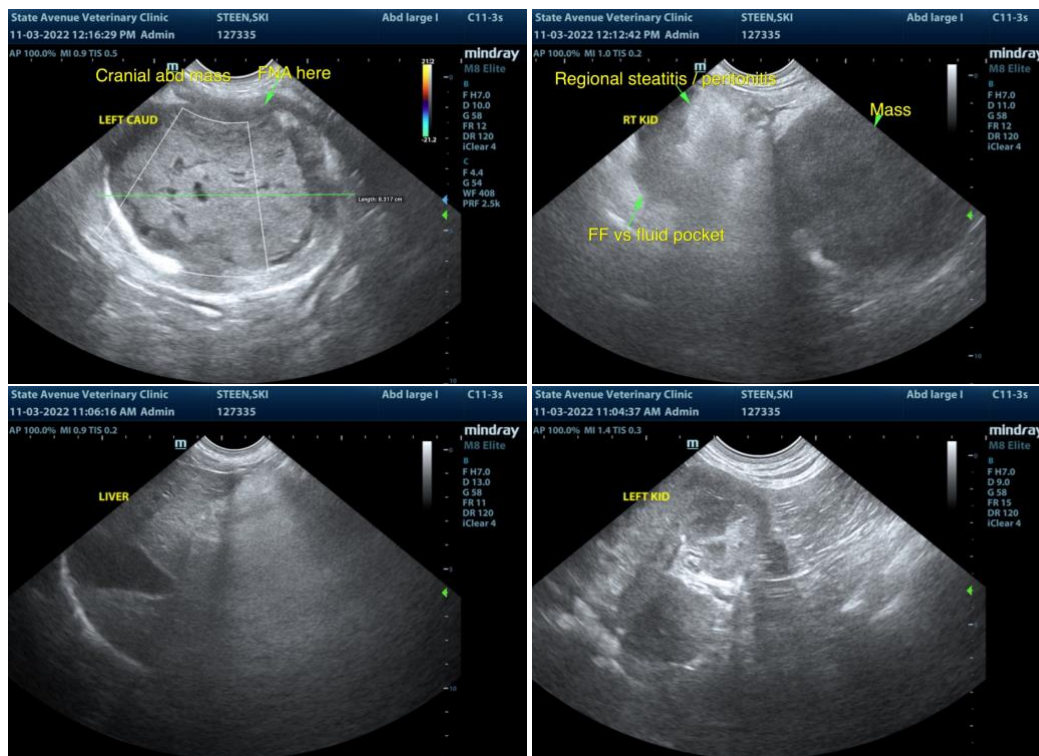
Dr. Jessie Evoniuk

INVOICE

17938

DATE

11/3/22



The information and recommendations provided are based on the images presented by the referring veterinarian. No evaluation can be communicated regarding pathology that was not visible in the image/video clips provided.

Thank you for this referral. If the clinical or image interpretation does not parallel your findings or if I can be of any further assistance please contact me.

R. McKenzie Daniel, DVM, DABVP (Canine / Feline Practice)
info@SonoPath.com