



PATIENT

Gus Gus Fatolitis

SPECIES

Canine

BREED

Beagle Mix

SEX

SF

AGE

9y 8m

WEIGHT

57.3 lbs.

INTERPRETED BY

R. McKenzie Daniel,
DVM, DABVP
(Canine and Feline)

IMAGING PERFORMED BY

Michaleen

HOSPITAL NAME

DCP VH

REFERRING VET

Dr. Ward

INVOICE

15352

DATE

11/3/22

PRESENTING CLINICAL SIGNS

Reason for Visit: Attempting to urinate but only dribbling History: 9y 8m Beagal mix presented for squatting to urinate but only dribbles coming out yesterday. urinated normally today. Went to saint francis last night, they took x rays and stated they saw no stones. pet has had stones in the past. Doctor there suggested they may be invisible. Pet did vomit 1 x yesterday, none since.

Abnormal PE/Chem/CBC/UA Results: Results: Adult annual Plus with UA; abdominal radiographs: CBC--mild neutropenia=2432 (2940-12670) rule-out sequestration less likely decreased production, mildly low monocytes. Normal plaetlets and Hct. Chem--ALP=660 (5-160), rule-out cholestatic disease vs. vacuolar hepatopathy (HAC vs. age-related) vs. boneisoform/metastatic disease (less likely) TT4 WNL First-morning USG dropped off this AM: 1.017 UA--4/hpf on dilute sample; considered clinically significant Abdominal radiographs: focal sublumbar increased soft tissue opacity (suspect sublumbar lymphadenopathy) Empty urinary bladder Spondylosis L7-S1, DJD right coxofemoral joint Recommendations: urinary tract ultrasound; cystocentesis/urine culture

The submitted study contained 15 videos limited to the urinary system.

ULTRASONOGRAPHIC EXAMINATION OF THE URINARY SYSTEM

The urinary bladder exhibited subjective mild distended size yet overall normal tone containing anechoic urine with no sediment or calculi. No evidence of inflammatory or neoplastic urinary bladder mural changes. The area of the trigone and cystourethral junction was free of overt pathology. The visible proximal urethra exhibited subjective normal structure and tone, without evidence of proximal urethra urine retention or dilation to a depth of 3.0 cm.

No evidence of overt pathology was noted in the area of the uterine remnant.

The area of the iliac trifurcation was free of pathology including no visualized evidence of medial Iliac or sublumbar lymphadenopathy/masses.

Normal size and margination were present in the kidneys. A normal 1:3 cortex / medulla ratio and normal corticomedullary definition were maintained. The echogenicity of the cortex was similar to or slightly less than normal liver parenchyma while the medulla echogenicity was hypoechoic to the cortex with no evidence of pyelectasia. The left kidney measured 5.7 cm in length. The right kidney measured 6.1 cm in length.

ULTRASONOGRAPHIC FINDINGS

- Overtly normal yet mildly distended urinary bladder
- Overtly normal visible proximal urethra
- Normal bilateral kidneys

INTERPRETATION OF THE FINDINGS & FURTHER RECOMMENDATIONS

A definitive cause of the patient's urinary abnormalities was not obvious in this study. No overt evidence of pyelonephritis or primary urinary bladder pathology, i.e., masses, calculi, was noted. The possibility of a non-visualized lesion within the visible or nonvisible proximal urethra, given the mildly distended urinary bladder in conjunction with the patient's clinical signs, cannot be excluded. Contrast imaging or cystoscopy may be indicated.



PATIENT

Gus Gus Fatolitis

SPECIES

Canine

BREED

Beagle Mix

SEX

SF

AGE

9y 8m

WEIGHT

57.3 lbs.

INTERPRETED BY

R. McKenzie Daniel,
DVM, DABVP
(Canine and Feline)

IMAGING PERFORMED BY

Michaleen

HOSPITAL NAME

DCP VH

REFERRING VET

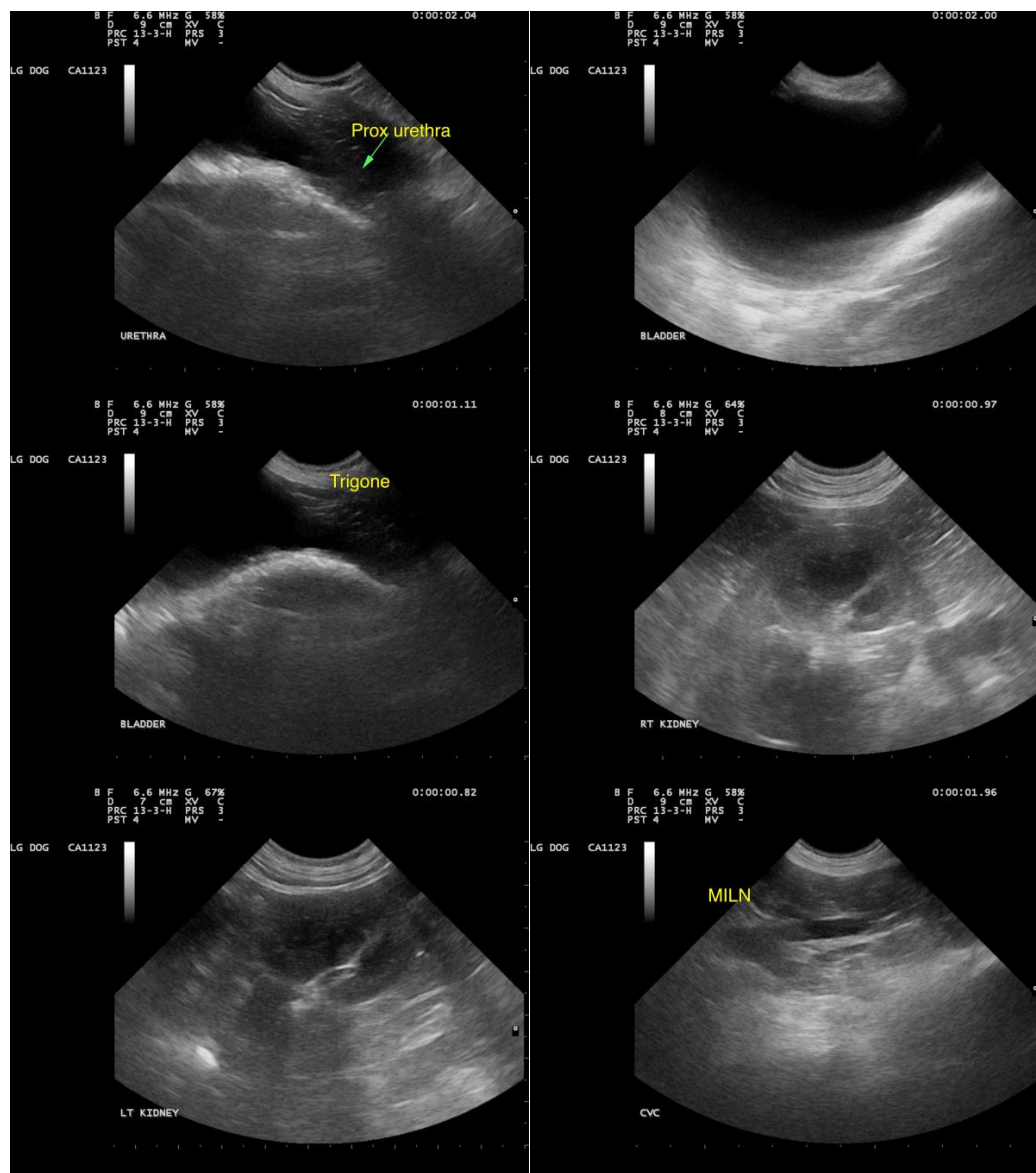
Dr. Ward

INVOICE

15352

DATE

11/3/22



The information and recommendations provided are based on the images presented by the referring veterinarian/sonographer. No evaluation can be communicated regarding pathology that was not visible in the image/video clips provided.

Thank you for this referral. If the clinical or image interpretation does not parallel your findings or if I can be of any further assistance please contact me.

R. McKenzie Daniel, DVM, DABVP (Canine / Feline Practice)
info@SonoPath.com