

PATIENT

Charger Milton

SPECIES

Canine

BREED

Lab X

SEX

MN

AGE

7 years

WEIGHT

65 lbs.

INTERPRETED BY

R. McKenzie Daniel,
DVM, DABVP

**IMAGING
PERFORMED BY**

Kelly Reschny

HOSPITAL NAME

Norwich Vet Services

REFERRING VET

Dr. Kungl

INVOICE

15349

DATE

11/3/22

PRESENTING CLINICAL SIGNS

Throat palpation is thick mid neck - left side feels more proximal than right. When I started to palpate then he did start to clear his throat after a few moments of examining. This continued during the rest of the exam. meds: metacam, doxycycline

Abnormal PE/Chem/CBC/UA Results: please see rads and labs

ULTRASONOGRAPHIC EXAMINATION OF THE NECK

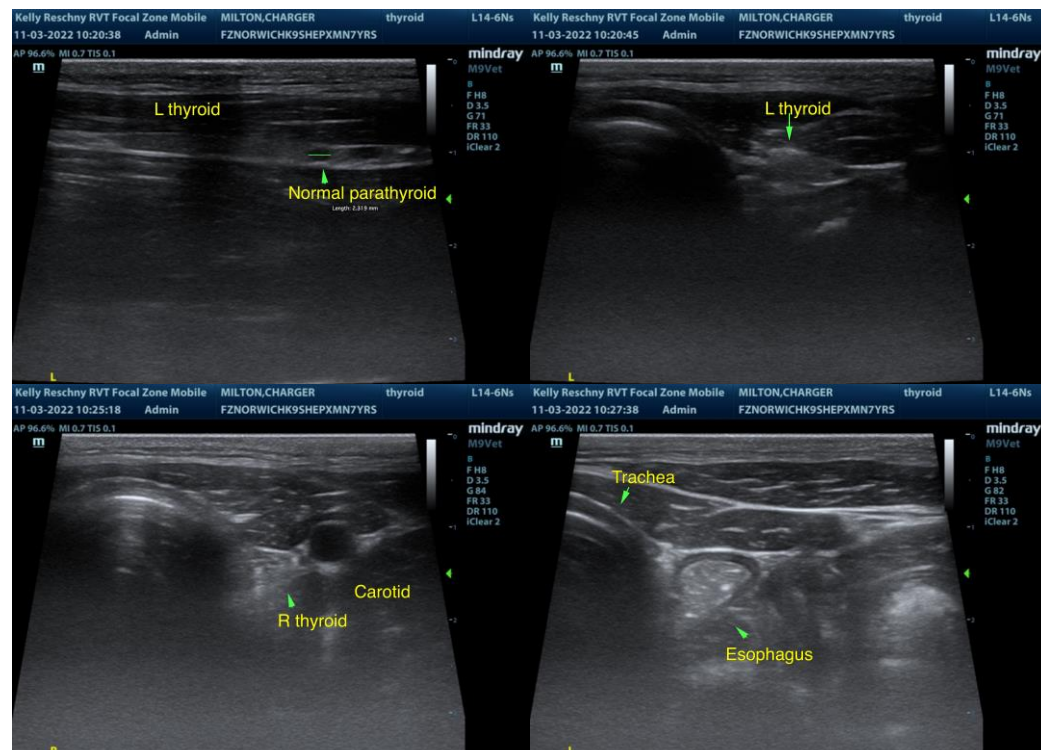
The left thyroid lobe was normal in size, position, shape and parenchyma echogenicity measuring 2.8 cm length x 0.3 cm width. Visualized left parathyroid glands were sonographically unremarkable in size and shape. An example of left parathyroid gland measured 0.23 cm in diameter. The right thyroid lobe was comparable in size to the left thyroid lobe exhibiting normal size, position, shape and parenchyma echogenicity. No evidence of right parathyroid gland enlargement was note. The trachea was sonographically normal. The esophagus was sonographically normal. Regional neck tissue, i.e., musculature and fascia were sonographically normal. No evidence of reginal subcutaneous edema or free fluid. The visualized left and right carotid vasculature was sonographically normal.

ULTRASONOGRAPHIC FINDINGS

- Sonographically unremarkable left and right thyroid lobes, sonographically unremarkable left and right parathyroid glands

INTERPRETATION OF THE FINDINGS & FURTHER RECOMMENDATIONS

No evidence of thyroid, parathyroid, or regional subcutaneous neck pathology was noted.





PATIENT

Charger Milton

The information and recommendations provided are based on the images presented by the referring veterinarian/sonographer. No evaluation can be communicated regarding pathology that was not visible in the image/video clips provided.

SPECIES

Canine

Thank you for this referral. If the clinical or image interpretation does not parallel your findings or if I can be of any further assistance please contact me.

BREED

Lab X

R. McKenzie Daniel, DVM, DABVP (Canine / Feline Practice)
info@SonoPath.com

SEX

MN

AGE

7 years

WEIGHT

65 lbs.

INTERPRETED BY

R. McKenzie Daniel,
DVM, DABVP

IMAGING PERFORMED BY

Kelly Reschny

HOSPITAL NAME

Norwich Vet Services

REFERRING VET

Dr. Kungl

INVOICE

15349

DATE

11/3/22