

**PATIENT**

Sugar Westerdale

**SPECIES**

Feline

**BREED**

DSH

**SEX**

Spayed Female

**AGE**

14 Years

**WEIGHT**

9.1 Pounds

**INTERPRETED BY**R. McKenzie Daniel, DVM,  
DABVP (Canine and Feline)**IMAGING  
PERFORMED BY**

Sarah Pender, CVT

**HOSPITAL NAME**

SVS Imaging QC

**REFERRING VET**

Dr. Chris Rall

**INVOICE**

18892

**DATE**

11/29/22

**PRESENTING CLINICAL SIGNS**

History: Annual wellness exam 11/23/2022. Nibbles on litter. Eats Purina Pro Plan Senior canned food but vomits about 9 of 10 times. also has Science Diet Senior dry. Vomits food, hair, foam; daily for about a week, then is fine - comes and goes. Seems to strain after defecating/coming out of box.

Doesn't jump up on furniture much anymore.

Abnormal PE/Chem/CBC/UA Results: Weight loss from 13.6# on 6/14/2021. Slight icterus. Possible dental resorptive lesions. MCS 3/9 with prominent spine. Slightly increased WBC, neutros, monos; decreased lymphs; increased SDMA with creatinine and BUN WNR; decreased albumin and TP; increased AST, ALP, GGT, all bilirubins, and Spec fPL.

**ULTRASONOGRAPHIC EXAMINATION OF THE ABDOMEN****Urinary System**

The urinary bladder, trigone, cystourethral junction, and visible pelvic urethra to a depth of 2.0 cm exhibited normal thickness and tone. Anechoic urine was present in the lumen with no uroliths or sediment. The ureteral papillae were normal. The ureters were not visible which is normal. No evidence of inflammatory or neoplastic changes were noted. No evidence of medial iliac or sublumbar lymphadenopathy/masses.

Normal size and margination was present in the kidneys. A normal 1:3 cortex / medulla ratio was maintained. The medulla and cortices were uniform in texture with some increased echogenicity and mild loss of corticomedullary symmetry and definition expected for the age of the patient. No evidence of pelvic dilation was present. The left kidney measured 3.7 cm in length. The right kidney measured 3.9 cm in length.

**Adrenal Glands**

The left adrenal gland was uniform in size and contour with a uniformly hypoechoic parenchyma. The left adrenal gland measured 0.33 cm.

The right adrenal gland was uniform in size and contour with a uniformly hypoechoic parenchyma. The right adrenal gland measured 0.43 cm.

**Spleen**

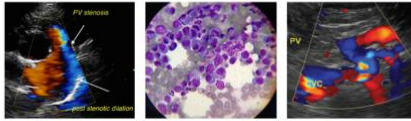
The spleen exhibited a finely textured and homogenous parenchyma which was hyperechoic to the liver and renal cortical parenchyma. The capsule was smooth and regular without apparent expansion. The splenic vasculature at the hilus was normal in volume with no evidence of congestion or thrombosis. Acute to chronic inflammatory, neoplastic, or benign parenchyma changes were not noted. The spleen measured 0.52 cm in width at the level of the hilus.

**Liver**

The liver revealed moderate generalized enlargement with primarily maintained symmetrical capsule contour and generalized nonuniform hepatic parenchyma, exhibiting moderate coarse ecotecture. No overt hepatic masses or nodules.

The gallbladder was nondistended in size with anechoic content primarily with mild dependent mineral. No evidence of peripheral gallbladder inflammation. The cystic and common bile ducts were normal.

**Gastrointestinal**

**PATIENT**

Sugar Westerdale

The stomach presented intact wall layering with a normal wall layer ratio. The lumen of the stomach was empty with no signs of ileus, obstruction or foreign material. The gastric body wall measured 0.25 cm.

**SPECIES**

Feline

The small intestine exhibited intact wall layering with primarily maintained 1:3 muscularis/mucosa ratio to the level of the ileocolic junction. Mild to moderately expansive irregular hypoechoic mass was present at the level and subjectively involving the ileocolic junction, measuring approximately 5.0 cm in diameter.

**BREED**

DSH

Normal visible colon wall layers were present with apparent formed feces in lumen.

**SEX**

Spayed Female

The pancreas was normal to mildly prominent in size with. Mild capsule asymmetry and subtle hypoechoic to nonhomogenous parenchyma.

**AGE**

14 Years

**Free Abdomen**

Multiple variably sized, hypoechoic to swollen colic and hepatic lymph nodes were present. The lymph nodes exhibited symmetrical to rounded margination with abnormal width: length ratio (>0.5). The enlarged lymph nodes were bordered by echogenic to reactive mesentery. An example of colic lymph node measured 2.5 cm x 2.1 cm. An example of hepatic lymph node measured 1.8 cm x 0.9 cm. Mild volume peritoneal free fluid was noted. Evidence of periileocolic and perilymphatic hyperechoic mesentery was noted.

**WEIGHT**

9.1 Pounds

**Thorax****INTERPRETED BY**R. McKenzie Daniel, DVM,  
DABVP (Canine and Feline)

Brief sonographic assessment of the thorax revealed overtly normal cardiac structure and function without evidence of left or right heart chamber enlargement. Concurrent hypoechoic to swollen cranial thoracic lymph node were present, as well as concurrent mild volume pleural effusion.

**ULTRASONOGRAPHIC FINDINGS****IMAGING PERFORMED BY**

Sarah Pender, CVT

**Primary Findings**

- Enlarged nonhomogenous liver
- Ileocolic mass
- Multicentric intraabdominal and cranial thoracic lymphadenopathy
- Bicavitary effusion

**HOSPITAL NAME**

SVS Imaging QC

**REFERRING VET**

Dr. Chris Rall

**Secondary Findings**

- Mild chronic renal changes
- Possible concurrent low-grade pancreatitis

**INVOICE**

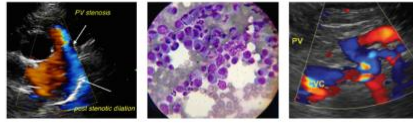
18892

**DATE**

11/29/22

**INTERPRETATION OF THE FINDINGS & FURTHER RECOMMENDATIONS**

Although sampling is required for further assessment, primary concern for multicentric round cell neoplasia involving the ileocolic junction, as well as multicentric bicavitary lymph nodes and secondary bicavitary effusion suspected to be secondary to lymphatic obstruction. Nonneoplastic etiology, i.e., severe inflammatory process, FIP, etc., is possible yet thought less likely. Primary concern



**PATIENT**

for multicentric potentially high-grade lymphoma.

Sugar Westerdale

Assuming normal clotting status, FNA cytology of the ileocolic mass, as well as accessible lymph node for cytology +/- oncology consult for chemotherapeutic intervention could be considered. However, likely unfavorable long-term prognosis is unfortunately indicated.

**SPECIES**

Feline

**BREED**

DSH

**SEX**

Spayed Female

**AGE**

14 Years

**WEIGHT**

9.1 Pounds

**INTERPRETED BY**

R. McKenzie Daniel, DVM,  
DABVP (Canine and Feline)

**IMAGING PERFORMED BY**

Sarah Pender, CVT

**HOSPITAL NAME**

SVS Imaging QC

**REFERRING VET**

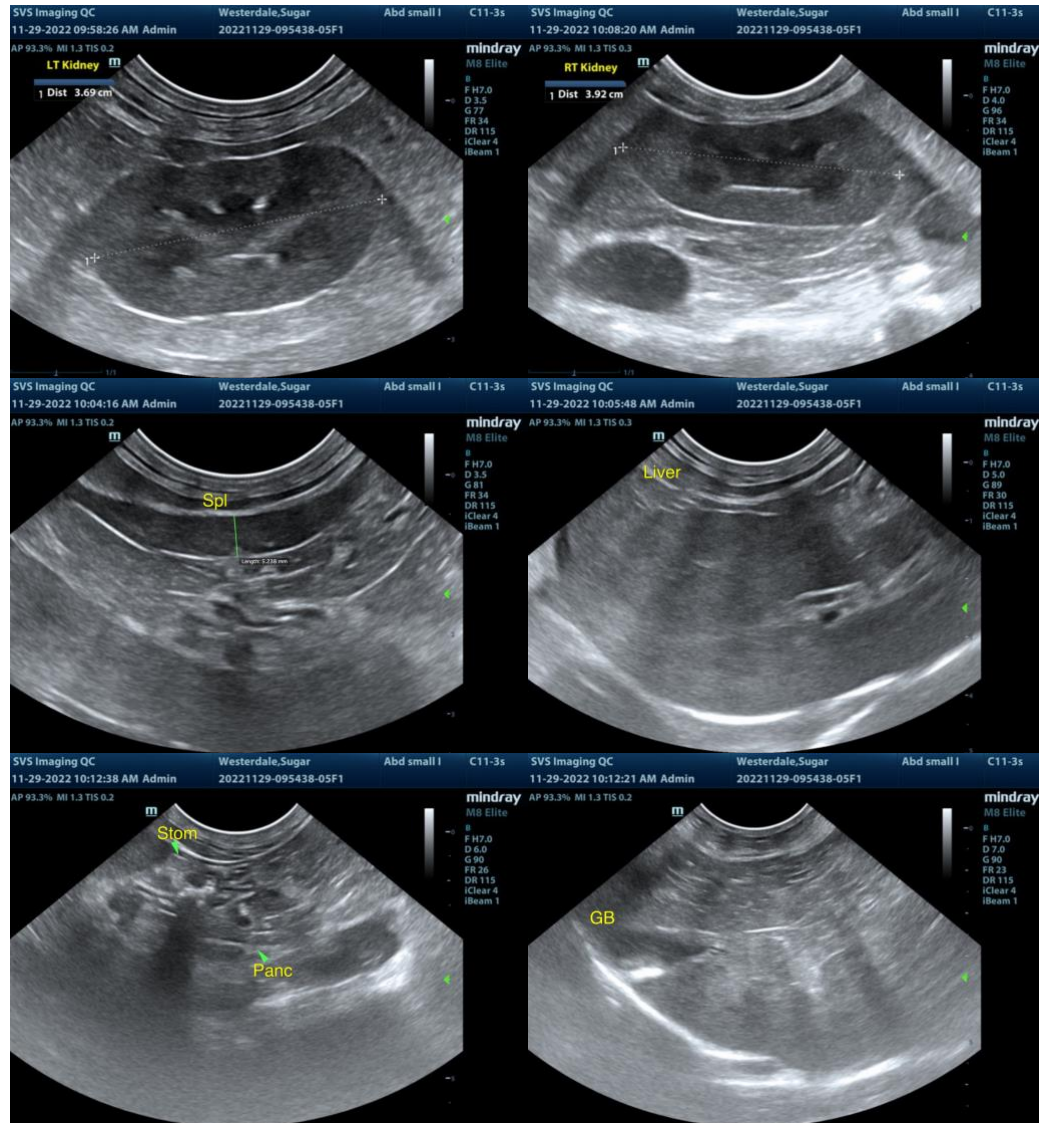
Dr. Chris Rall

**INVOICE**

18892

**DATE**

11/29/22





**PATIENT**

Sugar Westerdale

**SPECIES**

Feline

**BREED**

DSH

**SEX**

Spayed Female

**AGE**

14 Years

**WEIGHT**

9.1 Pounds

**INTERPRETED BY**

R. McKenzie Daniel, DVM,  
DABVP (Canine and Feline)

**IMAGING PERFORMED BY**

Sarah Pender, CVT

**HOSPITAL NAME**

SVS Imaging QC

**REFERRING VET**

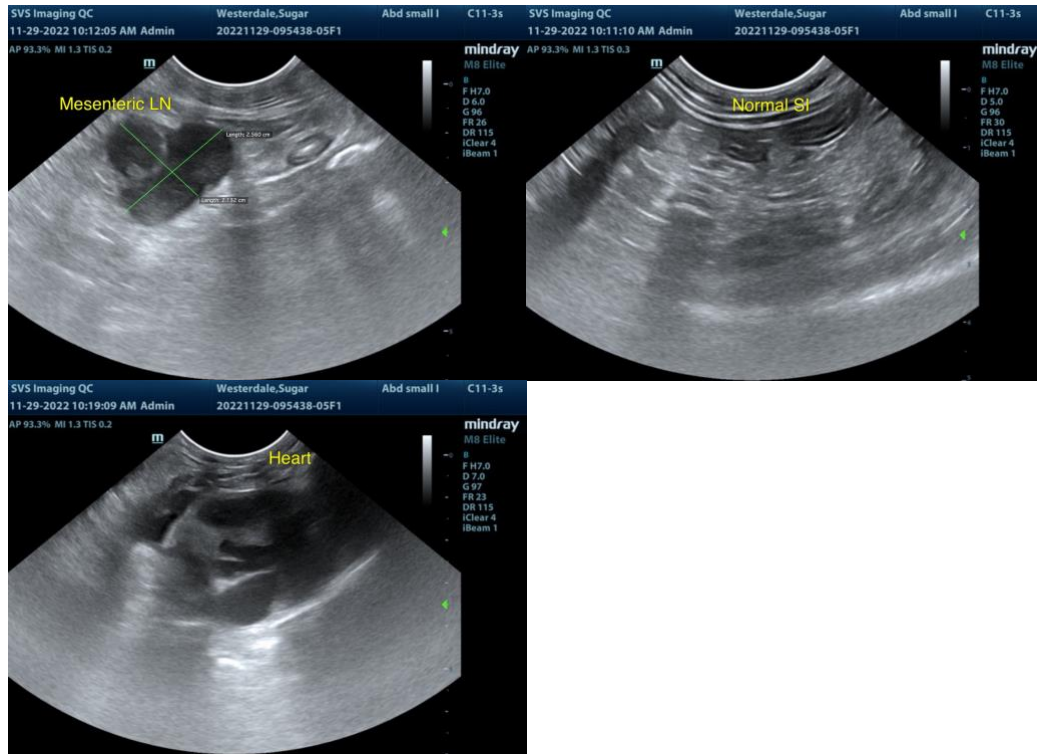
Dr. Chris Rall

**INVOICE**

18892

**DATE**

11/29/22



The information and recommendations provided are based on the images presented by the referring veterinarian. No evaluation can be communicated regarding pathology that was not visible in the image/video clips provided.

Thank you for this referral. If the clinical or image interpretation does not parallel your findings or if I can be of any further assistance please contact me.

R. McKenzie Daniel, DVM, DABVP (Canine / Feline Practice)  
info@SonoPath.com