

**PATIENT**

Remy Waddell 54959A

SPECIES

Feline

BREED

DSH

SEX

MN

AGE

2yr

WEIGHT

5kg

INTERPRETED BYR. McKenzie Daniel,
DVM, DABVP
(Canine and Feline)**IMAGING PERFORMED BY**

Tom McNeill

HOSPITAL NAME

SVS Imaging CT

REFERRING VETMadison Veterinary
Specialists Dr. Alucard**INVOICE**

12313ag

DATE

11/29/2022

PRESENTING CLINICAL SIGNS

Acute onset of vomiting for the past 3 days. The owner described that Remy would be dry heaving and then would throw up the undigested food. About 24-36 hours ago, Remy's mom tried to offer less food at a time to see if that would help, but then she stopped eating all together. Around this same time she began regurgitating water with some yellow/foam in it. Her attitude has also been decreased and she is laying in unusual places like the closet and under the bed. Lastly Remy has had decreased urine production as well, which the owner thinks is because he is unable to drink anything.

ULTRASONOGRAPHIC EXAMINATION OF THE ABDOMEN**Urinary System**

The urinary bladder, trigone, cystourethral junction, and visible pelvic urethra to a depth of 2 cm exhibited normal thickness and tone. Anechoic urine was present in the lumen with no uroliths or sediment. The ureteral papillae were normal. The ureters were not visible which is normal. No evidence of inflammatory or neoplastic changes were noted.

Normal size and margination were present in the kidneys. A normal 1:3 cortex / medulla ratio and normal corticomedullary definition were maintained. The echogenicity of the cortex was similar to or slightly less than normal liver parenchyma while the medulla echogenicity was hypoechoic to the cortex with no evidence of pelvic dilation. The left kidney measured 3.8 cm in length. The right kidney measured 4.3 cm in length.

The area of the aortic trifurcation was free of pathology.

Adrenal Glands

The left adrenal gland was uniform in size and contour with a uniformly hypoechoic parenchyma. The left adrenal gland measured 0.38 cm width. The right adrenal gland was uniform in size and contour with a uniformly hypoechoic parenchyma. The right adrenal gland measured 0.34 cm width.

Spleen

The spleen exhibited a finely textured and homogenous parenchyma which was hyperechoic to the liver and renal cortical parenchyma. The capsule was smooth and regular without apparent expansion. The splenic vasculature at the hilus was normal in volume with no evidence of congestion or thrombosis. Acute to chronic inflammatory, neoplastic, or benign parenchyma changes were not noted.

Liver

The liver was subjectively normal in size, structure, and contour. Subjective mild decreased hepatic parenchyma echogenicity with a mild coarse echotexture was present. The hepatic and portal vasculature were normal in appearance without signs of congestion. The gallbladder was non-distended in size with thin walls and primarily anechoic luminal content. The cystic and common bile ducts were normal to the level of the distal common bile duct adjacent to the duodenal papilla.

Gastrointestinal

The stomach presented intact wall layering with a normal wall layer ratio. The lumen of the stomach was empty with no signs of ileus, obstruction or foreign material. The gastric body wall measured 0.26 cm in width.

The small intestine presented intact wall layering with 1:3 muscularis/mucosa ratio. Segmental intact mildly prominent jejunoileal wall layering was present. No evidence of significant mural hypertrophy or loss of wall layering was present. No intestinal masses. The lumen of the small intestine was empty with

IMAGING PERFORMED BY

SVS Mobile Imaging CT 262-366-5970
fredgromalak@gmail.com



Clinical Sonography & Telectology

EDUCATIONAL TELECONSULTATION SERVICES™

1-800-838-4268 info@sonopath.com SonoPath.com

PATIENT

Remy Waddell 54959A

no signs of ileus, obstruction or foreign material. The duodenum wall measured 0.24 cm width. The jejunum wall measured 0.29 cm width. The ileum wall measured 0.37 cm width.

Normal visible colon wall layers were present with apparent formed feces in lumen.

SPECIES***Pancreas***

Feline

The pancreas presented hypoechoic to heterogeneous echogenicity compared to adjacent omental fat. Mild asymmetrical capsule margination was present with mild variable parenchymal swelling and peripancreatic to regional cranial abdominal hyperechoic to reactive mesentery. A suspect pancreatic cyst present in the proximal right limb at the level of the duodenal papilla.

BREED

DSH

Free Abdomen**SEX**

No peritoneal effusion was present.

MN

Several to multiple focally enlarged pancreaticoduodenal and jejunoileal lymph nodes were present. These lymph nodes were homogenous, mildly hypoechoic and smoothly margined. A normal width:length ratio was maintained (<0.5). Evidence of perilymphatic inflammation was evident. An example of lymph node size was 1.7 cm x 0.65 cm.

AGE

2yr

ULTRASONOGRAPHIC FINDINGS

- Pancreatitis pattern with peripancreatic to cranial abdominal hyperechoic reactive mesentery
- Suspect right pancreatic cyst at the level of the duodenal papilla, potential for regionally non-obstructive distal CBD dilatation/cholangitis
- Mild hypoechoic liver, sonographically unremarkable non-dilated gallbladder
- Intact segmentally prominent jejunoileal walls-possible segmental inflammatory enteropathy
- Associated suspected pancreaticoduodenal and jejunoileal lymphadenitis

WEIGHT

5kg

INTERPRETATION OF THE FINDINGS & FURTHER RECOMMENDATIONS**INTERPRETED BY**

R. McKenzie Daniel,
DVM, DABVP
(Canine and Feline)

A full CBC/Chem panel, spec fPL +/- GI panel to include PLI/TLI/Cobalamin/Folate is recommended for assessment of the pancreas and to assess for occult intestinal disease. Potential for mild to acute emerging hepatopathy is possible although not definitive. Empirical therapy for pancreatitis with as needed GI support based on this study and pending additional diagnostics would be reasonable. No overt evidence of post hepatic obstructive criteria however, sonographic monitoring of the suspected pancreatic cyst with potential for mild non-obstructive CBD dilation/cholangitis is suggested.

IMAGING PERFORMED BY

Tom McNeill

HOSPITAL NAME

SVS Imaging CT

REFERRING VET

Madison Veterinary
Specialists Dr. Alucard

INVOICE

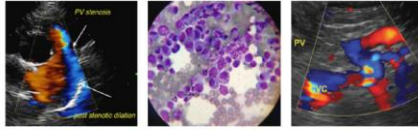
12313ag

DATE

11/29/2022

IMAGING PERFORMED BY

SVS Mobile Imaging CT 262-366-5970
fredgromalak@gmail.com



Clinical Sonography & Telecytology

EDUCATIONAL TELECONSULTATION SERVICES™

1-800-838-4268 info@sonopath.com SonoPath.com

PATIENT

Remy Waddell 54959A

SPECIES

Feline

BREED

DSH

SEX

MN

AGE

2yr

WEIGHT

5kg

INTERPRETED BY

R. McKenzie Daniel,
DVM, DABVP
(Canine and Feline)

IMAGING PERFORMED BY

Tom McNeill

HOSPITAL NAME

SVS Imaging CT

REFERRING VET

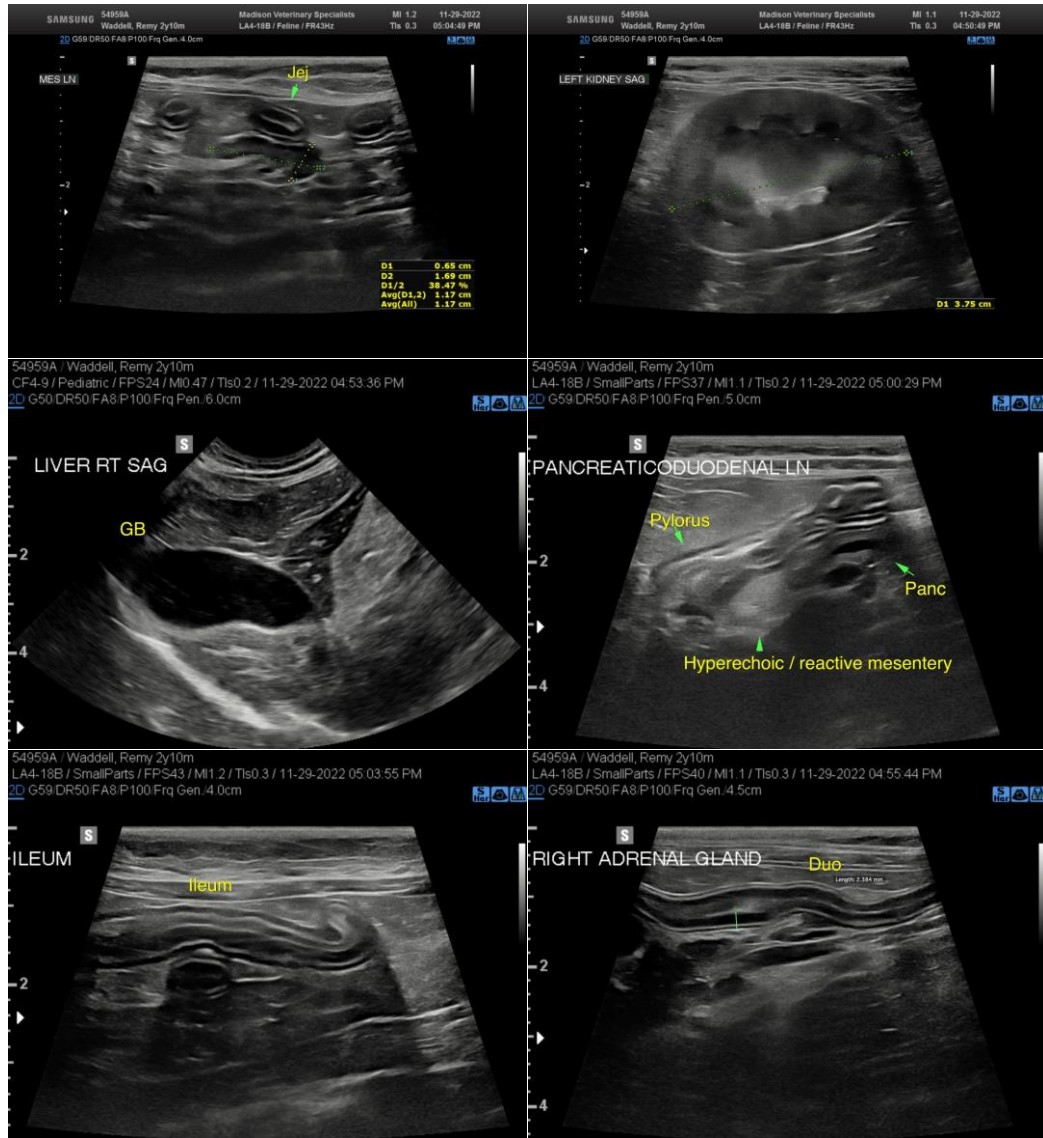
Madison Veterinary
Specialists Dr. Alucard

INVOICE

12313ag

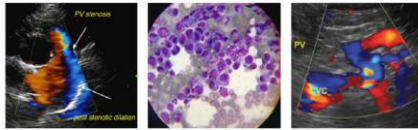
DATE

11/29/2022



IMAGING PERFORMED BY

SVS Mobile Imaging CT 262-366-5970
fredgromalak@gmail.com



EDUCATIONAL TELECONSULTATION SERVICES™
1-800-838-4268 info@sonopath.com SonoPath.com

PATIENT

Remy Waddell 54959A

SPECIES

Feline

BREED

DSH

SEX

MN

AGE

2yr

WEIGHT

5kg

INTERPRETED BY

R. McKenzie Daniel,
DVM, DABVP
(Canine and Feline)

IMAGING PERFORMED BY

Tom McNeill

HOSPITAL NAME

SVS Imaging CT

REFERRING VET

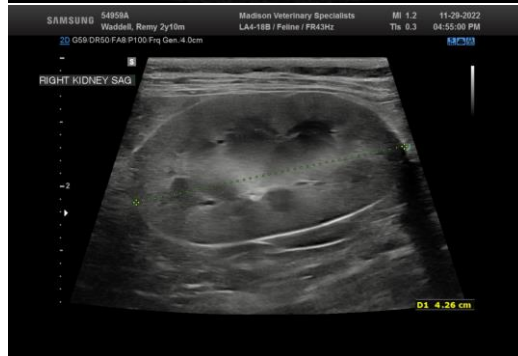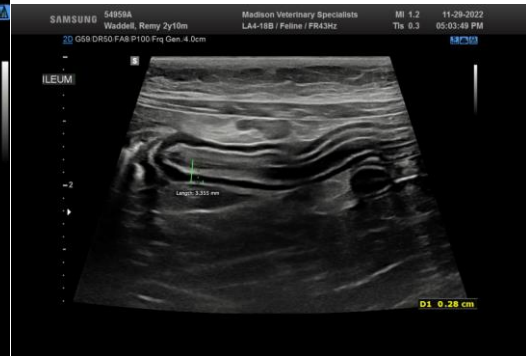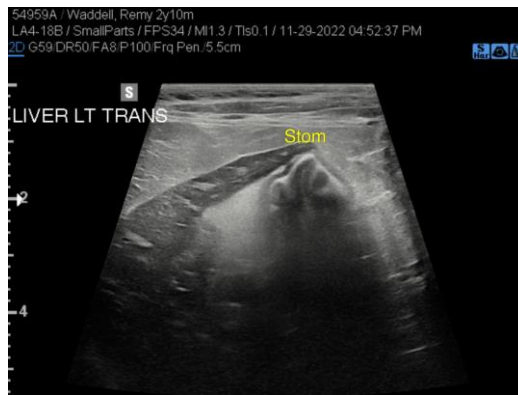Madison Veterinary
Specialists Dr. Alucard

INVOICE

12313ag

DATE

11/29/2022



The information and recommendations provided are based on the images presented by the referring veterinarian/sonographer. No evaluation can be communicated regarding pathology that was not visible in the image/video clips provided.

Thank you for this referral. If the clinical or image interpretation does not parallel your findings or if I can be of any further assistance please contact me.

R. McKenzie Daniel, DVM, DABVP (Canine / Feline Practice)

info@SonoPath.com