


PATIENT PRESENTING CLINICAL SIGNS

Cutty Soreng ecg-axis deviation, tall p wave cbc wnl chem-elevated liver values t4-wnl ua-wnl

SPECIES Abnormal PE/Chem/CBC/UA Results: Heart Rate and Respiratory Rates none Blood Pressure Measurements none Current Medications none

Canine

ULTRASONOGRAPHIC EXAMINATION OF THE ABDOMEN AND HEART

BREED	CANINE CARDIAC PARAMETERS	MR VMAX (m/s)	TR VMAX (m/s)	LA/AO (Boon method)	LA/AO (Heart Base; Swe)	FS (%)	EF (%)	EPSS (cm)
Dachshund								
SEX								
FS	NORMAL PARAMETER	4.5-5.5	<2.7	1.3	<1.3	28-40	40-100	<0.6
AGE								
12yr	CANINE CARDIAC PARAMETERS	HR (BPM)	AV VMAX (m/s)	PV MAX (m/s)	BODY WEIGHT (kg)	LA 2D short axis Base view (cm)	LVIDd Avg; 2D and m-mode short axis (cm)	LVIDs Avg; 2D and m-mode short axis (cm)
WEIGHT								
4.27kg	NORMAL PARAMETER	50-100	0.7-1.7	0.7-1.6				
INTERPRETED BY	PATIENT	NM	1.5	0.71		2.3	2.3	

 R. McKenzie Daniel,
 DVM, DABVP
 (Canine and Feline)

Cardiac Presentation

The echocardiogram in this patient demonstrated normal left atrial size based on 3 different LA measurement methods. Chamber volumes and echogenicity were normal. The cranial and caudal mitral valve leaflets presented minor thickening consistent with endocardiosis more prominent in the septal leaflet. Doppler indicated mild eccentric insufficiency. The left ventricle presented thicknesses with linear contour and was not dilated nor restricted. The myocardium presented normal echogenicity without subjective evidence of significant fibrotic or ischemic disease. Contractility of the ventricular walls was adequate and in normal range for this patient evidenced by the fractional shortening measurement and subjective evaluation of the different regions of the myocardium. The left ventricular outflow tract demonstrated normal laminar flow and subjective structural integrity. The right atrium and auricle revealed normal size, structure and content. No evidence of masses was noted or chamber overload. Tricuspid valvular assessment demonstrated adequate linear morphology. No evidence of significant TR on Doppler. The right ventricle was of normal size (1/3 diameter of LV), chordae structure, myocardial echogenicity and thickness. Pulmonic tract assessment revealed normal valve structure, laminar flow, and diameter (approx.1:1 pa/ao ratio). No visible pericardial or free pleura fluid was noted. No echographically detectable evidence of infiltrative disease was visible. The cranial mediastinum and pericardial regions were free of masses in the visible window.

Urinary System

The urinary bladder, trigone, cystourethral junction, and visible pelvic urethra to a depth of 2 cm exhibited normal thickness and tone. Anechoic urine was present in the lumen with no uroliths or

IMAGING PERFORMED BY

Sara Hansen

HOSPITAL NAME

Edgewood AC

REFERRING VET

Dr. Callahan

INVOICE

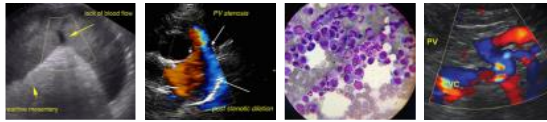
12315ag

DATE

11/29/2022



PATIENT	sediment. The ureteral papillae were normal. The ureters were not visible which is normal. No evidence of inflammatory or neoplastic changes were noted.
Cutty Soreng	
SPECIES	Normal size and margination were present in the kidneys. A normal 1:3 cortex / medulla ratio was maintained. The medulla and cortices were uniform in texture with some increased echogenicity and moderate loss of corticomedullary symmetry and definition expected for the age of the patient. No evidence of pelvic dilation was present. Bilateral pinpoint medullary mineral was present. The left kidney measured 4.7 cm in length. The right kidney measured 4.5 cm in length.
Canine	
BREED	The area of the aortic trifurcation was free of pathology.
Dachshund	
	Adrenal Glands
SEX	The left adrenal gland was uniform in size and contour with a uniformly hypoechoic parenchyma. The left adrenal gland measured 0.51 cm width at the caudal pole and 0.65 cm width at the cranial pole. The right adrenal gland was uniform in size and contour with a uniformly hypoechoic parenchyma. The right adrenal gland measured 0.47 cm width at the caudal pole.
FS	
AGE	Spleen
12yr	The spleen exhibited primarily finely textured and homogenous parenchyma which was hyperechoic to the liver and renal cortical parenchyma. A solitary well-defined, symmetrical, hyperechoic nodule was present in the medial parenchyma. The capsule was smooth and regular without apparent expansion. The splenic vasculature at the hilus was normal in volume with no evidence of congestion or thrombosis. Acute to chronic inflammatory or neoplastic changes were not noted. The echogenic nodules tend to trend benign and are most consistent with benign hyperplasia or myelolipomas.
WEIGHT	
4.27kg	
INTERPRETED BY	Liver
R. McKenzie Daniel, DVM, DABVP (Canine and Feline)	The liver presented moderately enlarged in size. The parenchyma of the liver was subjectively normal in echogenicity compared to the spleen and renal cortices. The liver parenchyma was uniform with a mildly coarse echotexture. A solitary expansive mild asymmetrical hypoechoic to non-homogeneous mass was present in the lid to right liver resulting in displacement of the gallbladder caudally. The capsule of the liver was symmetrically rounded to mildly swollen in margination. The hepatic and portal vasculature were normal in appearance without signs of congestion.
IMAGING PERFORMED BY	
Sara Hansen	
HOSPITAL NAME	The gallbladder was non-distended in size with primarily anechoic luminal content and mild non-organized echogenic luminal debris. The cystic and common bile ducts were normal.
Edgewood AC	
REFERRING VET	Gastrointestinal
Dr. Callahan	The stomach presented intact wall layering with a normal wall layer ratio. The lumen of the stomach was empty with no signs of ileus, obstruction or foreign material.
INVOICE	The small intestine presented intact wall layering with 1:3 muscularis/mucosa ratio. The lumen of the small intestine was empty with no signs of ileus, obstruction or foreign material.
12315ag	
DATE	The colon walls presented intact yet prominent wall layering with mild thickened to echogenic submucosa. The colon was primarily empty with lumen dilation
11/29/2022	Pancreas



PATIENT The pancreas was normal in size and contour with isoechoic to heterogeneous parenchyma compared to adjacent omentum, likely consistent with age related changes and considered incidental. No signs of active inflammation or neoplasia.
Cutty Soreng

SPECIES *Free Abdomen*

Canine No omental masses or peritoneal effusion was present.

BREED Discrete hepatic lymphadenopathy adjacent to the portal vein was present, exhibiting normal width to length ration.
Dachshund

ULTRASONOGRAPHIC FINDINGS

- SEX**
- Compensated mild chronic mitral valve disease (ACVIM B1)
 - Hepatomegaly exhibiting large hypoechoic intraparenchymal mass
- FS
- Displaced gallbladder with mild non-dependent luminal debris (non-mucocele)
 - Bilateral chronic renal changes
- AGE**
- Benign splenic nodule-consistent with benign myelolipoma

12yr INTERPRETATION OF THE FINDINGS & FURTHER RECOMMENDATIONS

WEIGHT No indication for cardiac medications. The mild mitral valve insufficiency is not suspected to be audible. Conservative monitoring of the heart at this stage would be appropriate. A recheck echocardiogram recommended in 6-12 months, sooner if clinical signs arise.
4.27kg

INTERPRETED BY Assuming normal clotting status and using a 25g needle, a hepatic parenchyma and hepatic mass FNA for screening cytology is warranted for further assessment. Subjectively the mass does not appear to be amendable to complete surgical resection as it likely involves more than one liver lobe. Hepatosupportive medications such as Denamarin or Vitamin E as well as Ursodiol may prove beneficial.
R. McKenzie Daniel,
DVM, DABVP
(Canine and Feline)

An abdominal CT could be considered for further assessment of the hepatic mass and abdominal cavity. Three view chest radiographs are recommended if not done to assess for occult thoracic pathology.

IMAGING PERFORMED BY

Sara Hansen

HOSPITAL NAME

Edgewood AC

REFERRING VET

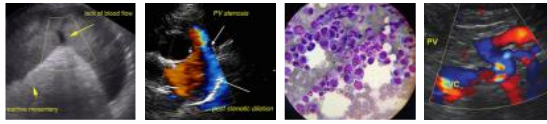
Dr. Callahan

INVOICE

12315ag

DATE

11/29/2022



PATIENT

Cutty Soreng

SPECIES

Canine

BREED

Dachshund

SEX

FS

AGE

12yr

WEIGHT

4.27kg

INTERPRETED BY

R. McKenzie Daniel,
DVM, DABVP
(Canine and Feline)

IMAGING PERFORMED BY

Sara Hansen

HOSPITAL NAME

Edgewood AC

REFERRING VET

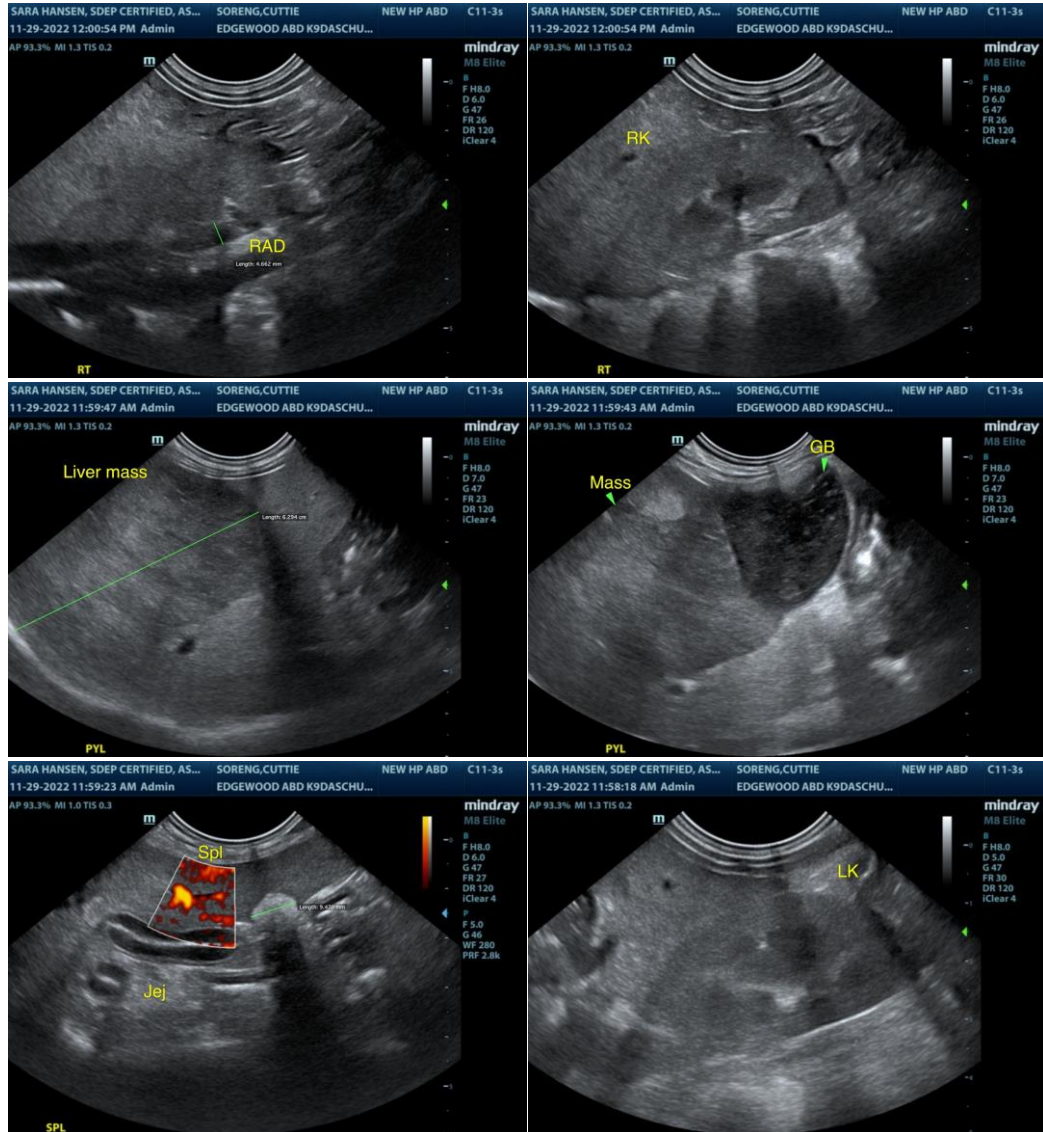
Dr. Callahan

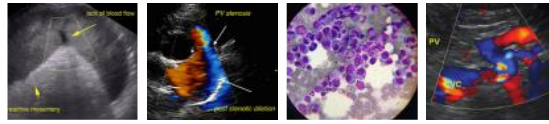
INVOICE

12315ag

DATE

11/29/2022





PATIENT
Cutty Soreng

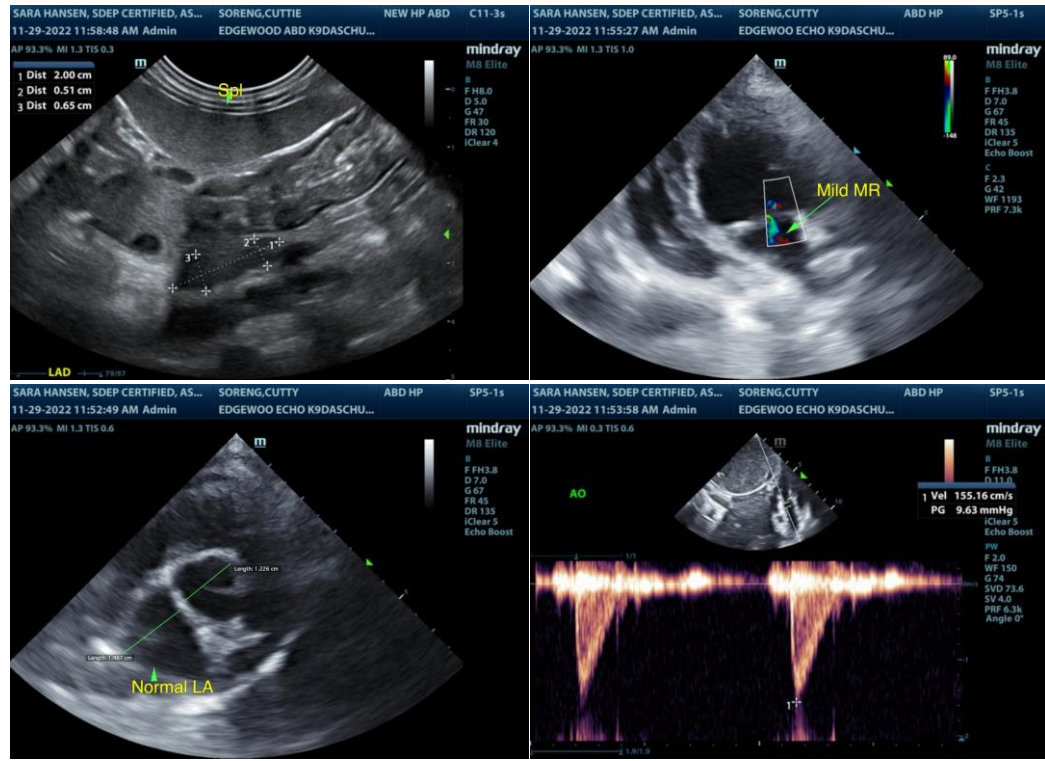
SPECIES
Canine

BREED
Dachshund

SEX
FS

AGE
12yr

WEIGHT
4.27kg



INTERPRETED BY

R. McKenzie Daniel,
DVM, DABVP
(Canine and Feline)

The information and recommendations provided are based on the images presented by the referring veterinarian/sonographer. No evaluation can be communicated regarding pathology that was not visible in the image/video clips provided.

IMAGING PERFORMED BY

Sara Hansen

Thank you for this referral. If the clinical or image interpretation does not parallel your findings or if I can be of any further assistance please contact me.

R. McKenzie Daniel, DVM, DABVP (Canine / Feline Practice)
info@SonoPath.com

HOSPITAL NAME

Edgewood AC

REFERRING VET

Dr. Callahan

INVOICE

12315ag

DATE

11/29/2022