



PATIENT

Daisy Hein

PRESENTING CLINICAL SIGNS

P presented ADR 11/26-abn. findings dental dz. OH hips. muscle wasting-worsened over weekend.
Current meds Gabapentin 300: 1 PO 9/12

SPECIES

Canine

Abnormal PE/Chem/CBC/UA Results: 11/26: AST 78, ALT 148, ALP 141, WBC 16.5, RBC 4.1, Hgb 9.4, HCT 27, PLT 119

BREED

Lab Mix

ULTRASONOGRAPHIC EXAMINATION OF THE ABDOMEN

Urinary System

The urinary bladder, trigone, cystourethral junction, and visible pelvic urethra to a depth of 3 cm exhibited normal thickness and tone. Anechoic urine was present in the lumen with no uroliths or sediment. The ureteral papillae were normal. The ureters were not visible which is normal. No evidence of inflammatory or neoplastic changes were noted.

SEX

FS

Normal size and margination were present in the kidneys. A normal 1:3 cortex / medulla ratio was maintained. The medulla and cortices were uniform in texture with some increased echogenicity and mild loss of corticomedullary symmetry and definition expected for the age of the patient. No evidence of pelvic dilation was present. The left kidney measured 6.9 cm in length. The right kidney measured 7.0 cm in length

AGE

12yr

WEIGHT

60lb

The area of the aortic trifurcation was free of pathology.

Adrenal Glands

The left adrenal gland was normal in size. An irregular non-homogeneous hyperechoic nodule was present in the cranial pole with mild associated capsule distortion without evidence of parenchymal escape or vascular invasion measuring 1.6 cm x 1.1 cm. Mild parenchyma heterogeneity and mild capsule asymmetry was present without suspicion for overt neoplasia. The left adrenal gland measured 3.7 cm length and 0.58 cm width in the caudal pole.

INTERPRETED BY

R. McKenzie Daniel,
DVM, DABVP
(Canine and Feline)

The cranial pole of the right adrenal gland was indistinctly visualized owing to patient size and conformation. Mild parenchyma heterogeneity and mild capsule asymmetry was present without suspicion for overt neoplasia. The right adrenal gland measured ~3.0 cm length and 0.44 cm width in the caudal pole.

IMAGING PERFORMED BY

Jessica Miller

Spleen

A solitary to potential coalescing mass/masses involving the spleen with secondary asymmetrical capsule expansion and disruption was present and measured ~9 cm x 8 cm. The parenchyma of the mass was heterogeneous to mixed echogenic with areas of cavitation. The non-affected spleen exhibited primarily finely textured and homogenous parenchyma which was hyperechoic to the liver and renal cortical parenchyma. The splenic vasculature at the hilus was normal in volume with no evidence of congestion or thrombosis. Regional omental inflammation was present around the mass. Scant perisplenic free fluid was present consistent with mild perisplenic hemoabdomen. Possible omental adhesions were present.

HOSPITAL NAME

Andover AH

REFERRING VET

Dr. Bihlear

INVOICE

12283ag

Liver

The liver presented enlarged in size. The parenchyma of the liver was subjectively normal in echogenicity compared to the spleen and renal cortices. The liver parenchyma was uniform with a mildly coarse echotexture. The capsule of the liver was symmetrically rounded to mildly swollen in

DATE

11/28/2022



PATIENT

Daisy Hein

margination. The hepatic and portal vasculature were normal in appearance without signs of congestion.

SPECIES

Canine

The gallbladder was non-distended in size with primarily anechoic luminal content and mild non-dependent echogenic debris. No evidence of gallbladder or peripheral gallbladder inflammation was present. The cystic and common bile ducts were normal.

Gastrointestinal

BREED

Lab Mix

The stomach presented intact wall layering with a normal wall layer ratio. The lumen of the stomach was empty with no signs of ileus, obstruction or foreign material.

The small intestine presented intact wall layering with 1:3 muscularis/mucosa ratio. The lumen of the small intestine was empty with no signs of ileus, obstruction or foreign material.

SEX

FS

Normal visible colon wall layers were present with apparent formed feces in lumen.

Pancreas

AGE

12yr

The parenchyma of the left limb, body and right limb of the pancreas presented isoechoic to the adjacent omental fat. A normal curvilinear capsule contour of the pancreas was present. The visible pancreatic duct was normal. No signs of active inflammation or neoplastic disease was evident.

Free Abdomen

WEIGHT

60lb

No overt lymphadenopathy was present. Regional omental inflammation was present around the splenic mass. Scant perisplenic free fluid was present consistent with mild perisplenic hemoabdomen.

Rapid view of the heart revealed no evidence of pericardial masses or effusion in the visible window.

INTERPRETED BY

R. McKenzie Daniel,
DVM, DABVP
(Canine and Feline)

ULTRASONOGRAPHIC FINDINGS

- Solitary to potential coalescing splenic mass/masses with regional hyperechoic mesentery and scant free fluid-potential for omental adhesions
- Hepatic parenchyma remodeling
- Mild gallbladder debris (non-mucocele)
- Bilateral chronic renal changes
- Mild irregular to non-homogeneous adrenal glands, non-specific left adrenal nodule-age related changes, adenomatous change, hyperplasia, potential for emerging neoplasia cannot be definitively excluded

IMAGING PERFORMED BY

Jessica Miller

HOSPITAL NAME

Andover AH

INTERPRETATION OF THE FINDINGS & FURTHER RECOMMENDATIONS

Although histopathology is required for definitive diagnosis, the splenic mass is most suggestive of neoplasia such as sarcoma or other. Benign pathologies are possible yet considered less likely. No overt evidence of hepatic or renal metastasis although potential for early regional perisplenic omental seeding cannot be definitively excluded.

REFERRING VET

Dr. Bihlear

A screening BP is advised to assess for evidence of hypertension which may allude to emerging adrenal neoplastic criteria i.e. pheochromocytoma. Assuming no evidence of pathology in three view chest radiographs, splenectomy with gross inspection of the perisplenic omentum, liver and bilateral adrenal glands could be considered. Sonographic monitoring of the bilateral adrenal glands pending gross inspection or if splenectomy is performed is likely ideal.

INVOICE

12283ag

DATE

11/28/2022



PATIENT

Daisy Hein

SPECIES

Canine

BREED

Lab Mix

SEX

FS

AGE

12yr

WEIGHT

60lb

INTERPRETED BY

R. McKenzie Daniel,
DVM, DABVP
(Canine and Feline)

IMAGING PERFORMED BY

Jessica Miller

HOSPITAL NAME

Andover AH

REFERRING VET

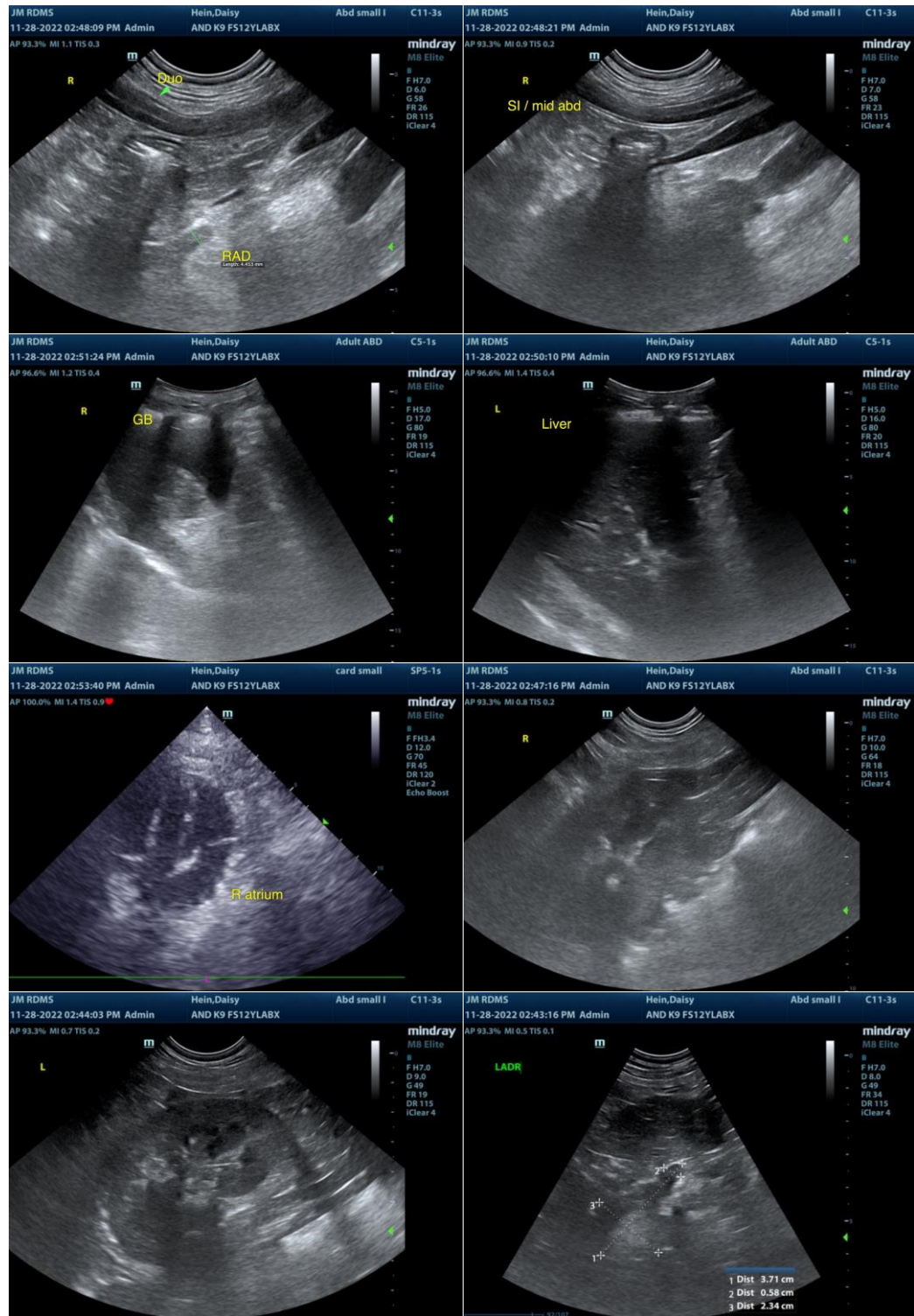
Dr. Bihlear

INVOICE

12283ag

DATE

11/28/2022



The information and recommendations provided are based on the images presented by the referring



PATIENT

Daisy Hein

veterinarian/sonographer. No evaluation can be communicated regarding pathology that was not visible in the image/video clips provided.

Thank you for this referral. If the clinical or image interpretation does not parallel your findings or if I can be of any further assistance, please contact me.

SPECIES

Canine

R. McKenzie Daniel, DVM, DABVP (Canine/Feline Practice)
mac.daniel@sonopath.com

BREED

Lab Mix

SEX

FS

AGE

12yr

WEIGHT

60lb

INTERPRETED BY

R. McKenzie Daniel,
DVM, DABVP
(Canine and Feline)

**IMAGING
PERFORMED BY**

Jessica Miller

HOSPITAL NAME

Andover AH

REFERRING VET

Dr. Bihlear

INVOICE

12283ag

DATE

11/28/2022